

REVIEW ARTICLE

MEDICAL PROGRESS

Necrotizing Enterocolitis

Josef Neu, M.D., and W. Allan Walker, M.D.

NECROTIZING ENTEROCOLITIS IS AMONG THE MOST COMMON AND DEVASTATING diseases in neonates. It has also been one of the most difficult to eradicate¹ and thus has become a priority for research.² Conditions closely resembling necrotizing enterocolitis were described before the 1960s, but the entity was not widely recognized until after the advent of modern neonatal intensive care.¹ Since that time, the incidence of necrotizing enterocolitis and the associated morbidity and mortality have remained unchanged because of ever-improving survival of the smallest infants; in some instances, these rates have actually increased. On the basis of large, multicenter, neonatal network databases from the United States and Canada, the mean prevalence of the disorder is about 7% among infants with a birth weight between 500 and 1500 g.³⁻⁶ The estimated rate of death associated with necrotizing enterocolitis ranges between 20 and 30%, with the highest rate among infants requiring surgery.⁷

The excessive inflammatory process initiated in the highly immunoreactive intestine in necrotizing enterocolitis extends the effects of the disease systemically, affecting distant organs such as the brain and placing affected infants at substantially increased risk for neurodevelopmental delays.^{8,9} Indeed, an infant recovering from necrotizing enterocolitis may have nearly a 25% chance of microcephaly and serious neurodevelopmental delays that will transcend concerns that pertain to the gastrointestinal tract.¹⁰ In many centers, concern that enteral feeding is associated with the development of necrotizing enterocolitis has resulted in an increased duration of intravenous nutrition in infants, potentially increasing the risk of infectious complications and the length of hospitalization.¹¹

The financial cost of necrotizing enterocolitis is substantial; the total annual estimated cost of caring for affected infants in the United States is between \$500 million and \$1 billion. In one study,¹² infants with necrotizing enterocolitis were hospitalized 60 days longer than unaffected preterm infants if surgery was required and more than 20 days longer if surgery was not necessary. The need for bowel resection is one of the most common severe complications of necrotizing enterocolitis and is the major cause of the short-bowel syndrome in pediatric patients. The total mean cost of care over a 5-year period for a child with the short-bowel syndrome has been estimated to be nearly \$1.5 million.¹³

DIFFERENTIAL DIAGNOSIS

There are multiple necrotizing enterocolitis–like conditions with various presentations. However, the most typical initial signs and symptoms of “classic” necrotizing enterocolitis in a preterm infant include feeding intolerance, abdominal distention (Fig. 1A), and bloody stools after 8 to 10 days of age. The pathognomonic findings on abdominal radiography are pneumatosis intestinalis, portal venous gas, or both (Fig. 1B). Early imaging signs that should raise the suspicion of necrotizing enterocolitis include dilated loops of bowel, a paucity of gas, and gas-filled loops of bowel

From the Department of Pediatrics, University of Florida, Gainesville (J.N.); Harvard Medical School, Boston (W.A.W.); and the Department of Pediatrics, Massachusetts General Hospital for Children, Charlestown (W.A.W.). Address reprint requests to Dr. Walker at the Mucosal Immunology Laboratory, Department of Pediatrics, Massachusetts General Hospital for Children, 114 16th St., Boston, MA 02129-4404, or at wwalker@partners.org.

N Engl J Med 2011;364:255-64.

Copyright © 2011 Massachusetts Medical Society.

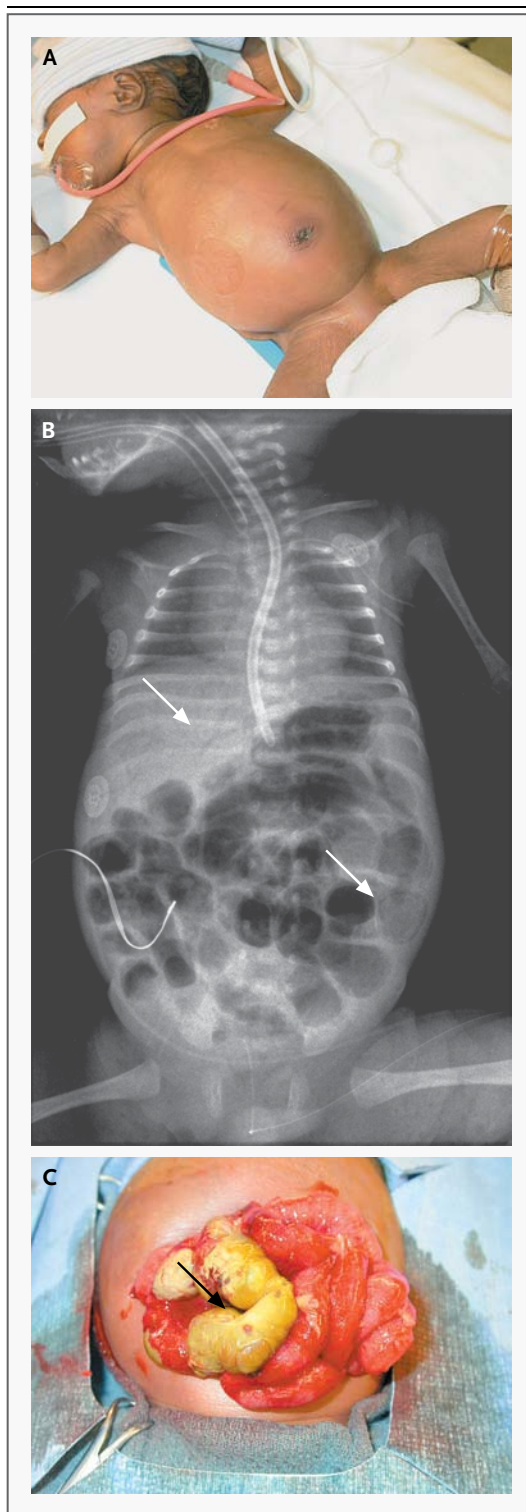


Figure 1. Clinical and Radiographic Features of Necrotizing Enterocolitis.

Panel A shows an infant with a shiny, distended abdomen with periumbilical erythema. (Photograph courtesy of Dr. David Kays, Department of Pediatric Surgery, University of Florida.) In the radiograph shown in Panel B, the upper arrow points to portal air, and the lower arrow points to a ring of intramural gas, which is indicative of pneumatosis intestinalis. (Radiograph courtesy of Dr. Jonathan Williams, Department of Pediatric Pathology, University of Florida.) In Panel C, the arrow points to an area of necrotic bowel in a patient with necrotizing enterocolitis. (Photograph courtesy of Dr. David Kays, Department of Pediatric Surgery, University of Florida.)

from subtle signs to abdominal discoloration, intestinal perforation, and peritonitis, leading to systemic hypotension that requires intensive medical support, surgical support, or both (Fig. 1C).

Despite considerable research, preventive strategies have remained elusive for several decades, reflecting the lack of a clear delineation of what constitutes the diagnosis of classic necrotizing enterocolitis. Thus, the term “necrotizing enterocolitis” often reflects a spectrum of intestinal conditions that differ with respect to pathogenesis and the strategies required for prevention and treatment. Three forms of neonatal intestinal injury occur most often: conditions primarily seen in term infants, spontaneous intestinal perforations, and classic necrotizing enterocolitis. Although necrotizing enterocolitis is considered to be a disease that primarily affects preterm infants, necrotizing enterocolitis–like symptoms also occur in term and late preterm infants. In these more mature neonates, the disease usually occurs in the first week after birth, but it differs from that seen in preterm infants in that it is more often associated with other problems, such as maternal illicit drug use, intestinal anomalies (e.g., aganglionosis or atresias), congenital heart disease, and perinatal stress that may affect mesenteric blood flow.^{14,15} Among preterm infants, spontaneous intestinal perforations have at times been categorized as necrotizing enterocolitis but probably represent a different disease entity with a different pathogenesis.^{16,17} Spontaneous intestinal perforation usually occurs in the first several days after birth and is not associated with enteral feeding. This disorder is characterized by only minimal intestinal inflammation and necrosis, as evidenced by low levels of serum inflammatory cytokines. It has been associated with

that are unaltered on repeated examinations. Extraluminal air (“free air”) outside the bowel is a sign of advanced necrotizing enterocolitis. Symptoms may progress rapidly, often within hours,

the administration of indomethacin and with glucocorticoids such as dexamethasone or hydrocortisone.^{18,19}

The remainder of this review focuses on the most common form of the disease, classic necrotizing enterocolitis, which involves an inflammatory intestinal condition in prematurely born infants. The more premature the infant, the later this condition occurs after birth.²⁰ The lack of universally reliable diagnostic criteria makes it difficult to establish the diagnosis. A systematic description of necrotizing enterocolitis, the staging system described by Bell et al., was first published in 1978 and subsequently refined.^{21,22} This system includes three stages. Stage 1 criteria are highly nonspecific findings and may include feeding intolerance, mild abdominal distention, or both. Stage 2 criteria are radiographic findings such as pneumatosis intestinalis, which may be hard to detect on radiographs. One of the most important criteria for stage 3 is a perforated viscus, which may or may not be associated with intestinal necrosis and which could, in fact, be a spontaneous intestinal perforation or dissected air from the pleural cavity. Furthermore, whether necrosis is actually present may not be clear in individual patients, since peritoneal drains may be placed without direct visualization and histopathological evaluation.²³

Another classification system used to define necrotizing enterocolitis more specifically is published in the *Vermont Oxford Network Manual of Operations*.²⁴ This manual describes clinical and radiographic findings, with one or more of each type of finding (clinical or radiographic) required to establish a diagnosis of necrotizing enterocolitis. The clinical findings include bilious gastric aspirate or emesis, abdominal distention, and occult gross blood in the stool, with the absence of anal fissures. The imaging findings include pneumatosis intestinalis, hepatobiliary gas, and pneumoperitoneum. However, the Vermont–Oxford diagnostic approach has shortcomings similar to those of the criteria described by Bell et al., since severe necrotizing enterocolitis requiring surgery can develop in patients even though pneumatosis intestinalis or portal gas has not been detected on imaging. These patients may only have abdominal distention, without intraluminal bowel gas, on presentation.²⁵ Thus, the ominous progression of the disease may be missed, with a failure to intervene early enough.

A more reliable staging approach that allows for aggressive preventive measures is needed, but it will probably require the development of biomarkers that accurately predict the full expression of necrotizing enterocolitis.

CURRENT TREATMENT STRATEGIES

Almost all very-low-birth-weight infants have intermittent gastrointestinal symptoms, such as abdominal distention, heme-positive stools, and feeding intolerance, that may cause concern, but most do not have necrotizing enterocolitis. Definitive necrotizing enterocolitis may require medical or surgical management based on the clinical presentation (Table 1). Medical intervention typically includes abdominal decompression, bowel rest, broad-spectrum intravenous antibiotics, and intravenous hyperalimentation. Surgical interventions are generally required in patients with intestinal perforation or deteriorating clinical or biochemical status (e.g., shock or a decreasing platelet count, neutrophil count, or both). Surgical procedures may involve drain placement, exploratory laparotomy with resection of diseased bowel, and enterostomy with creation of a stoma.

Two commonly used methods for treating advanced necrotizing enterocolitis with intestinal perforation are laparotomy and primary peritoneal drainage without laparotomy. The relative benefits of these methods have been controversial. Two large multicenter studies attempted to address this controversy.^{26,27} The first concluded that the type of procedure does not influence survival or other clinically important early outcomes.²⁶ The second study also showed no significant differences in outcomes between the groups, but it showed that infants treated with peritoneal drainage very often required a subsequent laparotomy.²⁷ Further analysis of data from the latter study examined whether peritoneal drainage improved the patient's immediate clinical status, and it showed no improvement when peritoneal drainage was used for this purpose.²⁴ In addition, a systematic review of several studies suggested mortality was increased by more than 50% with peritoneal drainage as compared with laparotomy.²⁸ Follow-up examinations at 18 to 22 months in infants who had undergone surgery for necrotizing enterocolitis in the neonatal period showed a significantly reduced risk of death or neurodevelopmental impairment among those

Table 1. Diagnostic Criteria for and Treatment of Necrotizing Enterocolitis.*

| Diagnosis and Signs and Symptoms | Treatment Strategy |
|--|--|
| Suspected necrotizing enterocolitis | |
| Abdominal distention without radiographic evidence of pneumatosis intestinalis, portal venous gas, or free intraperitoneal air | Close clinical observation for increased abdominal distention and feeding intolerance |
| Unexpected onset of feeding intolerance | Consideration of bowel decompression and brief discontinuation of feeding (e.g., 24 hr); abdominal radiograph (anteroposterior and left lateral decubitus); monitoring of white-cell, differential, and platelet counts (sudden decreases suggest progression of disease); consideration of blood cultures and short course of intravenous antibiotics |
| Definitive medical necrotizing enterocolitis | |
| Abdominal distention with pneumatosis intestinalis, portal venous gas, or both | Bowel decompression and discontinuation of enteral feedings for approximately 7–10 days |
| Other radiographic signs such as fixed, dilated loops of intestine and ileus patterns are not pathognomonic but should be treated as such | Close monitoring of white-cell, differential, and platelet counts (sudden decreases suggest progression of disease); blood culture and intravenous antibiotics for 7–10 days; close monitoring of abdominal radiographs (anteroposterior and left lateral decubitus); notification of surgical team |
| Surgical necrotizing enterocolitis | |
| Free intraperitoneal air on abdominal radiograph after initial medical signs and symptoms | Exploratory laparotomy with resection if necessary |
| Persistent ileus pattern, abdominal distention, and radiographs that show an absence of bowel gas, coupled with deteriorating clinical and laboratory values (e.g., decreasing neutrophil and platelet counts) | Placement of drain |

* Adapted from Bell et al.²¹ and Walsh and Kliegman.²²

who had undergone a laparotomy as compared with those who had undergone peritoneal drainage.²⁹ These studies indicate that once surgery is required, the outcome may be poor, a finding that underscores the need for effective prevention.

PATHOGENESIS

The pathophysiology of classic necrotizing enterocolitis is incompletely understood. However, epidemiologic observations strongly suggest a multifactorial cause. The combination of a genetic predisposition, intestinal immaturity, and an imbalance in microvascular tone, accompanied by a strong likelihood of abnormal microbial colonization in the intestine and a highly immunoreactive intestinal mucosa, leads to a confluence of predisposing factors (Fig. 2).

INTESTINAL IMMATURITY

Immature motility, digestion, absorption, immune defenses, barrier function, and circulatory regu-

lation probably predispose the preterm infant to an increased risk of intestinal injury.³⁰ For example, gastric acid secretion is limited in the preterm infant, and this limitation has been linked to an increased risk of necrotizing enterocolitis, particularly among infants with gastric acid secretion that is further limited by the administration of H₂ blockers.⁴

Observations in animal models of necrotizing enterocolitis and in human fetal-cell cultures, intestinal explants, and xenografts have suggested that the fetus and preterm infant have an excessive inflammatory response to luminal microbial stimuli; such responses alter the protective barriers in the intestine. Extensive basic mucosal immunologic studies^{31,32} indicate that after its initial postnatal microbial colonization, the human intestine adapts to the increased microbial stimulation by means of modifications in the epithelial innate immune response. The expression of toll-like receptor 4 (TLR4) appears to be increased in a fetal cell line as compared with an

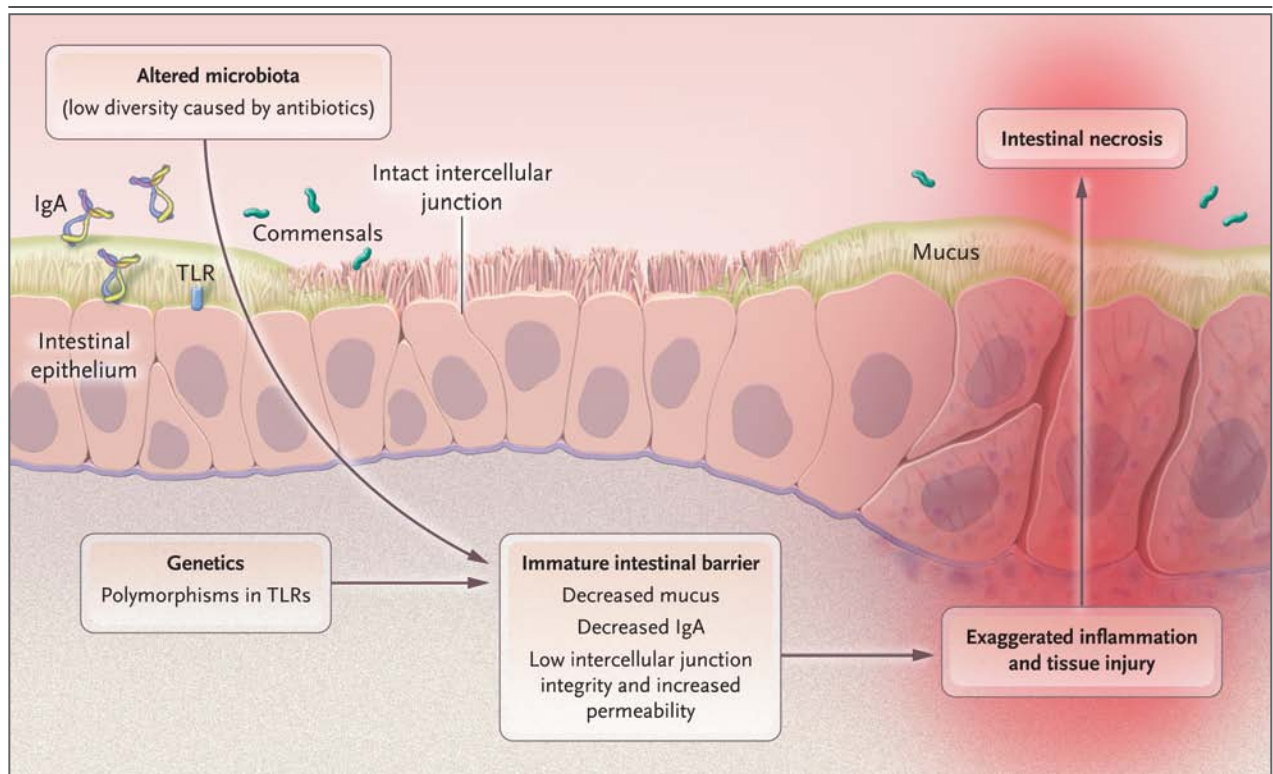


Figure 2. Pathophysiology of Necrotizing Enterocolitis.

Factors conferring a predisposition to necrotizing enterocolitis include genetic factors and several immature characteristics of the fetal intestine, including altered microbiota, inadequate intestinal barrier function, and an excessive inflammatory response. These factors contribute to the severe necrosis of the small intestine that is characteristic of this disease. TLR denotes toll-like receptor.

adult cell line,³³ and an important regulatory factor (I κ B) for the transcription factor nuclear factor κ B (NF- κ B), which affects inflammation, is developmentally underexpressed.³⁴ Such differences between the fetal and the mature intestine may be the basis for the excessive and inappropriate inflammatory response that leads to necrotizing enterocolitis. These observations suggest that enterocytes in the preterm infant, which have resided in a germ-free intrauterine environment, are not prepared for the excessive stimulation of initial postnatal colonization.

Several clinical observations also implicate excessive inflammation in response to intestinal stimuli in the development of this intestinal injury.^{35,36} For example, the serum levels of several cytokines and chemokines that recruit inflammatory cells have been reported to be higher in patients with necrotizing enterocolitis than in unaffected preterm infants. Among these increased cytokines, interleukin-8,³⁶ which is produced by epithelial cells and mediates the migration of

neutrophils to the site of inflammation and their activation, can cause necrosis and increased production of acute-phase proteins in the gut.³⁷ Thus, the increase in interleukin-8 and the excessive inflammatory response produced by fetal enterocytes as compared with mature enterocytes are consistent with the vulnerability of the preterm infant to necrotizing enterocolitis.^{30,38}

MICROBIAL COLONIZATION

Another hypothesis is that inappropriate initial microbial colonization in preterm infants is an important risk factor for necrotizing enterocolitis,³⁹ particularly since necrotizing enterocolitis does not occur until at least 8 to 10 days post partum, at a time when anaerobic bacteria have colonized the gut. Furthermore, experimental necrotizing enterocolitis does not occur in germ-free animals,⁴⁰ and infants with necrotizing enterocolitis frequently have concomitant bacteremia and endotoxemia.⁴¹ Although specific pathogens have been cultured in outbreaks of necrotizing

enterocolitis in single institutions, no organism has consistently been implicated. The Human Microbiome Project was initiated in 2007⁴² in conjunction with technological advances that allow for the molecular identification of a vast array of microbes that are difficult or impossible to culture from the intestine. The findings of this project have strengthened the evidence supporting the colonization hypothesis.⁴³

Preliminary studies using molecular methods to evaluate fecal microbiota from unaffected preterm infants, as well as some infants in whom necrotizing enterocolitis developed and from whom samples were obtained before and during necrotizing enterocolitis,^{44,45} suggest that the disorder is associated with both unusual intestinal microbial species and an overall reduction in the diversity of microbiota, especially when there has been prolonged antibiotic therapy. The decreased microbial diversity and alteration in the microbial species may reduce colonization resistance,⁴⁶ because the usually rich diversity among colonizing intestinal microflora, which protects the host against hospital-acquired pathogens that can cause intestinal inflammation, is lacking. In addition, in a cultured human enterocyte model, commensal bacteria as well as pathogens have been shown to evoke an excessive inflammatory response in fetal human enterocytes as compared with mature enterocytes.³⁴ This difference appears to be mediated by a developmental immaturity in the expression of I κ B (the molecule that inhibits the activation of cytokines by transcription factor NF- κ B), providing further evidence that the premature gut is unprepared to interact with colonizing bacteria in the extrauterine environment.³⁴ The excessive immature inflammatory response associated with abnormal intestinal microbiota is currently considered to be the most likely basis for the pathogenesis of necrotizing enterocolitis.

HYPOXIA–ISCHEMIA

The role of hypoxia–ischemia, previously considered to be the primary contributor to necrotizing enterocolitis,^{47,48} has recently been questioned.⁴⁹ It is now considered to be unlikely that major perinatal hypoxic–ischemic events contribute substantially to the pathogenesis of necrotizing enterocolitis. However, hypoxia and ischemia modulate the balance in microvascular tone related to the relative production of vascular regulators such

as nitric oxide and endothelin, which probably play a downstream role in the pathogenic cascade that leads to necrotizing enterocolitis.⁴⁹

OTHER CONTRIBUTING FACTORS

Although of wide concern in neonatology, the use of umbilical catheters has not been causally associated with the pathogenesis of necrotizing enterocolitis, and parenteral nutrition through an umbilical-artery catheter does not increase the risk of necrotizing enterocolitis.⁵⁰ An association between the elective transfusion of packed red cells and necrotizing enterocolitis has been reported,⁵¹ but the way in which transfusion might be related to alterations in intestinal blood flow or hypoxia–ischemia is unclear.

PREVENTIVE APPROACHES

Numerous approaches have been proposed for the prevention of necrotizing enterocolitis (Table 2). These approaches include withholding enteral feedings; using enteral antibiotics; feeding the infant with the mother's expressed breast milk; administering probiotic agents, prebiotic agents, or both; and administering various growth factors, anticytokine agents, and glucocorticoids. The widespread practice of withholding enteral feedings in infants with necrotizing enterocolitis stems from clinical experience and retrospective reviews suggesting that a rapid increase in feedings increases the likelihood of necrotizing enterocolitis.⁵² More recent data suggest that complete withholding of feedings may be a dangerous practice because it leads to the prolonged use of parenteral nutrition, as well as to intestinal atrophy, increased permeability and inflammation, and late-onset sepsis.⁵³ It is thought that a delay in feeding may actually increase the severity of necrotizing enterocolitis if it occurs.⁵³

A current alternative attempt at the prevention of necrotizing enterocolitis is to provide enteral feedings of small amounts of the mother's expressed breast milk; this approach appears promising.^{54–56} A recent study suggested that the exclusive use of human milk plus a human milk–derived fortifier may result in a lower incidence of necrotizing enterocolitis.⁵⁷

The findings of several small studies suggest that the administration of enteral aminoglycosides might be a promising preventive strategy,^{58,59} but most neonatal intensive care units

Table 2. Measures to Prevent Necrotizing Enterocolitis.*

| Evidence of Efficacy and Safety | Evidence of Efficacy but Questionable Safety | Evidence of Efficacy in Animal Models but Not in Humans | Proposed Efficacy but Lacking Evidence |
|---------------------------------|--|---|--|
| Breast-milk feeding | Enteral aminoglycosides | Anticytokines | Prebiotics (derived from plants and breast milk) |
| Nonaggressive enteral feeding | Probiotics | Growth factors | Microbial components and toll-like-receptor agonists |
| | Glucocorticoids | | Glutamine, n-3 fatty acids |
| | Arginine | | |

* Adapted from Grave et al.² and Neu.²⁰

(NICUs) avoid this practice because resistant microorganisms often emerge. More recent studies suggest that prolonged empirical use of intravenous antibiotics (a very common practice in NICUs) actually results in an increased incidence of necrotizing enterocolitis.⁶⁰

PROBIOTIC AGENTS

Prospective randomized trials during the past decade have evaluated the effects of various probiotics to prevent necrotizing enterocolitis.⁶¹⁻⁶³ The most recently reported multicenter trial of probiotics suggested that the probiotic approach decreased the incidence of necrotizing enterocolitis but did not decrease mortality from necrotizing enterocolitis. However, there appears to be a higher incidence of sepsis among infants receiving probiotics,⁶⁴ especially in those with a birth weight of less than 750 g. Thus, caution in the use of probiotics seems wise, despite a recent commentary suggesting the routine use of probiotics on the basis of current data.⁶⁵ The Food and Drug Administration has not approved the administration of a microorganism in preterm infants. Furthermore, probiotic products have not been subjected to rigorous manufacturing quality control. The contents of such products, although they appear to be safe in individual studies, may not be reproducible according to drug or pharmaceutical standards. Before routine probiotic prophylaxis could be recommended to neonatologists, it would be important to have evidence in support of such use from at least one large, prospective, single-protocol, randomized, double-blind trial.

PREBIOTIC AGENTS

Another proposed preventive strategy is to supplement feedings with so-called prebiotics, or nutrients that enhance the growth of potentially benefi-

cial intestinal microbes.⁶⁶ Prebiotic agents include the oligosaccharides inulin, galactose, fructose, lactulose, and combinations of these nutrients.⁶⁷ Although these compounds appear to alter the consistency and frequency of stools, their efficacy in the prevention of necrotizing enterocolitis is unclear. Prebiotics enhance the proliferation of endogenous flora such as bifidobacteria, but they require an initial appropriate colonization of the gut, which appears to be lacking in very-low-birth-weight preterm infants.⁶⁸ Oligosaccharides in human milk have been proposed as alternatives to plant-based and synthetic prebiotic agents.⁶⁹ The theoretical benefit of such preparations has been reviewed,⁶⁶ but little information is currently available to provide support for a benefit in the prevention of necrotizing enterocolitis.

MICROBIAL COMPONENTS THAT MODULATE INFLAMMATION

Studies in epithelial cells and in a model of rats fed infant formula suggest that dead microbes may be as effective as live microbes in modulating excessive inflammatory stimuli.⁷⁰⁻⁷³ Experimental data suggest that specific microbial components that affect toll-like receptor (TLR) signaling could also be effective. For example, studies involving a mouse model used isolated, purified, primary intestinal epithelial cells from fetal and neonatal mice and reported high lipopolysaccharide reactivity in the fetus, which decreased after vaginal birth in the newborn, presumably through interleukin-1 receptor-associated kinase 1 (IRAK-1),⁷⁴ an important cellular signaling step in inflammation. If the pups were delivered by cesarean section, the cells continued to respond to lipopolysaccharide, suggesting that those neonates in which IRAK-1 expression was not decreased may have had an increased risk of intestinal inflammation and injury.

Studies in rat or mouse models of necrotizing enterocolitis suggest that the expression of TLR4 may be critical in the pathogenesis of this condition.^{75,76} Studies both in these models and in resected intestine from infants with necrotizing enterocolitis suggest that there are more TLR4 surface receptors in these infants than in full-term infants or animals without necrotizing enterocolitis. Other studies indicate that TLR4 surface expression is increased under conditions associated with necrotizing enterocolitis or intestinal inflammation.^{76,77} The location of TLRs on the surface or within the enterocyte may also limit activation by colonizing bacteria. TLRs have differential localization (e.g., intracellular vs. extracellular, apical vs. basolateral, and in relation to whether intercellular junctions are open or closed), depending on the level of inflammation and the type of microbes colonizing the intestine.³² The role and therapeutic potential of pharmaceutical or dietary interventions that may alter the accessibility of colonizing bacteria to TLRs and other receptors require additional elucidation.

FUTURE CONSIDERATIONS

Because of the fulminant nature of necrotizing enterocolitis, it is unlikely that new treatment

strategies will provide major breakthroughs in reducing its associated mortality and morbidity. Preventive approaches are likely to yield better results.

To develop effective preventive strategies, clear diagnostic criteria need to be used consistently to differentiate between necrotizing enterocolitis and other entities, such as spontaneous intestinal perforation and intestinal injury in term infants. Strategies for establishing and applying these criteria would include the development of highly sensitive specific biomarkers⁷⁸ and new techniques for detecting factors that confer a predisposition to necrotizing enterocolitis.⁷⁹ Consistent diagnostic criteria may also be helpful in evaluating the effects of different clinical practices among NICUs and then applying strategies that are successful. Specific preventive interventions may be applied to the most susceptible infants in studies that focus on enhancing innate immunity with human milk or avoiding manipulations that may alter normal microbial ecology and diversity, such as the unnecessary use of antibiotics. After decades of insufficient progress in the prevention and treatment of necrotizing enterocolitis, there are now tools that may lead toward the goal of eradicating this disease.

Disclosure forms provided by the authors are available with the full text of this article at NEJM.org.

REFERENCES

- Obladen M. Necrotizing enterocolitis — 150 years of fruitless search for the cause. *Neonatology* 2009;96:203-10.
- Grave GD, Nelson SA, Walker WA, et al. New therapies and preventive approaches for necrotizing enterocolitis: report of a research planning workshop. *Pediatr Res* 2007;62:510-4.
- Holman RC, Stoll BJ, Curns AT, Yorita KL, Steiner CA, Schonberger LB. Necrotizing enterocolitis hospitalizations among neonates in the United States. *Paediatr Perinat Epidemiol* 2006;20:498-506.
- Guillet R, Stoll BJ, Cotten CM, et al. Association of H2-blocker therapy and higher incidence of necrotizing enterocolitis in very low birth weight infants. *Pediatrics* 2006;117(2):e137-e142.
- Horbar JD, Badger GJ, Carpenter JH, et al. Trends in mortality and morbidity for very low birth weight infants, 1991-1999. *Pediatrics* 2002;110:143-51.
- Erasmus HD, Ludwig-Auser HM, Paterson PG, Sun D, Sankaran K. Enhanced weight gain in preterm infants receiving lactase-treated feeds: a randomized, double-blind, controlled trial. *J Pediatr* 2002;141:532-7.
- Fitzgibbons SC, Ching Y, Yu D, et al. Mortality of necrotizing enterocolitis expressed by birth weight categories. *J Pediatr Surg* 2009;44:1072-5.
- Hintz SR, Kendrick DE, Stoll BJ, et al. Neurodevelopmental and growth outcomes of extremely low birth weight infants after necrotizing enterocolitis. *Pediatrics* 2005;115:696-703.
- Salhab WA, Perlman JM, Silver L, Sue Broyles R. Necrotizing enterocolitis and neurodevelopmental outcome in extremely low birth weight infants <1000 g. *J Perinatol* 2004;24:534-40.
- Bedrick AD. Necrotizing enterocolitis: neurodevelopmental “risky business.” *J Perinatol* 2004;24:531-3.
- Stoll BJ, Hansen N, Fanaroff AA, et al. Late-onset sepsis in very low birth weight neonates: the experience of the NICHD Neonatal Research Network. *Pediatrics* 2002;110:285-91.
- Bisquera JA, Cooper TR, Berseth CL. Impact of necrotizing enterocolitis on length of stay and hospital charges in very low birth weight infants. *Pediatrics* 2002;109:423-8.
- Spencer AU, Kocovich D, McKinney-Barnett M, et al. Pediatric short-bowel syndrome: the cost of comprehensive care. *Am J Clin Nutr* 2008;88:1552-9.
- Martinez-Tallo E, Claire N, Bancalari E. Necrotizing enterocolitis in full-term or near-term infants: risk factors. *Biol Neonate* 1997;71:292-8.
- Raboei EH. Necrotizing enterocolitis in full-term neonates: is it aganglionosis? *Eur J Pediatr Surg* 2009;19:101-4.
- Gordon PV, Swanson JR, Attridge JT, Clark R. Emerging trends in acquired neonatal intestinal disease: is it time to abandon Bell's criteria? *J Perinatol* 2007;27:661-71.
- Gordon PV, Attridge JT. Understanding clinical literature relevant to spontaneous intestinal perforations. *Am J Perinatol* 2009;26:309-16.
- Stark AR, Carlo WA, Tyson JE, et al. Adverse effects of early dexamethasone in extremely-low-birth-weight infants. *N Engl J Med* 2001;344:95-101.
- Watterberg KL, Gerdes JS, Cole CH, et al. Prophylaxis of early adrenal insufficiency to prevent bronchopulmonary dysplasia: a multicenter trial. *Pediatrics* 2004;114:1649-57.

20. Neu J. Neonatal necrotizing enterocolitis: an update. *Acta Paediatr Suppl* 2005; 94:100-5.
21. Bell MJ, Ternberg JL, Feigin RD, et al. Neonatal necrotizing enterocolitis: therapeutic decisions based upon clinical staging. *Ann Surg* 1978;187:1-7.
22. Walsh MC, Kliegman RM. Necrotizing enterocolitis: treatment based on staging criteria. *Pediatr Clin North Am* 1986; 33:179-201.
23. Swanson JR, Attridge JT, Gordon PV. Potential confounder of NEC clinical trials. *J Perinatol* 2009;29:256-7.
24. Rees CM, Eaton S, Khoo AK, Kiely EM. Peritoneal drainage does not stabilize extremely low birth weight infants with perforated bowel: data from the NET Trial. *J Pediatr Surg* 2010;45:324-8.
25. Epelman M, Daneman A, Navarro OM, et al. Necrotizing enterocolitis: review of state-of-the-art imaging findings with pathologic correlation. *Radiographics* 2007; 27:285-305.
26. Moss RL, Dimmitt RA, Barnhart DC, et al. Laparotomy versus peritoneal drainage for necrotizing enterocolitis and perforation. *N Engl J Med* 2006;354:2225-34.
27. Rees CM, Eaton S, Kiely EM, Wade AM, McHugh K, Pierro A. Peritoneal drainage or laparotomy for neonatal bowel perforation? A randomized controlled trial. *Ann Surg* 2008;248:44-51.
28. Sola JE, Tepas JJ III, Koniaris LG. Peritoneal drainage versus laparotomy for necrotizing enterocolitis and intestinal perforation: a meta-analysis. *J Surg Res* 2010;161:95-100.
29. Blakely ML, Tyson JE, Lally KP, et al. Laparotomy versus peritoneal drainage for necrotizing enterocolitis or isolated intestinal perforation in extremely low birth weight infants: outcomes through 18 months adjusted age. *Pediatrics* 2006; 117(4):e680-e687.
30. Martin CR, Walker WA. Intestinal immune defences and the inflammatory response in necrotising enterocolitis. *Semin Fetal Neonatal Med* 2006;11:369-77.
31. Otte JM, Podolsky DK. Functional modulation of enterocytes by gram-positive and gram-negative microorganisms. *Am J Physiol Gastrointest Liver Physiol* 2004;286:G613-G626.
32. Abreu MT. The Ying and Yang of bacterial signaling in necrotizing enterocolitis. *Gastroenterology* 2010;138:39-43.
33. Fusunyan RD, Nanthakumar NN, Baldeon ME, Walker WA. Evidence for an innate immune response in the immature intestine: toll-like receptors on fetal enterocytes. *Pediatr Res* 2001;49:589-93.
34. Claud EC, Lu L, Anton PM, Savidge T, Walker WA, Cherayil BJ. Developmentally regulated IkappaB expression in intestinal epithelium and susceptibility to flagellin-induced inflammation. *Proc Natl Acad Sci U S A* 2004;101:7404-8.
35. Sharma R, Tepas JJ III, Hudak ML, et al. Neonatal gut barrier and multiple organ failure: role of endotoxin and proinflammatory cytokines in sepsis and necrotizing enterocolitis. *J Pediatr Surg* 2007;42: 454-61.
36. Markel TA, Crisostomo PR, Wairiuko GM, Pitcher J, Tsai BM, Meldrum DR. Cytokines in necrotizing enterocolitis. *Shock* 2006;25:329-37.
37. Mukaida N. Interleukin-8: an expanding universe beyond neutrophil chemotaxis and activation. *Int J Hematol* 2000; 72:391-8.
38. Nanthakumar NN, Fusunyan RD, Sanderson I, Walker WA. Inflammation in the developing human intestine: a possible pathophysiologic contribution to necrotizing enterocolitis. *Proc Natl Acad Sci U S A* 2000;97:6043-8.
39. Claud EC, Walker WA. Hypothesis: inappropriate colonization of the premature intestine can cause neonatal necrotizing enterocolitis. *FASEB J* 2001;15:1398-403.
40. Morowitz MJ, Poroyko V, Caplan M, Alverdy J, Liu DC. Redefining the role of intestinal microbes in the pathogenesis of necrotizing enterocolitis. *Pediatrics* 2010; 125:777-85.
41. Schwiertz A, Gruhl B, Löbnitz M, Michel P, Radke M, Blaut M. Development of the intestinal bacterial composition in hospitalized preterm infants in comparison with breast-fed, full-term infants. *Pediatr Res* 2003;54:393-9.
42. Turnbaugh PJ, Ley RE, Hamady M, Fraser-Liggett CM, Knight R, Gordon JI. The human microbiome project. *Nature* 2007;449:804-10.
43. Hattori M, Taylor TD. The human intestinal microbiome: a new frontier of human biology. *DNA Res* 2009;16:1-12.
44. Wang Y, Hoenig JD, Malin KJ, et al. 16S rRNA gene-based analysis of fecal microbiota from preterm infants with and without necrotizing enterocolitis. *ISME J* 2009;3:944-54.
45. Mshvildadze M, Neu J, Shuster J, Theriaque D, Li N, Mai V. Intestinal microbial ecology in premature infants assessed with non-culture-based techniques. *J Pediatr* 2010;156:20-5.
46. Vollaard EJ, Clasener HA. Colonization resistance. *Antimicrob Agents Chemother* 1994;38:409-14.
47. Lloyd JR. The etiology of gastrointestinal perforations in the newborn. *J Pediatr Surg* 1969;4:77-84.
48. Crissinger KD. Regulation of hemodynamics and oxygenation in developing intestine: insight into the pathogenesis of necrotizing enterocolitis. *Acta Paediatr Suppl* 1994;396:8-10.
49. Nowicki PT, Nankervis CA. The role of the circulation in the pathogenesis of necrotizing enterocolitis. *Clin Perinatol* 1994;21:219-34.
50. Davey AM, Wagner CL, Cox C, Kendig JW. Feeding premature infants while low umbilical artery catheters are in place: a prospective, randomized trial. *J Pediatr* 1994;124:795-9.
51. Mally P, Golombek SG, Mishra R, et al. Association of necrotizing enterocolitis with elective packed red blood cell transfusions in stable, growing, premature neonates. *Am J Perinatol* 2006;23:451-8.
52. Anderson DM, Kliegman RM. The relationship of neonatal alimentation practices to the occurrence of endemic necrotizing enterocolitis. *Am J Perinatol* 1991; 8:62-7.
53. Moss RL, Kalish LA, Duggan C, et al. Clinical parameters do not adequately predict outcome in necrotizing enterocolitis: a multi-institutional study. *J Perinatol* 2008;28:665-74.
54. Lucas A, Cole TJ. Breast milk and neonatal necrotising enterocolitis. *Lancet* 1990;336:1519-23.
55. Meinen-Derr J, Poindexter B, Wrage L, Morrow AL, Stoll B, Donovan EF. Role of human milk in extremely low birth weight infants' risk of necrotizing enterocolitis or death. *J Perinatol* 2009;29:57-62.
56. Quigley MA, Henderson G, Anthony MY, McGuire W. Formula milk versus donor breast milk for feeding preterm or low birth weight infants. *Cochrane Database Syst Rev* 2007;4:CD002971.
57. Sullivan S, Schanler RJ, Kim JH, et al. An exclusively human milk-based diet is associated with a lower rate of necrotizing enterocolitis than a diet of human milk and bovine milk-based products. *J Pediatr* 2010;156(4):562.e1-567.e1.
58. Grylack LJ, Scanlon JW. Oral gentamicin therapy in the prevention of neonatal necrotizing enterocolitis: a controlled double-blind trial. *Am J Dis Child* 1978;132: 1192-4.
59. Egan EA, Mantilla G, Nelson RM, Eitzman DV. A prospective controlled trial of oral kanamycin in the prevention of neonatal necrotizing enterocolitis. *J Pediatr* 1976;89:467-70.
60. Cotten CM, Taylor S, Stoll B, et al. Prolonged duration of initial empirical antibiotic treatment is associated with increased rates of necrotizing enterocolitis and death for extremely low birth weight infants. *Pediatrics* 2009;123:58-66.
61. Lin HC, Su BH, Chen AC, et al. Oral probiotics reduce the incidence and severity of necrotizing enterocolitis in very low birth weight infants. *Pediatrics* 2005;115: 1-4.
62. Bin-Nun A, Bromiker R, Wilschanski M, et al. Oral probiotics prevent necrotizing enterocolitis in very low birth weight neonates. *J Pediatr* 2005;147:192-6.
63. Dani C, Biadaioli R, Bertini G, Martelli E, Rubaltelli FF. Probiotics feeding in prevention of urinary tract infection, bacterial sepsis and necrotizing enterocolitis

- in preterm infants: a prospective double-blind study. *Biol Neonate* 2002;82:103-8.
64. Lin HC, Hsu CH, Chen HL, et al. Oral probiotics prevent necrotizing enterocolitis in very low birth weight preterm infants: a multicenter, randomized, controlled trial. *Pediatrics* 2008;122:693-700.
 65. Tarnow-Mordi WO, Wilkinson D, Trivedi A, Brok J. Probiotics reduce all-cause mortality in necrotizing enterocolitis: it is time to change practice. *Pediatrics* 2010;125:1068-70.
 66. Gibson GR. Dietary modulation of the human gut microflora using prebiotics. *Br J Nutr* 1998;80:S209-S212.
 67. Sherman PM, Cabana M, Gibson GR, et al. Potential roles and clinical utility of prebiotics in newborns, infants, and children: proceedings from a global prebiotic summit meeting, New York City, June 27-28, 2008. *J Pediatr* 2009;155:S61-S70. [Erratum, *J Pediatr* 2010;156:344.]
 68. Moro G, Minoli I, Mosca M, et al. Dosage-related bifidogenic effects of galacto- and fructooligosaccharides in formula-fed term infants. *J Pediatr Gastroenterol Nutr* 2002;34:291-5.
 69. Donovan SM. Human milk oligosaccharides — the plot thickens. *Br J Nutr* 2009;101:1267-9.
 70. Zhang L, Li N, Caicedo R, Neu J. Live and dead *Lactobacillus rhamnosus* GG decrease tumor necrosis factor- α -induced interleukin-8 production in Caco-2 cells. *J Nutr* 2005;135:1752-6.
 71. Zhang L, Li N, des Robert C, et al. *Lactobacillus rhamnosus* GG decreases lipopolysaccharide-induced systemic inflammation in a gastrostomy-fed infant rat model. *J Pediatr Gastroenterol Nutr* 2006;42:545-52.
 72. Li N, Russell WM, Douglas-Escobar M, Hauser N, Lopez M, Neu J. Live and heat-killed *Lactobacillus rhamnosus* GG: effects on proinflammatory and anti-inflammatory cytokines/chemokines in gastrostomy-fed infant rats. *Pediatr Res* 2009;66:203-7.
 73. Lopez M, Li N, Kataria J, Russell M, Neu J. Live and ultraviolet-inactivated *Lactobacillus rhamnosus* GG decrease flagellin-induced interleukin-8 production in Caco-2 cells. *J Nutr* 2008;138:2264-8.
 74. Lotz M, Gütle D, Walther S, Ménard S, Bogdan C, Hornef MW. Postnatal acquisition of endotoxin tolerance in intestinal epithelial cells. *J Exp Med* 2006;203:973-84.
 75. Jilling T, Simon D, Lu J, et al. The roles of bacteria and TLR4 in rat and murine models of necrotizing enterocolitis. *J Immunol* 2006;177:3273-82.
 76. Leaphart CL, Cavallo J, Gribar SC, et al. A critical role for TLR4 in the pathogenesis of necrotizing enterocolitis by modulating intestinal injury and repair. *J Immunol* 2007;179:4808-20.
 77. Lu J, Caplan MS, Li D, Jilling T. Polyunsaturated fatty acids block platelet-activating factor-induced phosphatidylinositol 3 kinase/Akt-mediated apoptosis in intestinal epithelial cells. *Am J Physiol Gastrointest Liver Physiol* 2008;294:G1181-G1190.
 78. Young C, Sharma R, Handfield M, Mai V, Neu J. Biomarkers for infants at risk for necrotizing enterocolitis: clues to prevention? *Pediatr Res* 2009;65:91R-97R.
 79. Oh S, Young C, Gravenstein N, Islam S, Neu J. Monitoring technologies in the neonatal intensive care unit: implications for the detection of necrotizing enterocolitis. *J Perinatol* 2010;30:701-8.

Copyright © 2011 Massachusetts Medical Society.

NEW NEJM APPLICATION FOR iPhone

The NEJM Image Challenge app brings a popular online feature to the smartphone. Optimized for viewing on the iPhone and iPod Touch, the Image Challenge app lets you test your diagnostic skills anytime, anywhere. The Image Challenge app randomly selects from 300 challenging clinical photos published in NEJM, with a new image added each week. View an image, choose your answer, get immediate feedback, and see how others answered. The Image Challenge app is available at the iTunes App Store.