

# Neuroblastoma: Biology, Prognosis, and Treatment

Julie R. Park, MD<sup>a,\*</sup>, Angelika Eggert, MD<sup>b</sup>,  
Huib Caron, MD, PhD<sup>c</sup>

<sup>a</sup>*Division of Hematology and Oncology, University of Washington School of Medicine  
and Children's Hospital and Regional Medical Center, 4800 Sand Pt. Way NE,  
MS: B6553, Seattle, WA 98105-0371, USA*

<sup>b</sup>*Department of Hematology/Oncology, University Children's Hospital Essen,  
Hufelandstr. 55, 45122 Essen, Germany*

<sup>c</sup>*Department of Pediatric Oncology and Hematology, Emma Children's Hospital AMC,  
EKZ/AMC, P.O. Box 22700, 1100 DE, Amsterdam, the Netherlands*

Neuroblastoma, a neoplasm of the sympathetic nervous system, is the second most common extracranial malignant tumor of childhood and the most common solid tumor of infancy. Neuroblastoma is a heterogeneous malignancy with prognosis ranging from near uniform survival to high risk for fatal demise. Neuroblastoma serves as a paradigm for the prognostic utility of biologic and clinical data and the potential to tailor therapy for patient cohorts at low, intermediate, and high risk for recurrence. Overall survival is excellent for patients who have low- and intermediate-risk neuroblastoma with a general trend toward minimization of therapy. In contrast, a marked intensification of therapy has led to only incremental improvement in survival for high-risk disease because less than 40% of high-risk patients survive. Chemotherapy and radiotherapy resistance remain the hallmark of failure. This article summarizes our understanding of neuroblastoma biology and prognostic features and discusses their impact on current and proposed risk stratification schemas, risk-based therapeutic approaches, and the development of novel therapies for patients at high risk for failure.

## Epidemiology and cause

The incidence of neuroblastoma per year is 10.5 per million children less than 15 years of age [1]. Neuroblastoma accounts for 8% to 10% of all

---

\* Corresponding author.

*E-mail address:* julie.park@seattlechildrens.org (J.R. Park).

childhood cancers and for approximately 15% of cancer deaths in children. There seems to be no significant geographical variation in the incidence between North America and Europe, and there are no differences between races. Neuroblastoma occurs slightly more frequently in boys than girls (ratio 1.2:1). The incidence peaks at age 0 to 4 years, with a median age of 23 months. Forty percent of patients who present with clinical symptoms at diagnosis are under 1 year of age, and less than 5% with clinical symptoms are over the age of 10 years. Cases of familial neuroblastoma have been reported [2]. Environmental factors are implicated in the development of neuroblastoma (eg, paternal exposure to electromagnetic fields or prenatal exposure to alcohol, pesticides, or phenobarbital). A potential relationship with assisted pregnancies has also been made. None of these environmental factors has been confirmed in independent studies [3,4].

Screening for neuroblastoma was pioneered by Japanese investigators who demonstrated that asymptomatic tumors could be detected in infants by measurement of urinary catecholamine metabolites. The implementation of infant screening for neuroblastoma resulted in a doubling of neuroblastoma incidence to 20.1 per million children [5], and the tumors detected possessed favorable biological characteristics [6]. Although the outcome for the children with the detected tumors was excellent, these studies were not population based and did not demonstrate a resultant reduction in neuroblastoma mortality rates. The Quebec Neuroblastoma Screening Project and the German Neuroblastoma Screening Study were designed to identify whether screening a large cohort of infants for neuroblastoma at the ages of 3 weeks, 6 months, and 12 months could reduce the population-based incidence of advanced disease and mortality. These studies demonstrate that screening for neuroblastoma at or under the age of 1 year identifies tumors with a good prognosis and molecular pathology, doubles the incidence, and fails to detect the poor-prognosis disease that presents clinically at an older age [7,8].

### Genetic predisposition

Neuroblastoma can occur in patients affected with other neural crest disorders or malignancies, such as Hirschsprung disease, neurofibromatosis type 1, and congenital central hypoventilation syndrome [9–11]. Genomic linkage studies have not found evidence of a link between Hirschsprung disease and neuroblastoma development. The co-occurrence of neuroblastoma and von Recklinghausen disease is of interest because both disorders are deviations of normal neural-crest cell development in the embryo. An analysis of the reported coincidence of neuroblastoma and neurofibromatosis indicates that most of these cases can probably be accounted for by chance [12]. The *PHOX2B* gene is the major disease gene for the congenital central hypoventilation disorder, and constitutional *PHOX2B* mutations have been

identified in familial neuroblastoma cases [13] and in 2.3% of patients who have sporadic neuroblastoma [14].

Several cases of constitutional chromosome abnormalities have been reported in individuals who have neuroblastoma, but no consistent pattern has emerged [12]. Constitutional abnormalities involving the short arm of chromosome 1 have been reported for three neuroblastoma cases, possibly implicating chromosome 1 p loci in neuroblastoma predisposition. A report that familial neuroblastoma is not linked to 1p36 indicates that the predisposition locus for familial cases lies elsewhere.

Familial forms of neuroblastoma are rare, accounting for about 1% of all cases. There are few reported pedigrees of familial neuroblastoma [15]. In those families, the median age at diagnosis is 9 months, as opposed to 2 to 3 years in sporadic cases. An increased incidence of multiple primary tumors is also apparent. Analysis of the pedigree structures suggests a dominant mode of inheritance with low penetrance [15]. The limited number of families available for linkage studies has hindered the ability to map neuroblastoma-predisposing genes. Linkage studies aimed at chromosomal regions involved in neuroblastoma and candidate genes have not demonstrated convincing evidence of linkage [16,17]. Linkage of neuroblastoma predisposition to the chromosomal region 16p12-p13 was demonstrated in North American families [18]. In studies of European pedigrees, linkage to chromosome 12 p and 2 p was found [15]. No constitutional mutations in candidate genes in those regions have been reported.

## Pathology

### *Cell of origin and cancer stem cell hypothesis*

The peripheral neuroblastic tumors (pNTs), including neuroblastoma, belong to the “small blue round cell” neoplasms of childhood [19]. They are derived from progenitor cells of the sympathetic nervous system: the sympathogonia of the sympathoadrenal lineage. After migrating from the neural crest, these pluripotent sympathogonia form the sympathetic ganglia, the chromaffin cells of the adrenal medulla, and the paraganglia, reflecting the typical localizations of neuroblastic tumors.

The mechanisms causing persistence of embryonal cells that later give rise to pNTs are mainly unknown. Defects in embryonic genes controlling neural crest development are likely to underlie the unbalanced proliferation and disturbed differentiation of neuroblastoma [13,14,20]. These defects cause a disruption of the normal genetic differentiation program, resulting in an early or late differentiation block. The classic histopathologic pNT subtypes of neuroblastoma, ganglioneuroblastoma, and ganglioneuroma reflect a spectrum of maturation ranging from tumors with predominant undifferentiated neuroblasts to those largely consisting of fully differentiated neurons surrounded by a dense stroma of Schwann cells.

A hallmark of neuroblastoma is cellular heterogeneity. Although the presence of phenotypically diverse cells could be explained by ongoing mutagenesis, the cancer stem cell hypothesis has provided an intriguing alternative explanation for neuroblastoma heterogeneity. This hypothesis suggests that rare multipotent stem cells with indefinite potential for self-renewal drive the onset and growth of tumors. Although the existence of cancer stem cells in leukemia and some solid tumors has been established [21–23], neuroblastoma stem cells have not been clearly identified. Developmental programs controlling self-renewal in neuronal stem cells, including the Notch, Sonic hedgehog, and Wnt/ $\beta$ -catenin pathways, have been implicated in embryonal tumorigenesis [24–26]. It is conceivable that neuroblastoma stem cells arise from normal neural crest stem cells, partly preserving and partly dysregulating these pathways. The identification and characterization of cancer stem cells in neuroblastoma should permit a targeted approach to more effective treatment.

#### *Histopathologic assessment*

Primary, pretreatment tumor specimens obtained by open biopsy are optimal material for histologic examination and prognostic evaluation. The typical neuroblastoma is composed of small, uniformly sized cells containing dense hyperchromatic nuclei and scant cytoplasm. The Homer-Wright pseudorosette composed of neuroblasts surrounding areas of eosinophilic neuropil is seen in up to 50% of cases [27]. Distinguishing pNTs from other “small blue round cell” tumors often requires techniques beyond hematoxylin-eosin staining and light microscopy. In the immunohistochemical diagnosis of pNTs, positive staining for neural markers, including neuron-specific enolase, synaptophysin, neurofilament protein, ganglioside GD2, chromogranin A, and tyrosine hydroxylase, combined with negative staining for markers of other small-round-cell tumors should be considered. Electron microscopy typically demonstrates dense core, membrane-bound neurosecretory granules, microfilaments, and parallel arrays of microtubules within neuritic processes (neuropil) [19].

As early as 1963, Beckwith and Perrin suggested a natural history of pNTs that might include involution (regression) and maturation [28]. This hypothesis was based on their observation of “in situ neuroblastoma,” an adrenal lesion of microscopic size that is cytologically identical to typical neuroblastoma and is detected in infants with a frequency of 50 times the expected incidence of primary adrenal neuroblastoma. The concept of Beckwith and Perrin has been adopted and incorporated in the International Neuroblastoma Pathology Classification (INPC) [29]. The INPC was established in 1999 by adopting the original system proposed by Shimada in 1984 [30]. The INPC was revised in 2003 [31]. The INPC distinguishes a favorable histology group from an unfavorable histology group of pNTs by applying the concept of age-dependent normal ranges of morphologic features, such

as Schwannian stromal development, grade of neuroblastic differentiation, and mitosis-karyorrhexis index (Fig. 1).

According to the INPC, the pNTs are assigned to one of the following four basic morphologic categories.

*Neuroblastoma (Schwannian-stroma poor)*

A neuroblastoma is a tumor composed of neuroblastic cells forming groups or nests separated by stromal septa with none to limited Schwannian proliferation. This category consists of the three subtypes: (1) undifferentiated, (2) poorly differentiated (background of recognizable neuropil and <5% of cells showing differentiation), and (3) differentiating (abundant neuropil and >5% cells showing differentiation toward ganglion cells).

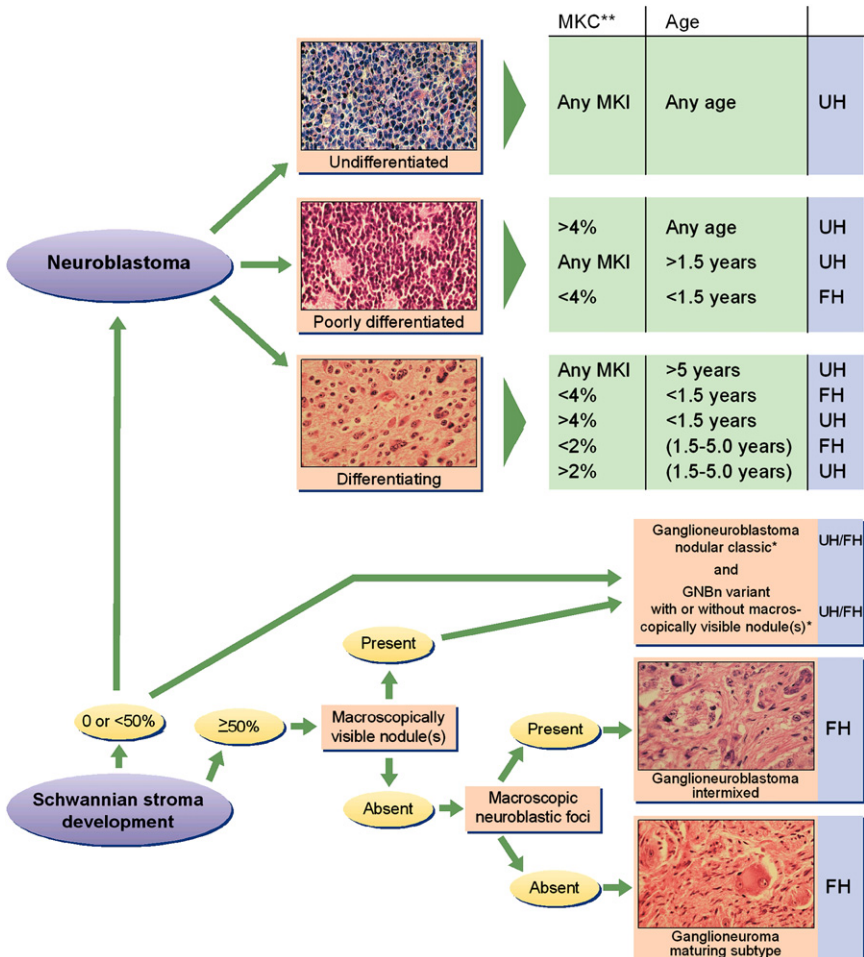


Fig. 1. International Neuroblastoma Pathology Classification.

*Ganglioneuroblastoma, intermixed (Schwannian stroma-rich)*

An intermixed ganglioneuroblastoma is a tumor containing well-defined microscopic nests of neuroblastic cells intermixed or randomly distributed in the ganglioneuromatous stroma. The nests are composed of a mixture of neuroblastic cells in various stages of differentiation, usually dominated by differentiating neuroblasts and maturing ganglion cells in a background of neuropil.

*Ganglioneuroblastoma, nodular (composite Schwannian stroma-rich/stroma dominant and stroma-poor)*

A nodular ganglioneuroblastoma is characterized by the presence of grossly visible, usually hemorrhagic neuroblastic nodules (stroma-poor component, representing an aggressive clone) co-existing with ganglioneuroblastoma, intermixed (stroma-rich component) or with ganglioneuroma (stroma-dominant component), both representing a nonaggressive clone. The term “composite” implies that the tumor is composed of biologically different clones.

*Ganglioneuroma (Schwannian-stroma-dominant)*

This variant has two subtypes: maturing and mature. The maturing subtype is composed predominantly of ganglioneuromatous stroma with scattered collections of differentiating neuroblasts or maturing ganglion cells in addition to fully mature ganglion cells. The mature subtype is composed of mature Schwannian stroma and ganglion cells.

There is a significant correlation between morphologic features of the INPC and biological properties of the pNTS, such as *MYCN* amplification or *TrkA* Expression.

**Clinical presentation, diagnosis, and staging**

Clinical presentation of neuroblastoma is dependent upon site of tumor origin, disease extent, and the presence of paraneoplastic syndromes. Neuroblastoma can arise anywhere along the sympathetic nervous system. The majority of tumors (65%) arise in the abdomen, with over half of these arising in the adrenal gland. Additional sites of origin include the neck, chest, and pelvis. There is a concordance with age and site of disease, with infants more likely to present with thoracic and cervical primary sites (Fig. 2). One percent of patients have no detectable primary tumor.

Approximately 50% of patients present with localized or regional disease, and approximately 35% of patients have regional lymph node spread at the time of diagnosis. Patients who have localized disease are often asymptomatic, with disease coincidentally diagnosed after testing for unassociated medical conditions. Alternatively, mass or abdominal distension and pain are present. Patients who have localized cervical disease arising from the

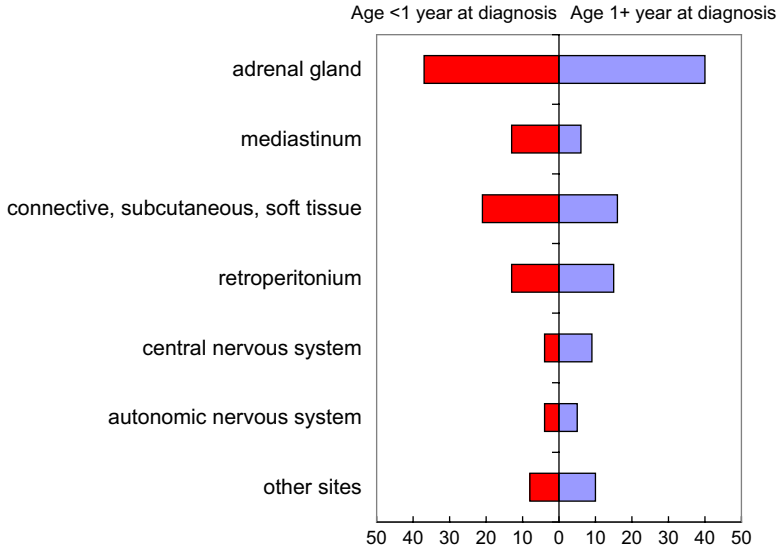


Fig. 2. Percent distribution of neuroblastomas by primary site and age; SEER 1975–1995. (Data from Ries LA, Smith MA, Gurney JG, et al. Cancer incidence and survival among children and adolescents: United States SEER Program 1975–1995. NIH Pub. No. 99-4649. Bethesda (MD): NIH; 1999.)

superior cervical ganglion may present with Horner syndrome. Epidural or intradural extension of tumor occurs in approximately 5% to 15% of patients diagnosed with neuroblastoma and may be accompanied by neurologic impairments [32,33]. Well-documented paraneoplastic or clinical syndromes can be present at diagnosis and are summarized in Table 1.

Disease dissemination occurs through lymphatic and hematogenous routes. Bone, bone marrow, and liver are the most common sites of hematogenous spread, with particular predilection for metaphyseal, skull, and orbital bone sites. In contrast to the frequent lack of symptoms with locoregional disease, patients who have widespread disease are often ill appearing with fever, pain, and irritability. A classic presentation of periorbital swelling and ecchymoses (“raccoon eyes”) is seen in children who have disease spread to periorbital region. Rarely, infants can present with respiratory compromise secondary to diffuse tumor involvement in the liver and massive hepatomegaly [34].

The current criteria for diagnosis and staging of neuroblastoma are based upon the International Neuroblastoma Staging System (INSS) criteria initially formulated in 1986 and revised in 1988 [35,36]. Neuroblastoma diagnosis is defined by pathologic confirmation from tumor tissue or by pathologic confirmation of neuroblastoma tumor cells in a bone marrow sample in the setting of increased urine or serum catecholamines or catecholamine metabolites (dopamine, vanillylmandelic acid, and homovanillic

Table 1  
Syndromes associated with neuroblastoma

Eponym	Syndrome features
Pepper syndrome	Massive involvement of the liver with metastatic disease with or without respiratory distress.
Horner syndrome	Unilateral ptosis, myosis, and anhidrosis associated with a thoracic or cervical primary tumor. Symptoms do not resolve with tumor resection.
Hutchinson syndrome	Limping and irritability in young child associated with bone and bone marrow metastases.
Opsoclonus Myoclonus Ataxia syndrome	Myoclonic jerking and random eye movement with or without cerebellar ataxia. Often associated with a biologically favorable and differentiated tumor. The condition is likely immune mediated, may not resolve with tumor removal, and often exhibits progressive neuropsychologic sequelae [118–120].
Kerner-Morrison syndrome	Intractable secretory diarrhea due to tumor secretion of vasointestinal peptides. Tumors are generally biologically favorable [121–122].
Neurocristopathy syndrome	Neuroblastoma associated with other neural crest disorders, including congenital hypoventilation syndrome or Hirshprung disease. Germline mutations in the paired homeobox gene PHOX2B have been identified in a subset of such patients [13,20].

*Adapted from* Castleberry RP. Biology and treatment of neuroblastoma. *Pediatr Clin North Am* 1997;44:919–37; with permission.

acid). Initial diagnostic testing should include CT or MRI to evaluate primary tumor size and regional extent and to assess for distant spread to neck, thorax, abdomen, or pelvic sites. Brain imaging is recommended only if clinically indicated by examination or neurologic symptoms. Bilateral posterior iliac crest marrow aspirates and core biopsies are required to exclude marrow involvement. Metaiodobenzylguanidine, a norepinephrine analog, is concentrated selectively in sympathetic nervous tissue and, when labeled with radioactive iodine ( $I^{131}$  or  $I^{123}$ ), is an integral component of neuroblastoma staging and response evaluation [37]. A technetium bone scan should be considered for detection of cortical bone disease, especially in patients who have a negative metaiodobenzylguanidine scan.

The INSS definitions for neuroblastoma stage are listed in Table 2. Resectability implies tumor removal without removal of vital organs, compromise of major vessels, or patient disfigurement. Completely resected tumors are classified as stage 1, and partially resected regional tumors with or without regional nodal involvement are classified as stages 2 and 3 dependent upon amount of tumor resection, local invasion, and regional lymph node involvement. Stage 4 disease is defined as distant nodal or hematogenous spread of disease. A unique pattern of dissemination limited to liver, skin, and minimal bone marrow involvement has been described in infants (stage 4s), which has a potential for spontaneous regression in marked contrast to



Table 2  
International Neuroblastoma Staging System

Stage 1	Localized tumor with complete gross excision with or without microscopic residual disease; representative ipsilateral lymph nodes negative for tumor microscopically (nodes attached to and removed with the primary tumor may be positive)
Stage 2A	Localized tumor with incomplete gross resection; representative ipsilateral nonadherent lymph nodes negative for tumor microscopically
Stage 2B	Localized tumor with or without complete gross excision with ipsilateral nonadherent lymph nodes positive for tumor; enlarged contralateral lymph nodes must be negative microscopically
Stage 3	Unresectable unilateral tumor infiltrating across the midline <sup>a</sup> with or without regional lymph node involvement, localized unilateral tumor with contralateral regional lymph node involvement, or midline tumor with bilateral extension by infiltration (unresectable) or by lymph node involvement <sup>b</sup>
Stage 4	Any primary tumor with dissemination to distant lymph nodes, bone, bone marrow, liver, skin, or other organs (except as defined for stage 4S)
Stage 4S	Localized primary tumor (as defined for stage 1, 2A, or 2B) with dissemination limited to skin, liver, or bone marrow <sup>c</sup> (limited to infants < 1 yr of age)

Multifocal primary tumors (eg, bilateral adrenal primary tumors) should be staged according to the greatest extent of disease, as defined in the table, and followed by a subscript "M" (eg, 3<sub>M</sub>).

<sup>a</sup> The midline is defined as the vertebral column. Tumors originating on one side and crossing the midline must infiltrate to or beyond the opposite side of the vertebral column.

<sup>b</sup> Proven malignant effusion within the thoracic cavity if it is bilateral or the abdominal cavity upstages the patient to INSS stage 3.

<sup>c</sup> Marrow involvement in stage 4S should be minimal (ie, <10% of total nucleated cells identified as malignant on bone marrow biopsy or marrow aspirate). More extensive marrow involvement would be considered to be stage 4. The metaiodobenzylguanidine scan (if performed) should be negative in the marrow.

*Data from Brodeur GM, Pritchard J, Berthold F, et al. Revisions of the international criteria for neuroblastoma diagnosis, staging, and response to treatment. J Clin Oncol 1933;11(8):1466-77.*

the disseminated aggressive disease seen in the majority of patients greater than 18 months of age [34].

### Tumor biology and prognosis

Numerous clinical and biologic factors have been shown to predict clinical behavior of neuroblastoma. There is international agreement that a combination of clinical and biologic factors best predicts clinical prognosis. The Children's Oncology Group stratifies patients into low-, intermediate-, or high-risk categories based upon age at diagnosis, INSS stage, tumor histopathology, DNA index (ploidy), and *MYCN* amplification status (Table 3), with each group displaying a unique risk for recurrence (Fig. 3). Similar strategies are used internationally; however, several factors outlined below suggest a potential for continued evolution of any classification algorithm.

Table 3  
Children's Oncology Group neuroblastoma risk stratification

Risk group	Stage	Age	<i>MYCN</i> Amplification Status	Ploidy	Shimada
Low risk	1	Any	Any	Any	Any
Low risk	2a/2b	Any	Not amplified	Any	Any
High risk	2a/2b	Any	Amplified	Any	Any
Intermediate risk	3	< 547 d	Not amplified	Any	any
Intermediate risk	3	≥ 547 d	Not amplified	Any	FH
High risk	3	Any	Amplified	Any	Any
High risk	3	≥ 547 d	Not amplified	Any	UH
High risk	4	< 365 d	Amplified	Any	Any
Intermediate risk	4	< 365 d	Not amp	Any	Any
High risk	4	365 to < 547 d	Amplified	Any	Any
High Risk	4	365 to < 547 d	Any	DI = 1	Any
High risk	4	365 to < 547 d	Any	Any	UH
Intermediate risk	4	365 to < 547 d	Not amplified	DI > 1	FH
High risk	4	≥ 547 d	Any	Any	Any
Low risk	4s	< 365 d	Not amplified	DI > 1	FH
Intermediate risk	4s	< 365 d	Not amplified	DI = 1	Any
Intermediate risk	4s	< 365 d	Not amplified	Any	UH
High risk	4s	< 365 d	Amplified	Any	Any

*Abbreviations:* DI, DNA index; FH, favorable histology; UH, unfavorable histology.  
*Courtesy of Children's Oncology Group.*

### Stage and age

Although the prognostic value of classifying patients according to the INSS has been confirmed [38,39], an inherent bias toward complete resection

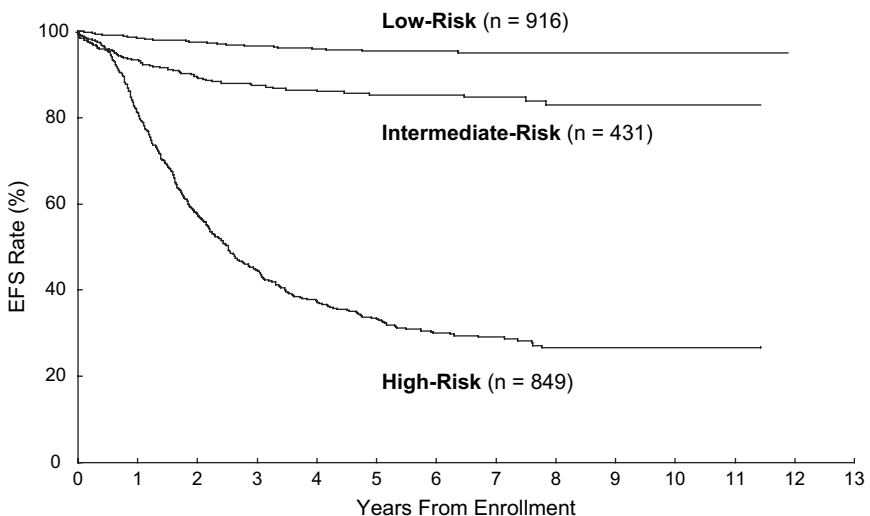


Fig. 3. Analysis of event free survival by risk stratification. (*Courtesy of W.B. London, PhD, Children's Oncology Group Statistical Office.*)

exists. Variation in the surgical approach for resection of locoregional disease has the potential to dramatically alter INSS staging. Such variation has led to considerations of alternative staging approaches. In 1995, the European International Society of Pediatric Oncology Neuroblastoma group demonstrated that radiographic characteristics of the tumor, termed surgical risk factors, were useful in predicting the ability to resect the primary tumor and the risk of developing postoperative complications [40]. This led to proposing an International Risk Group imaging classification system that would use surgical risk factors to more uniformly define extent of disease/staging [41]. The prognostic significance of the International Risk Group classification system will be prospectively validated in ongoing trials within the United States and Europe and, if validated, may replace the current INSS staging.

Age is an important clinical prognostic factor. Patients older than 1 to 2 years have a worse prognosis than those who are younger [42,43], especially for patients who have disseminated disease at diagnosis. Until recently, an age of 365 days has been used as a surrogate for tumor behavior, although alternative ages have been explored. A review of over 3000 neuroblastoma cases confirmed age as a continuous prognostic variable and identified 460 days as the most prognostic age cutoff [44]. Recent reviews demonstrated that patients up to 18 months of age who are diagnosed with biologically favorable INSS stage 3 and 4 neuroblastoma share the same excellent prognosis with those less than 1 year of age [45–47] and suggests that 18 months may be a more clinically relevant predictor of outcome. These outcomes were achieved with dose-intensive chemotherapy regimens, including myeloablative consolidation therapy as compared with the moderately dosed chemotherapy received by the more biologically favorable patient cohorts. The ability to treat children ages 12 to 18 months of age who have metastatic disease or locoregional disease using less aggressive therapy is under investigation.

### *Pathology*

The pathologic characteristics of neuroblastoma have been used to further classify these tumors as outlined previously. Shimada initially proposed a histology-based classification of tumors into “favorable” and “unfavorable” by combining age with extent of tumor differentiation, presence of a Schwannian stromal components, and degree of mitosis and karyorrhexis [30]. The prognostic impacts of the original Shimada classification and the more recently revised INPC have been validated [30,48]. The inclusion of age, which is a strong independent prognostic variable, has led to consideration for examining cellular proliferation and extent of differentiation as independent variables in future multifactorial clinical and biological classification schemas.

### *Genetic factors*

Neuroblastoma can be divided into those with a near-diploid nuclear DNA content ( $\approx 45\%$ ) and near-triploid tumors ( $\approx 55\%$ ). Near-triploid

neuroblastomas are characterized by whole chromosome gains and losses without structural genetic aberrations. Clinically, near-triploid tumors are more often localized and show a favorable outcome. Near-diploid neuroblastomas are characterized by the presence of genetic aberrations, such as *MYCN* amplification, 17q gain, and chromosomal losses (reviewed in references [12,49]). For many genetic, molecular, and clinical factors, a prognostic value has been reported. Recently, a systematic review of prognostic tumor markers in neuroblastoma has been published [50]. Riley and co-workers identified 3415 papers with a sensitive literature search for prognostic factors in neuroblastoma, of which 428 were judged to be relevant. In total, 31 prognostic factors were reported, each in five or more papers. Among these 31 prognostic factors, there were six genetic aberrations listed (ploidy, *MYCN* amplification, chromosome 1 p loss, chromosome 17q gain, chromosome 14q loss, and loss of chromosome 11q). Meta-analysis of prognostic markers showed that *MYCN* amplification and DNA ploidy had the strongest prognostic impact. The pooled hazard ratio for a bad outcome (measured by overall survival) for *MYCN* amplification was 5.48 (95% confidence interval, 4.30–6.97) and for DNA near-diploidy was 3.23 (95% confidence interval, 2.08–5.00).

Most neuroblastomas have a nuclear DNA content in the diploid range. Tumors from patients who have lower stages of disease can often be hyperdiploid or near-triploid (reviewed in references [12,49]). DNA content is most prognostic in infants who have neuroblastoma. The Children's Oncology Group is the only collaborative group using ploidy of diagnostic tumor specimen for risk stratification (see Table 3).

#### *Allelic gains and amplifications*

The *MYCN* oncogene is present in an increased copy number in 25% to 35% of neuroblastomas. *MYCN* amplification is found in 30% to 40% of stage 3 and 4 neuroblastomas and in only 5% of localized or stage 4s neuroblastomas. *MYCN*-amplified neuroblastomas are characterized by a highly aggressive behavior with unfavorable outcome (reviewed in [12,49]). Some discussion remains on the prognostic value of *MYCN* amplification in the rare cases of completely resected localized neuroblastoma. The unfavorable prognostic value also holds in the prognostically favorable group of infants who have stage 4s neuroblastoma. In *MYCN*-amplified neuroblastomas, loss of chromosome 1 p is almost invariably present [49,51].

#### *Allelic gains*

Gain of the entire chromosome 17 or gain of parts of chromosome 17q occur in greater than 60% of neuroblastomas. The partial 17q gain most often results from unbalanced translocation of 17q21–25 to another chromosome (eg, chromosome 1). Partial gain of 17q identifies unfavorable

neuroblastoma [52]. Obvious candidate genes on 17q are the NM23 and the BIRC5 (survivin) gene.

### *Tumor suppressor genes*

Loss of tumor suppressor regions is reported in neuroblastomas for many chromosomal regions. The most frequently affected regions are chromosome 1 p (30–40%), 4 p (20%), 11q (25%), and 14q (25%).

Chromosome 1 p loss occurs more frequently in older children who have stage 3 and 4 neuroblastoma and is correlated with increased serum ferritin and serum lactate dehydrogenase. In almost all samples with *MYCN* amplification, concomitant 1 p loss is demonstrated, but loss of chromosome 1 p also occurs in *MYCN* single-copy cases [53]. Several studies have shown that 1 p loss is a strong predictor of outcome [12,49,53]. In the meta-analysis of Riley and colleagues [50], *MYCN* amplification and ploidy were stronger predictors of outcome, indicating that 1 p loss might best be used to identify high-risk patients in *MYCN* single-copy tumors.

Chromosome 11q loss is demonstrated in approximately 40% of patients (reviewed in [12,49]). Chromosome 11q loss is inversely correlated with *MYCN* amplification and therefore identifies an additional high-risk subset of patients characterized by advanced stage, older age, and unfavorable pathology. It has recently become clear that “unbalanced” deletion of 11q (deletion of long-arm material with retention or gain of short-arm material) occurs in 15% to 20% of cases but is more clearly associated with high-risk biologic features [54]. Prospective evaluation of 1 p and 11q status is ongoing in several cooperative group trials and is especially aimed at risk stratification of intermediate-risk patients.

### *Molecular factors*

Despite extensive data correlating genomic alterations with disease outcome, no bona fide target genes have been identified for neuroblastoma, with the exception of *MYCN* [55]. A number of biological pathways regulating cancer seem to be disrupted or affected in neuroblastoma, including tumor differentiation, apoptosis, drug resistance, angiogenesis, and metastasis. Insight into the molecular regulation of these biological pathways will lead to the identification of novel drug targets.

Because neurotrophin signaling has a central role in normal neuronal development and may be involved in differentiation and regression of neuroblastoma there has been interest in alterations of these pathways. The clinical and biological roles of Trk receptors (*NTRK1*, *NTRK2*, and *NTRK3* encoding TrkA, TrkB, and TrkC, respectively) and their ligands (NGF, BDNF, and NT-3, respectively) have been extensively investigated. Trk-receptors have been identified as important prognostic factors in neuroblastoma [56,57]. High expression of TrkA is present in neuroblastomas, with favorable biological features and correlates with good outcome

[58–61]. By contrast, full-length TrkB is highly expressed in biologically unfavorable, *MYCN*-amplified, aggressive neuroblastomas [56,62]. In neuroblastoma cell culture models, the biological effects of TrkA include neuronal differentiation or apoptosis, depending on the presence or absence of NGF and on inhibition of proliferation and angiogenesis [63,64]. TrkA signaling might also be related to Phox2B- or Delta-Notch-regulated differentiation programs. Depending on the microenvironment, NGF/TrkA signaling could provoke differentiation or regression in favorable neuroblastomas [14,65]. This would partly explain spontaneous regression as a delayed activation of developmentally programmed cell death resulting from the absence of NGF in the microenvironment.

Activation of TrkB by its ligand BDNF results in enhanced proliferation, migration, angiogenesis, and chemotherapy resistance of neuroblastoma cells [66]. Differential splicing of Trk receptors results in the expression of truncated receptors lacking the kinase domain [67], which may function as dominant negative inhibitors or scavenger receptors sequestering the ligand [68–70]. Truncated TrkB seems to be preferentially expressed in more differentiated tumors [62,71]. Recently, a novel NGF-unresponsive TrkA splice variant has been identified, which is predominantly expressed in clinically aggressive neuroblastomas. This splice variant promotes cell survival, xenograft tumor growth, and angiogenesis [72]. Thus, the neurotrophins and their receptors govern numerous cellular functions in neuroblastoma, and the complexity of the signaling responses is reflected in the multiplicity of the pathways involved. More detailed insights into the mechanisms regulating differentiation might suggest new options for treatment.

Delayed activation or disruption of normal apoptotic pathways may be an important phenomenon involved in spontaneous regression and therapy resistance of neuroblastoma. Major elements of the apoptotic signaling cascade with abnormal expression or activation patterns include the BCL2 family, survivin, and caspase-8 [73–76]. The latter is mainly affected by inactivation due to epigenetic silencing. CpG-island hypermethylation of gene promoters is a frequent mechanism for functional inactivation of genes. In neuroblastoma, this mode of inactivation has been demonstrated not only for caspase-8 but also for the four TRAIL apoptosis receptors, the caspase-8 inhibitor FLIP, the RASSF1A tumor suppressor, p73, RB1, DAPK, CD44, p14ARF, and p16INK4a [74,77]. Because many of these genes are involved in apoptotic signaling and therapy responsiveness, gene hypermethylation might be a major event leading to resistance. Therefore, the antitumor effects of demethylating agents, including decitabine, are being investigated in preclinical studies.

Acquired resistance to chemotherapeutic agents may be conferred by enhanced drug efflux due to overexpression of classical multidrug resistance proteins, including multidrug resistance gene 1 and the gene for multidrug resistance-related protein. Their potential clinical significance in neuroblastoma has been addressed in several studies [78–81], but their interaction with

each other and the role of unknown cofactors remains to be elucidated. Several additional factors have been shown to contribute to treatment resistance in neuroblastoma, including expression of oncogenes such as *MYCN*, *TrkB*/*BDNF* signaling, or loss of *p53* expression [66,82,83].

Enhanced tumor angiogenesis and high expression of proangiogenic factors such as vascular endothelial growth factor and basic fibroblast growth factor are correlated with an aggressive phenotype in neuroblastoma [64,84], making angiogenesis inhibitors an attractive treatment option that is being evaluated in preclinical studies. Despite the fact that approximately 50% of patients present with disseminated disease at the time of diagnosis, little is known about the biology of invasion and metastases in neuroblastoma. Major molecular players in the regulation of local invasiveness and metastases are metalloproteinases (mainly *MMP9*), activating matrix-degrading proteolytic enzymes, and molecules regulating tumor cell adhesion and migration, such as *CD44* and *NM23-H1* [85–88].

### Treatment overview

It is imperative that a multidisciplinary approach to diagnosis and therapy be undertaken for all patients. Tumor tissue obtained through surgical tumor biopsy is almost uniformly required to assess tumor genetic and histologic features. The improved understanding of neuroblastoma biology and its impact on prognosis has resulted in successful tailoring of therapy. The requirement for further surgical resection, chemotherapy, or radiotherapy is based upon a patient's risk stratification with general principles of therapy outlined below. When possible, exposure to chemotherapy is limited to patients who have regional or advanced-stage disease, whereas radiotherapy is limited to patients who have advanced disease and unfavorable biologic characteristics.

### Low-risk neuroblastoma

Survival rates for patients who have INSS stage 1 disease, regardless of biologic factors, are excellent with surgery alone. Chemotherapy, when necessary, has been an effective salvage therapy for patients who have INSS stage 1 disease who relapse after surgery only [89,90]. Chemotherapy can be omitted for the majority of patients who have biologically favorable but incompletely resected localized tumors (INSS stage 2A and 2B), with a survival rate greater than 95% [90–93]. For patients who have INSS stage 1, 2A, or 2B disease, chemotherapy should be reserved for those who have localized neuroblastoma and experience life- or organ-threatening symptoms at diagnosis or for the minority of patients who experience recurrent or progressive disease.

Stage 4S neuroblastoma without *MYCN* amplification undergoes spontaneous regression in the majority of cases [34,94]. Chemotherapy or low-dose

radiotherapy is reserved for patients who have large tumors or massive hepatomegaly causing mechanical obstruction, respiratory insufficiency, or liver dysfunction [95,96].

### **Intermediate-risk neuroblastoma**

The intermediate-risk classification group encompasses a wide spectrum of disease. Surgical resection and moderate-dose, multiagent chemotherapy are the backbone of therapy. The prognosis for patients who have INSS stage 3 disease or infants who have INSS stage 4 disease is highly dependent upon the tumor's histologic and biologic features. Survival after surgical resection and moderate-dose chemotherapy, including cisplatin, doxorubicin, etoposide, and cyclophosphamide, is greater than 95% for children whose tumors exhibit favorable characteristics [97,98]. To reduce acute and long-term toxicity, international groups have successfully reduced the cumulative exposure to chemotherapy and substituted carboplatin for cisplatin while maintaining excellent survival [99]. These promising results have provided the basis for further reduction in therapy for patients who have intermediate-risk disease. Several small series have brought to question whether chemotherapy could be eliminated for patients who have regional disease and favorable biologic characteristics [100,101]. The challenge is to use more recently identified biologic features to identify patients within this heterogeneous intermediate risk group for whom therapy reduction may not be warranted. Prospective clinical trials in the United States and Europe will integrate additional molecular genetic variables (1 p and 11q allelic status) to further refine risk assessment within the intermediate-risk group.

### **High-risk neuroblastoma**

High-risk neuroblastoma is largely chemotherapy responsive, but, despite improvements in complete response rates, only 30% to 40% of patients survive long term [102]. Standard therapy for patients who have high-risk neuroblastoma involves at least four components: induction, local control, consolidation, and treatment of minimal disease with biologic agents. The use of these four components has evolved over the last 20 years based upon work by the Pediatric Oncology Group, the Children's Cancer Group (CCG), international cooperative groups, and smaller cohort studies, with results summarized below.

#### *Induction therapy*

There is a direct correlation between achieving complete tumor response after induction therapy and survival [102]. Standard induction chemotherapy consists of a combination of anthracyclines, alkylators, platinum compounds, and topoisomerase II inhibitors. Escalation in chemotherapy dose



intensity may improve initial tumor response rates [103]; however, these results have not been reproduced in multicenter trials [104,105]. An alternative induction strategy is to add noncross-resistant cytotoxic agents into this multiagent chemotherapy backbone. The topoisomerase I inhibitor class of agents, including topotecan, has activity in recurrent neuroblastoma [106] and can be safely combined with multiagent induction chemotherapy [107]. The efficacy of this strategy is being studied in a phase III Children's Oncology Group trial for newly diagnosed neuroblastoma.

### *Local control*

Optimal local control is achieved with a combination of aggressive surgical resection and administration of external-beam radiotherapy to the primary tumor site regardless of response to induction chemotherapy. Resection of the primary tumor and bulky metastatic disease is usually necessary to achieve a chance of cure. Delayed surgical resection after initial induction chemotherapy improves resection of the primary tumor, may improve overall survival, and may minimize acute complications of surgical resection [108].

Neuroblastoma is one of the most radiosensitive solid tumors of childhood [109]. Radiation doses of 2160 cGy in daily 180 cGy fractions administered to the primary tumor site, regardless of initial response to chemotherapy, seem to decrease the risk for local recurrence [33,110,111]. The presence of residual tumor at the time of radiation therapy affects risk for recurrence. A single-institution study suggests that patients undergoing an incomplete resection may benefit from a higher radiation dose [112]. Prospective studies are ongoing to assess whether higher-dose radiation to the volume of residual tumor improves local control rates.

### *Myeloablative consolidation therapy*

Over the past decade, several clinical trials have assessed the efficacy of myeloablative consolidation chemotherapy. The CCG-3891 study demonstrated that myeloablative therapy with purged bone marrow transplant improved outcome for patients who had high-risk neuroblastoma [102]. Trials performed in Germany and Europe similarly demonstrate improved outcome after myeloablative therapy compared with maintenance chemotherapy [113] or observation [114]. Taken together, these data indicate that neuroblastoma is one of the few human cancers in which relapse rates are reduced by myeloablative consolidation in first remission and raise the possibility that further intensification of consolidation therapy may improve outcome. George and colleagues have recently published a 3-year, event-free survival of 55% after a rapid sequential tandem transplant consolidation therapy [115], forming the basis for an ongoing randomized trial comparing single- versus tandem transplant consolidation for high-risk neuroblastoma.

### *Biologic therapy*

The CCG-3891 study demonstrated the efficacy of isotretinoin (cis-RA), a synthetic retinoid, in treating minimal residual neuroblastoma and established a standard for the use of noncytotoxic therapy for the treatment of minimal residual disease [102]. Although cis-RA is the standard of care for postremission induction maintenance therapy, monoclonal antibodies directed against neuroblastoma-specific antigens (gangliosidase, GD2) may provide an additional mechanism to kill residual neuroblastoma cells via antibody-dependant cellular cytotoxicity. Preclinical and clinical trials suggest that lymphocyte-, neutrophil-, or natural killer cell-mediated, antibody-dependent cellular cytotoxicity can be enhanced by coadministration of the cytokines granulocyte/macrophage colony-stimulating factor and interleukin-2 [116,117]. Clinical trials are underway to analyze the efficacy of coadministration of soluble cytokines with anti-GD2 (gangliosidase) monoclonal antibodies or the development of fused anti-GD2/cytokine molecules in the setting of minimal residual disease. Alternative retinoid derivatives, including fenretinide, have been tested and show promising response rates in recurrent disease.

### **Future directions**

Neuroblastoma is a heterogeneous tumor for which biology dictates clinical behavior. Further advances in our understanding of the molecular biology of neuroblastoma are supported by the use of high-throughput, array-based methods not only with the goal of patient-tailored prognostication but also to identify key targets that can efficiently be exploited therapeutically. We must continue to refine our ability to better identify the rare patients who have apparent low-risk or intermediate-risk disease who are destined to have a poor outcome. For the remaining patients who have low- and intermediate-risk disease, we must minimize the lasting effects of therapy, specifically avoiding organ damage or organ loss from surgery and organ dysfunction or risk for secondary malignancy after chemotherapy. Likewise, it is imperative that we use the mounting knowledge of neuroblastoma tumor biology toward the development of novel therapies for high-risk neuroblastoma. Several rationally chosen biologic agents are in ongoing clinical trials for recurrent neuroblastoma, including histone deacetylase inhibitors, Trk tyrosine kinase inhibitors, and anti-angiogenic agents. If effective, these agents will be moved into front-line therapy and may improve induction response. Alternatively, they may be used to optimize treatment of minimal residual disease.

### **References**

- [1] Stillier CA, Parkin DM. International variations in the incidence of neuroblastoma. *Int J Cancer* 1992;52(4):538-43.

- [2] Kushner BH, Gilbert F, Helson L. Familial neuroblastoma: case reports, literature review, and etiologic considerations. *Cancer* 1986;57(9):1887–93.
- [3] Belson M, Kingsley B, Holmes A. Risk factors for acute leukemia in children: a review. *Environ Health Perspect* 2007;115(1):138–45.
- [4] Connelly JM, Malkin MG. Environmental risk factors for brain tumors. *Curr Neurol Neurosci Rep* May 2007;7(3):208–14.
- [5] Yamamoto K, Hayashi Y, Hanada R, et al. Mass screening and age-specific incidence of neuroblastoma in Saitama Prefecture, Japan. *J Clin Oncol* 1995;13(8):2033–8.
- [6] Kaneko Y, Kanda N, Maseki N, et al. Current urinary mass screening for catecholamine metabolites at 6 months of age may be detecting only a small portion of high-risk neuroblastomas: a chromosome and N-myc amplification study. *J Clin Oncol* 1990;8(12):2005–13.
- [7] Schilling FH, Spix C, Berthold F, et al. Neuroblastoma screening at one year of age. *N Engl J Med* 2002;346(14):1047–53.
- [8] Woods WG, Gao RN, Shuster JJ, et al. Screening of infants and mortality due to neuroblastoma. *N Engl J Med* 2002;346(14):1041–6.
- [9] Clausen N, Andersson P, Tommerup N. Familial occurrence of neuroblastoma, von Recklinghausen's neurofibromatosis, Hirschsprung's agangliosis and jaw-winking syndrome. *Acta Paediatr Scand* 1989;78(5):736–41.
- [10] Rohrer T, Trachsel D, Engelcke G, et al. Congenital central hypoventilation syndrome associated with Hirschsprung's disease and neuroblastoma: case of multiple neurocristopathies. *Pediatr Pulmonol* 2002;33(1):71–6.
- [11] Trochet D, O'Brien LM, Gozal D, et al. PHOX2B genotype allows for prediction of tumor risk in congenital central hypoventilation syndrome. *Am J Hum Genet* 2005;76(3):421–6.
- [12] Brodeur GM. Neuroblastoma: biological insights into a clinical enigma. *Nat Rev Cancer* 2003;3(3):203–16.
- [13] Trochet D, Bourdeaut F, Janoueix-Lerosey I, et al. Germline mutations of the paired-like homeobox 2B (PHOX2B) gene in neuroblastoma. *Am J Hum Genet* 2004;74(4):761–4.
- [14] van Limpt V, Schramm A, van Lakeman A, et al. The Phox2B homeobox gene is mutated in sporadic neuroblastomas. *Oncogene* 2004;23(57):9280–8.
- [15] Longo L, Panza E, Skena F, et al. Genetic predisposition to familial neuroblastoma: identification of two novel genomic regions at 2p and 12p. *Hum Hered* 2007;63(3–4):205–11.
- [16] Tonini GP, McConville C, Cusano R, et al. Exclusion of candidate genes and chromosomal regions in familial neuroblastoma. *Int J Mol Med* 2001;7(1):85–9.
- [17] Maris JM, Kyemba SM, Rebbeck TR, et al. Familial predisposition to neuroblastoma does not map to chromosome band 1p36. *Cancer Res* 1996;56(15):3421–5.
- [18] Maris JM, Weiss MJ, Mosse Y, et al. Evidence for a hereditary neuroblastoma predisposition locus at chromosome 16p12-13. *Cancer Res* 2002;62(22):6651–8.
- [19] Triche TJ. Neuroblastoma: biology confronts nosology. *Arch Pathol Lab Med* 1986;110(11):994–6.
- [20] Mosse YP, Laudenslager M, Khazi D, et al. Germline PHOX2B mutation in hereditary neuroblastoma. *Am J Hum Genet* 2004;75(4):727–30.
- [21] O'Brien CA, Pollett A, Gallinger S, et al. A human colon cancer cell capable of initiating tumour growth in immunodeficient mice. *Nature* 2007;445(7123):106–10.
- [22] Singh SK, Hawkins C, Clarke ID, et al. Identification of human brain tumour initiating cells. *Nature* 2004;432(7015):396–401.
- [23] Tirode F, Laud-Duval K, Prieur A, et al. Mesenchymal stem cell features of Ewing tumors. *Cancer Cell* 2007;11(5):421–9.
- [24] Allenspach EJ, Maillard I, Aster JC, et al. Notch signaling in cancer. *Cancer Biol Ther* 2002;1(5):466–76.
- [25] Blanc E, Goldschneider D, Douc-Rasy S, et al. Wnt-5a gene expression in malignant human neuroblasts. *Cancer Letters* 2005;228(1–2):117–23.
- [26] Taipale J, Beachy PA. The Hedgehog and Wnt signalling pathways in cancer. *Nature* 2001;411(6835):349–54.

- [27] Russell D, Rubinstein L. Pathology of tumours of the nervous system. London: Edward Arnold; 1989.
- [28] Beckwith J, Perrin E. In situ neuroblastomas: a contribution to the natural history of neural crest tumors. *Am J Pathol* 1963;43:1089–104.
- [29] Shimada H, Ambros IM, Dehner LP, et al. The International Neuroblastoma Pathology Classification (the Shimada system). *Cancer* 1999;86(2):364–72.
- [30] Shimada H, Chatten J, Newton W Jr, et al. Histopathologic prognostic factors in neuroblastic tumors: definition of subtypes of ganglioneuroblastoma and an age-linked classification of neuroblastomas. *J Natl Cancer Inst* 1984;73:405–16.
- [31] Peuchmaur M, d'Amore ES, Joshi VV, et al. Revision of the international neuroblastoma pathology classification: confirmation of favorable and unfavorable prognostic subsets in ganglioneuroblastoma, nodular. *Cancer* 2003;98(10):2274–81.
- [32] de Bernardi B, Rogers D, Carli M, et al. Localized neuroblastoma: surgical and pathologic staging. *Cancer* 1987;60(5):1066–72.
- [33] Haas-Kogan DA, Swift PS, Selch M, et al. Impact of radiotherapy for high-risk neuroblastoma: a Children's Cancer Group study. *Int J Radiat Oncol Biol Phys* 2003;56(1):28–39.
- [34] Evans AE, Chatten J, D'Angio GJ, et al. A review of 17 IV-S neuroblastoma patients at the Children's Hospital of Philadelphia. *Cancer* 1980;45(5):833–9.
- [35] Brodeur GM, Pritchard J, Berthold F, et al. Revisions of the international criteria for neuroblastoma diagnosis, staging, and response to treatment. *J Clin Oncol* 1993;11(8):1466–77.
- [36] Brodeur GM, Seeger RC, Barrett A, et al. International criteria for diagnosis, staging, and response to treatment in patients with neuroblastoma. *J Clin Oncol* 1988;6(12):1874–81.
- [37] Messina JA, Cheng SC, Franc BL, et al. Evaluation of semi-quantitative scoring system for metaiodobenzylguanidine (mIBG) scans in patients with relapsed neuroblastoma. *Pediatr Blood Cancer* 2006;47(7):865–74.
- [38] Castleberry RP, Shuster JJ, Smith EI. The pediatric oncology group experience with the international staging system criteria for neuroblastoma. Member Institutions of the Pediatric Oncology Group. *J Clin Oncol* 1994;12(11):2378–81.
- [39] Haase GM, Atkinson JB, Stram DO, et al. Surgical management and outcome of locoregional neuroblastoma: comparison of the Children's Cancer Group and the international staging systems. *J Pediatr Surg* 1995;30(2):289–94 [discussion: 295].
- [40] Cecchetto G, Mosseri V, De Bernardi B, et al. Surgical risk factors in primary surgery for localized neuroblastoma: the LNESG1 study of the European International Society of Pediatric Oncology Neuroblastoma Group. *J Clin Oncol* 2005;23(33):8483–9.
- [41] Cohn SL, London W, Monclair T, Matthay KK, Ambros PF, Pearson AD. Update on the development of the international neuroblastoma risk group. Presented at the 43rd Annual Meeting of the American Society of Clinical Oncology. Chicago, June 2–6, 2007.
- [42] Breslow N, McCann B. Statistical estimation of prognosis for children with neuroblastoma. *Cancer Res* 1971;31(12):2098–103.
- [43] Evans AE. Staging and treatment of neuroblastoma. *Cancer* 1980;45(Suppl 7):1799–802.
- [44] London WB, Castleberry RP, Matthay KK, et al. Evidence for an age cutoff greater than 365 days for neuroblastoma risk group stratification in the Children's Oncology Group. *J Clin Oncol* 2005;23(27):6459–65.
- [45] George RE, London WB, Cohn SL, et al. Hyperdiploidy plus nonamplified MYCN confers a favorable prognosis in children 12 to 18 months old with disseminated neuroblastoma: a Pediatric Oncology Group study. *J Clin Oncol* 2005;23(27):6466–73.
- [46] Schmidt ML, Lal A, Seeger RC, et al. Favorable prognosis for patients 12 to 18 months of age with stage 4 nonamplified MYCN neuroblastoma: a Children's Cancer Group Study. *J Clin Oncol* 2005;23(27):6474–80.
- [47] Park J, Villablanca J, Seeger R, et al. Favorable outcome of high risk (HR) stage 3 neuroblastoma (NB) with myeloablative therapy and 13-cis-retinoic acid. Presented at the 41st Annual Meeting of American Society of Oncology. Orlando, Florida, May 13–17, 2005.

- [48] Shimada H, Stram DO, Chatten J, et al. Identification of subsets of neuroblastomas by combined histopathologic and N-myc analysis. *J Natl Cancer Inst* 1995;87(19):1470–6.
- [49] Maris JM. The biologic basis for neuroblastoma heterogeneity and risk stratification. *Curr Opin Pediatr* 2005;17(1):7–13.
- [50] Riley RD, Heney D, Jones DR, et al. A systematic review of molecular and biological tumor markers in neuroblastoma. *Clin Cancer Res* 2004;10(1 Pt 1):4–12.
- [51] Westermann F, Schwab M. Genetic parameters of neuroblastomas. *Cancer Lett* 2002;184(2):127–47.
- [52] Bown N, Cotterill S, Lastowska M, et al. Gain of chromosome arm 17q and adverse outcome in patients with neuroblastoma. *N Engl J Med* 1999;340(25):1954–61.
- [53] Caron H, van Sluis P, de Kraker J, et al. Allelic loss of chromosome 1p as a predictor of unfavorable outcome in patients with neuroblastoma. *N Engl J Med* 1996;334(4):225–30.
- [54] Attiyeh EF, London WB, Mosse YP, et al. Chromosome 1p and 11q deletions and outcome in neuroblastoma. *N Engl J Med* 2005;353(21):2243–53.
- [55] Maris JM, Hogarty MD, Bagatell R, et al. Neuroblastoma. *Lancet* 2007;369(9579):2106–20.
- [56] Nakagawara A, Azar CG, Scavarda NJ, et al. Expression and function of Trk-B and BDNF in human neuroblastomas. *Mol Cell Biol* 1994;14:759–67.
- [57] Nakagawara A, Arima-Nakagawara M, Scavarda NJ, et al. Association between high levels of expression of the Trk gene and favorable outcome in human neuroblastomas. *N Engl J Med* 1993;328:847–54.
- [58] Combaret V, Gross N, Lasset C, et al. Clinical relevance of CD44 cell surface expression and MYCN gene amplification in neuroblastoma. *Eur J Cancer* 1997;33(12):2101–5.
- [59] Borrello MG, Bongarzone I, Pierotti MA, et al. TRK and RET protooncogene expression in human neuroblastoma specimens: high frequency of Trk expression in non-advanced stages. *Int J Cancer* 1993;54:540–5.
- [60] Kogner P, Barbany G, Dominici C, et al. Coexpression of messenger RNA for Trk protooncogene and low affinity nerve growth factor receptor in neuroblastomas with favorable prognosis. *Cancer Res* 1993;53:2044–50.
- [61] Suzuki T, Bogenmann E, Shimada H, et al. Lack of high affinity nerve growth factor receptors in aggressive neuroblastomas. *J Natl Cancer Inst* 1993;85:377–84.
- [62] Aoyama M, Asai K, Shishikura T, et al. Human neuroblastomas with unfavorable biologies express high levels of brain-derived neurotrophic factor mRNA and a variety of its variants. *Cancer Lett* 2001;164(1):51–60.
- [63] Eggert A, Grotzer MA, Ikegaki N, et al. Expression of the neurotrophin receptor TrkA down-regulates expression and function of angiogenic stimulators in SH-SY5Y neuroblastoma cells. *Cancer Res* 2002;62(6):1802–8.
- [64] Eggert A, Ikegaki N, Kwiatkowski J, et al. High-level expression of angiogenic factors is associated with advanced tumor stage in human neuroblastomas. *Clin Cancer Res* 2000;6:1900–8.
- [65] van Limpt V, Chan A, Schramm A, et al. Phox2B mutations and the Delta-Notch pathway in neuroblastoma. *Cancer Lett* 2005;228(1–2):59–63.
- [66] Ho R, Eggert A, Hishiki T, et al. Resistance to chemotherapy mediated by TrkB in neuroblastomas. *Cancer Res* 2002;62(22):6462–6.
- [67] Barbacid M. The trk family of neurotrophin receptors. *J Neurobiol* 1994;25:1386–403.
- [68] Biffo S, Offenhauser N, Carter BD, et al. Selective binding and internalisation by truncated receptors restrict the availability of BDNF during development. *Development* 1995;121(8):2461–70.
- [69] Eide FF, Vining ER, Eide BL, et al. Naturally occurring truncated trkB receptors have dominant inhibitory effects on brain-derived neurotrophic factor signaling. *J Neurosci* 1996;16(10):3123–9.

- [70] Haapasalo A, Koponen E, Hoppe E, et al. Truncated trkB.T1 is dominant negative inhibitor of trkB.TK+-mediated cell survival. *Biochem Biophys Res Commun* 2001;280(5):1352–8.
- [71] Brodeur GM, Nakagawara A, Yamashiro D, et al. Expression of TrkA, TrkB and TrkC in human neuroblastomas. *J Neurooncol* 1997;31:49–55.
- [72] Tacconelli A, Farina AR, Cappabianca L, et al. TrkA alternative splicing: a regulated tumor-promoting switch in human neuroblastoma. *Cancer Cell* 2004;6(4):347–60.
- [73] Castle VP, Heidelberger KP, Bromberg J, et al. Expression of the apoptosis-suppressing protein bcl-2, in neuroblastoma is associated with unfavorable histology and N-myc amplification. *Am J Pathol* 1993;143(6):1543–50.
- [74] Eggert A, Grotzer MA, Zuzak TJ, et al. Resistance to tumor necrosis factor-related apoptosis-inducing ligand (TRAIL)-induced apoptosis in neuroblastoma cells correlates with a loss of caspase-8 expression. *Cancer Res* 2001;61(4):1314–9.
- [75] Hopkins-Donaldson S, Bodmer JL, Bourlout KB, et al. Loss of caspase-8 expression in highly malignant human neuroblastoma cells correlates with resistance to tumor necrosis factor-related apoptosis-inducing ligand-induced apoptosis. *Cancer Res* 2000;60(16):4315–9.
- [76] Teitz T, Wei T, Valentine MB, et al. Caspase 8 is deleted or silenced preferentially in childhood neuroblastomas with amplification of MYCN. *Nat Med* 2000;6(5):529–35.
- [77] van Noesel MM, van Bezouw S, Salomons GS, et al. Tumor-specific down-regulation of the tumor necrosis factor-related apoptosis-inducing ligand decoy receptors DcR1 and DcR2 is associated with dense promoter hypermethylation. *Cancer Res* 2002;62(7):2157–61.
- [78] Chan HS, Haddad G, Thorner PS, et al. P-glycoprotein expression as a predictor of the outcome of therapy for neuroblastoma. *N Engl J Med* 1991;325(23):1608–14.
- [79] Goldstein LJ, Fojo AT, Ueda K, et al. Expression of the multidrug resistance, MDR1, gene in neuroblastomas. *J Clin Oncol* 1990;8(1):128–36.
- [80] Haber M, Smith J, Bordow SB, et al. Association of high-level MRP1 expression with poor clinical outcome in a large prospective study of primary neuroblastoma. *J Clin Oncol* 2006;24(10):1546–53.
- [81] Norris MD, Bordow SB, Marshall GM, et al. Expression of the gene for multidrug-resistance-associated protein and outcome in patients with neuroblastoma. *N Engl J Med* 1996;334(4):231–8.
- [82] Jaboin J, Kim CJ, Kaplan DR, et al. Brain-derived neurotrophic factor activation of TrkB protects neuroblastoma cells from chemotherapy-induced apoptosis via phosphatidylinositol 3'-kinase pathway. *Cancer Res* 2002;62(22):6756–63.
- [83] Scala S, Wosikowski K, Giannakakou P, et al. Brain-derived neurotrophic factor protects neuroblastoma cells from vinblastine toxicity. *Cancer Res* 1996;56:3737–42.
- [84] Meitar D, Crawford SE, Rademaker AW, et al. Tumor angiogenesis correlates with metastatic disease, N-myc amplification, and poor outcome in human neuroblastoma. *J Clin Oncol* 1996;14:405–14.
- [85] Almgren MA, Henriksson KC, Fujimoto J, et al. Nucleoside diphosphate kinase A/nm23-H1 promotes metastasis of NB69-derived human neuroblastoma. *Mol Cancer Res* 2004;2(7):387–94.
- [86] Chantrain CF, Shimada H, Jodele S, et al. Stromal matrix metalloproteinase-9 regulates the vascular architecture in neuroblastoma by promoting pericyte recruitment. *Cancer Res* 2004;64(5):1675–86.
- [87] Gross N, Balmas Bourlout K, Brognara CB. MYCN-related suppression of functional CD44 expression enhances tumorigenic properties of human neuroblastoma cells. *Exp Cell Res* 2000;260(2):396–403.
- [88] Jodele S, Chantrain CF, Blavier L, et al. The contribution of bone marrow-derived cells to the tumor vasculature in neuroblastoma is matrix metalloproteinase-9 dependent. *Cancer Res* 2005;65(8):3200–8.

- [89] Alvarado CS, London WB, Look AT, et al. Natural history and biology of stage A neuroblastoma: a Pediatric Oncology Group Study. *J Pediatr Hematol Oncol* 2000;22(3):197–205.
- [90] Perez CA, Matthay KK, Atkinson JB, et al. Biologic variables in the outcome of stages I and II neuroblastoma treated with surgery as primary therapy: a children's cancer group study. *J Clin Oncol* 2000;18(1):18–26.
- [91] Simon T, Spitz R, Faldum A, et al. New definition of low-risk neuroblastoma using stage, age, and 1p and MYCN status. *J Pediatr Hematol Oncol* 2004;26(12):791–6.
- [92] Simon T, Spitz R, Hero B, et al. Risk estimation in localized unresectable single copy MYCN neuroblastoma by the status of chromosomes 1p and 11q. *Cancer Lett* 2006;237(2):215–22.
- [93] Strother DR, London W, Schmidt ML, et al. Surgery alone or followed by chemotherapy for patients with stages 2A and 2B neuroblastoma: results of Children's Oncology Group Study P9641. Presented at the 12th meeting of Advances in Neuroblastoma Research. Los Angeles, May 18–20, 2006.
- [94] D'Angio GJ, Evans AE, Koop CE. Special pattern of widespread neuroblastoma with a favourable prognosis. *Lancet* 1971;1(7708):1046–9.
- [95] Nickerson HJ, Matthay KK, Seeger RC, et al. Favorable biology and outcome of stage IV-S neuroblastoma with supportive care or minimal therapy: a Children's Cancer Group study. *J Clin Oncol* 2000;18(3):477–86.
- [96] Katzenstein HM, Bowman LC, Brodeur GM, et al. Prognostic significance of age, MYCN oncogene amplification, tumor cell ploidy, and histology in 110 infants with stage D(S) neuroblastoma: the pediatric oncology group experience—a pediatric oncology group study. *J Clin Oncol* 1998;16(6):2007–17.
- [97] Matthay KK, Perez C, Seeger RC, et al. Successful treatment of stage III neuroblastoma based on prospective biologic staging: a Children's Cancer Group study. *J Clin Oncol* 1998;16(4):1256–64.
- [98] Schmidt ML, Lukens JN, Seeger RC, et al. Biologic factors determine prognosis in infants with stage IV neuroblastoma: a prospective Children's Cancer Group study. *J Clin Oncol* Mar 2000;18(6):1260–8.
- [99] Baker DL, Schmidt ML, Cohn SL, et al. A phase III trial of biologically-based therapy reduction for intermediate risk neuroblastoma. Presented at the 43rd Annual meeting of the American Society of Clinical Oncology. Chicago, June 2–6, 2007.
- [100] Kushner BH, Cheung NK, LaQuaglia MP, et al. Survival from locally invasive or widespread neuroblastoma without cytotoxic therapy. *J Clin Oncol* 1996;14(2):373–81.
- [101] Hero B, Thorsten S, Benz-Bohm G, et al. Is a “wait and see” strategy justified in localised neuroblastoma in infancy? Presented at the 12th meeting of Advances in Neuroblastoma Research. Los Angeles, May 18–20, 2006.
- [102] Matthay KK, Villablanca JG, Seeger RC, et al. Treatment of high-risk neuroblastoma with intensive chemotherapy, radiotherapy, autologous bone marrow transplantation, and 13-cis-retinoic acid. Children's Cancer Group. *N Engl J Med* 1999;341(16):1165–73.
- [103] Kushner BH, LaQuaglia MP, Bonilla MA, et al. Highly effective induction therapy for stage 4 neuroblastoma in children over 1 year of age. *J Clin Oncol* 1994;12(12):2607–13.
- [104] Valteau-Couanet D, Michon J, Boneu A, et al. Results of induction chemotherapy in children older than 1 year with a stage 4 neuroblastoma treated with the NB 97 French Society of Pediatric Oncology (SFOP) protocol. *J Clin Oncol* 2005;23(3):532–40.
- [105] Kreissman SG, Villablanca JG, Diller L, et al. Response and toxicity to a dose-intensive multi-agent chemotherapy induction regimen for high risk neuroblastoma: a Children's Oncology Group study. Presented at the 43rd Annual meeting of the American Society of Clinical Oncology. Chicago, June 2–6, 2007.
- [106] Frantz CN, London WB, Diller L, et al. Recurrent neuroblastoma: randomized treatment with topotecan + cyclophosphamide (T + C) vs. topotecan alone(T). A POG/CCG Inter-group Study. *J Clin Oncol* 2004;22(14S):8512.

- [107] Park JR, Stewart CF, London W, et al. Targeted topotecan during induction therapy of high risk neuroblastoma : A Children's Oncology Group pilot study. Presented at the 42nd annual meeting of the American Society of Clinical Oncology. Atlanta, Georgia, June 2–6, 2006.
- [108] Adkins ES, Sawin R, Gerbing RB, et al. Efficacy of complete resection for high-risk neuroblastoma: a Children's Cancer Group study. *J Pediatr Surg* 2004;39(6):931–6.
- [109] Brodeur GM, Maris JM. Neuroblastoma. 4th edition. Philadelphia: Lippincott; 2002.
- [110] Kushner BH, Wolden S, LaQuaglia MP, et al. Hyperfractionated low-dose radiotherapy for high-risk neuroblastoma after intensive chemotherapy and surgery. *J Clin Oncol* 2001;19(11):2821–8.
- [111] Bradfield SM, Douglas JG, Hawkins DS, et al. Fractionated low-dose radiotherapy after myeloablative stem cell transplantation for local control in patients with high-risk neuroblastoma. *Cancer* 2004;100(6):1268–75.
- [112] Simon T, Bongartz R, Hero B, et al. Intensified external beam radiation therapy improves the outcome of stage 4 neuroblastoma in children > 1 year with residual local disease [abstract: 314]. *Advances in Neuroblastoma Research* 2006.
- [113] Berthold F, Boos J, Burdach S, et al. Myeloablative megatherapy with autologous stem-cell rescue versus oral maintenance chemotherapy as consolidation treatment in patients with high-risk neuroblastoma: a randomised controlled trial. *Lancet Oncol* 2005;6(9):649–58.
- [114] Pritchard J, Cotterill SJ, Germond SM, et al. High dose melphalan in the treatment of advanced neuroblastoma: results of a randomised trial (ENSG-1) by the European Neuroblastoma Study Group. *Pediatr Blood Cancer* 2005;44(4):348–57.
- [115] George RE, Li S, Medeiros-Nancarrow C, et al. High-risk neuroblastoma treated with tandem autologous peripheral-blood stem cell-supported transplantation: long-term survival update. *J Clin Oncol* 2006;24(18):2891–6.
- [116] Albertini MR, Gan J, Jaeger P, et al. Systemic interleukin-2 modulates the anti-idiotypic response to chimeric anti-GD2 antibody in patients with melanoma. *J Immunother Emphasis Tumor Immunol* 1996;19(4):278–95.
- [117] Hank JA, Surfus J, Gan J, et al. Treatment of neuroblastoma patients with antiganglioside GD2 antibody plus interleukin-2 induces antibody-dependent cellular cytotoxicity against neuroblastoma detected in vitro. *J Immunother* 1994;15(1):29–37.
- [118] Roberts KB. Cerebellar ataxia and “occult neuroblastoma” without opsoclonus. *Pediatrics* 1975;56(3):464–5.
- [119] Altman AJ, Baehner RL. Favorable prognosis for survival in children with coincident opso-myoclonus and neuroblastoma. *Cancer* 1976;37(2):846–52.
- [120] Matthay KK, Blaes F, Hero B, et al. Opsoclonus myoclonus syndrome in neuroblastoma: a report from a workshop on the dancing eyes syndrome at the advances in neuroblastoma meeting in Genoa, Italy. *Cancer Lett* 2005;228(1–2):275–82.
- [121] Scheibel E, Rechnitzer C, Fahrenkrug J, et al. Vasoactive intestinal polypeptide (VIP) in children with neural crest tumours. *Acta Paediatr Scand* 1982;71(5):721–5.
- [122] El Shafie M, Samuel D, Klippel CH, et al. Intractable diarrhea in children with VIP-secreting ganglioneuroblastomas. *J Pediatr Surg* 1983;18(1):34–6.