

Developmental Dysplasia of the Hip

Blaise A. Nemeth, MD, MS,*
Vinay Narotam, MD[†]

Author Disclosure
Drs Nemeth and Narotam have disclosed no financial relationships relevant to this article. This commentary does not contain a discussion of an unapproved/investigative use of a commercial product/device.

Educational Gap

Early detection of developmental dysplasia of the hip is essential because restoration of the normal relationship of the femoral head and acetabulum increases the likelihood of normal development. Pediatricians must be aware of the American Academy of Pediatrics guidelines for early detection.

Objectives

After completing this article, readers should be able to:

1. Acknowledge the spectrum of hip pathology included in developmental dysplasia of the hip (DDH).
2. Identify newborns at risk for DDH.
3. Diagnose hip dislocations by using appropriate physical examination maneuvers.
4. Appropriately use imaging modalities to screen for DDH in infants who have normal or equivocal physical findings.
5. Recognize the presentation of hip dislocation in the older child.

Definition

Developmental dysplasia of the hip (DDH) encompasses the spectrum of hip abnormalities involving the relationship between the femoral head and the acetabulum during early growth and development. A hip may be dislocated at rest, dislocatable (but in a normal position at rest), subluxed (incomplete contact between the femoral head and acetabulum), subluxable (incomplete contact induced with provocative maneuvers), or appear normal on physical examination yet have an abnormally shaped acetabulum or femoral head radiographically. The previously used term, “congenital hip dislocation,” has been abandoned in recognition of this spectrum, acknowledging as well the fact that a child may have normal examination findings at birth but progress to dislocation later in life.

Strictly speaking, the term DDH does not apply to abnormal development of the hip due to other diseases, such as cerebral palsy, Legg-Calvé-Perthes disease, or slipped capital femoral epiphysis, in which “hip dysplasia” is a sufficient term, nor does the term include traumatic dislocation. In addition, the term “teratologic dislocation” is reserved for cases of hip dislocation present at birth related to neurologic disease or joint contracture syndromes such as spina bifida, arthrogryposis, or Larsen syndrome.

Epidemiology

DDH occurs in approximately 1 per 100 live births, whereas dislocation at birth is present in approximately 1 per 1,000 infants; the native Alaskan population experiences a rate 25 to 50 times higher.

A number of risk factors for DDH have been reported, but three primary factors have been supported consistently in the literature (Table). Being female presents the greatest risk for DDH, an association thought to be due to increased sensitivity to maternal estrogen and relaxin, yielding increased joint laxity and abnormal motion during fetal development. Breech

Abbreviations

AVN: avascular necrosis
DDH: developmental dysplasia of the hip

*Associate Professor, Department of Orthopedics and Rehabilitation, University of Wisconsin School of Medicine and Public Health, Madison, WI.

[†]Assistant Professor, Department of Orthopaedics, University of North Carolina School of Medicine, Chapel Hill, NC.

Table. Risk of Developmental Dysplasia of the Hip

Newborn Characteristic	Risk of a Positive Examination per 1,000 Newborns
All newborns	11.5
Boys	4.1
Girls	19.0
Positive family history	
Boys	9.4
Girls	44.0
Breech presentation	
Boys	26.0
Girls	120.0

From Goldberg MJ. Early detection of developmental hip dysplasia: synopsis of the AAP clinical practice guideline. *Pediatr Rev.* 2001;22(4):132.

position during the last trimester presents a similar risk, whereas genetic factors (often identified through family history) also play a role. Multiple reports have associated DDH with examination findings suggestive of a restricted intrauterine environment, such as torticollis, metatarsus adductus, and calcaneovalgus foot. (1)(2) Because many of these reports are from tertiary care centers, the applicability of these factors to primary care is unclear, but they may be considerations when assessing overall risk.

Pathogenesis

The acetabulum and femoral head evolve from the same mesenchymal tissue during the first trimester; but formation of a concentric hip joint relies on contact between the femoral head and acetabulum during growth. As a result, factors beyond genetics that disrupt joint motion or position may result in abnormal development. This disruption may occur in utero, as with breech positioning or female gender, as well as after birth. One area of concern is infant positioning, either with swaddling or placing children on a papoose board with the hips extended. Instead, infants should be swaddled with the legs left free or the hips in a flexed and abducted position.

Early detection is essential because restoration of the normal relationship between the femoral head and acetabulum increases the likelihood of normal development during remaining growth. Dislocated hips that remain dislocated carry a poor prognosis, as do unstable hips, which may progress to acetabular dysplasia or subsequent dislocation. An unfavorable outcome is especially noteworthy in regard to premature infants, whose hips may be overlooked amid other health issues resulting in a late presentation. (3)

Teratologic dislocations are thought to occur early in fetal development, during the second trimester. In such cases, the normal relationship between the acetabulum and femoral head occurs only briefly, if at all, resulting in significant disruption of normal joint architecture. Treatment requires surgical reduction, although the decision to do so is made by the orthopedic surgeon based on the underlying cause and the risk/benefit ratio for the individual child.

Clinical Aspects

Many cases of DDH are identified on physical examination of the newborn at or shortly after birth. With the infant lying supine on a firm surface, such as an examination table, and the hips and knees flexed 90 degrees, a unilateral dislocated hip usually demonstrates a positive Galeazzi sign, that is, the knee on the side of the dislocated hip appears lower than that of the other side (Fig 1). Some unstable hips may have a negative Galeazzi sign, so provocative maneuvers should always be performed.

Thigh or gluteal creases may be asymmetric, although this finding occurs commonly in children without hip dislocation or subluxation and should be interpreted in the context of the rest of the examination. Hip abduction in the frog-leg position may demonstrate painless, limited motion in a dislocated hip (Fig 2). If a neonate has painful, limited abduction, with or without dislocation, a septic hip should be suspected, and the child referred emergently for orthopedic evaluation. Normal abduction in the frog-leg position should be at least 60 degrees from midline, with 80 degrees attainable by most newborns. Decreased abduction in both hips raises concern for bilateral dislocations.

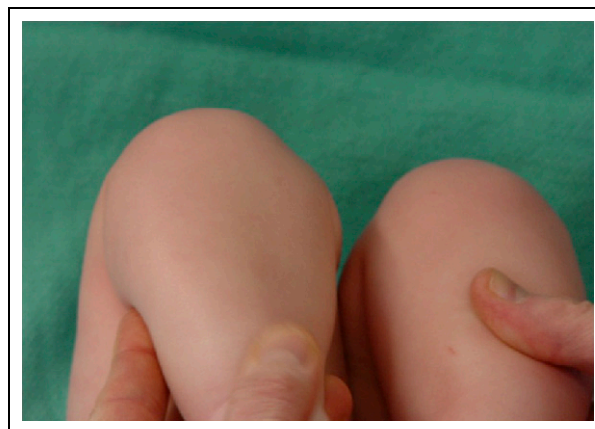


Figure 1. Positive Galeazzi sign. The left knee is lower when the hips and knees are both flexed 90 degrees in this infant, suggesting a dislocated or subluxed hip.

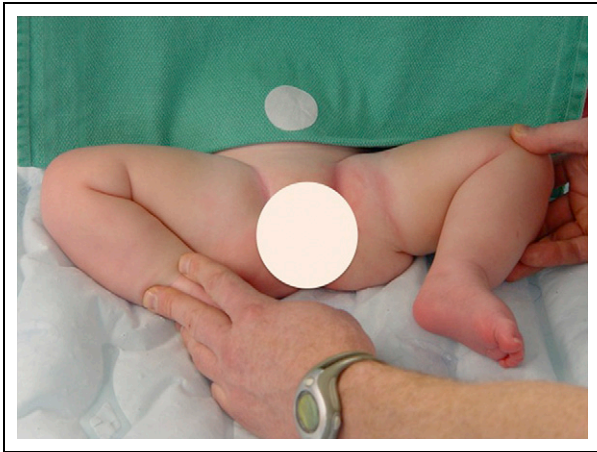


Figure 2. Abduction is limited even while this infant (same as Fig 1) is sedated in preparation for closed reduction of a dislocated hip.

The most important part of the evaluation of the hip includes the dynamic Ortolani and Barlow maneuvers, which allow for differentiation of asymmetric thigh creases not associated with DDH, identification of instability, and detection of bilateral hip dislocations associated with a symmetric static exam. The child should be placed supine on a firm surface and the hips should be examined one at a time, stabilizing the contralateral hip to prevent falsely positive or negative findings due to rocking of the pelvis. The child should be relaxed, because muscle contractures may reduce or stabilize an unstable hip and result in a falsely negative examination.

These are not forceful maneuvers but typically are performed easily in a relaxed child just through pronation and supination of the forearm without any contribution from the rest of the examiner's arm; likewise, the examiner should not be "white knuckled." Having the baby suck from a bottle or on a finger, or examination shortly after breastfeeding, frequently results in a relaxed examination.

The Ortolani test detects dislocated hips that are reducible. From the resting position with hips flexed 90 degrees, the thigh is abducted and the examiner lifts anteriorly over the greater trochanter with the ring or middle finger. A positive test will elicit the "clunk" of relocation, and the clunks will be experienced once again as the thigh is adducted and the hip redislocates. The term clunk has more recently been promoted as the identifying sensation in a dislocated hip and occurs as the femoral head rides over the posterior rim of the acetabulum and either drops into a reduced position within the acetabulum or redislocates. (4)

Children commonly demonstrate "clicks" during provocative maneuvers in the first few months after birth. Much confusion exists over the significance of these subtle, superficial, high-pitched "adventitious clicks" at the hips, which similarly may occur in the knees or shoulders. In contrast to clicks, clunks are a deeper and more prominent sensation; occasionally the relocation is dramatic enough to be visualized by onlookers (Fig 3). Clicks are thought to be due to the snapping of soft tissue structures over bony prominences.

The confusion in terminology may stem from Ortolani's initial description in Italian that was literally translated as click, as well as the continued use of click in the European literature. Adventitious clicks in the first few months after birth have not been found to be associated with DDH and do not require further imaging or orthopedic consultation. (5)

The Barlow test identifies a hip that is located at rest but unstable, that is, the Ortolani maneuver is negative. Most examiners use a slight modification to Barlow's original maneuver, whereby the thigh is adducted slightly past midline and pushed posteriorly (toward the table); the femoral head will then "spring back in again as soon as the pressure is released." (6) Although many infants will have slight laxity on examination, identifying truly increased motion that defines instability requires proficiency gained through experience examining normal and abnormal hips.

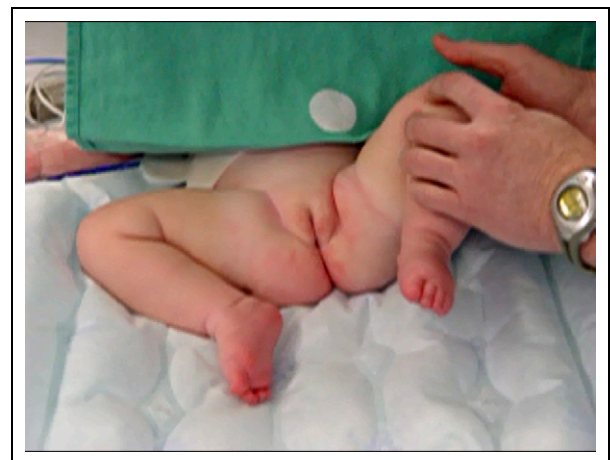

Figure 3. (Click here for video.) A positive Ortolani maneuver is seen in this patient (same as Figs 1 and 2). The clunk of relocation is dramatic. This finding is seen easily because this patient is sedated, reinforcing the importance of a relaxed child, but a palpable clunk was obvious also on clinical examination when the patient was awake.

Indeterminate or uncertain examinations warrant examination by an orthopedist or radiographic imaging (see Screening below). Although most abnormal hips are identifiable on Ortolani or Barlow maneuvers, a few may have apparently normal findings on examination and be missed clinically. Similarly, stable hips that have acetabular dysplasia by definition have normal findings on examination and require radiographic imaging to make the diagnosis.

The presentation of DDH in children older than 4 months differs in a number of regards. Late dislocations present frequently with an abnormal gait. Children who have unilateral dislocations may appear to have a leg length discrepancy on the dislocated side, walking on their tip-toes (Fig 4). Children who have bilateral dislocations will have an abnormal, yet symmetric, gait (somewhat waddling with hyperlordosis of the lower back). The Ortolani maneuver rarely is positive in late dislocations, but abduction of a dislocated hip usually is limited and a positive Galeazzi sign is seen; in cases of bilateral dislocations, the Galeazzi maneuver appears negative (ie, both knees are at the same level) because of the symmetric, albeit abnormal, position of femoral heads relative to the acetabulae. Late presentations of radiographic dysplasia in childhood are unusual. The first manifestation is usually pain, with these patients presenting in late adolescence or young adulthood once pain occurs.

Screening

Screening is recommended by the American Academy of Pediatrics (AAP) in an effort to decrease the frequency of late-presenting dislocations (7); but the indications and

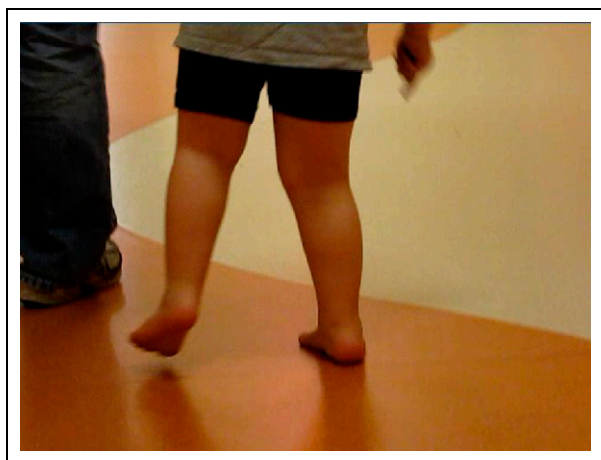

Figure 4. (Click here for video.) Gait of patient from Fig 9 demonstrates walking on the toes of the left leg. The findings on physical examination and radiographs were consistent with late-presenting DDH with dislocation.

utility of screening are a source of confusion and controversy. The physical examination is the most important and cost-effective screening method for DDH and should be performed in every newborn. Children who have normal findings should continue to have their hips examined at each of the recommended health supervision visits until a normal gait is demonstrated. Radiographic imaging augments the physical examination for those who have equivocal findings (asymmetric thigh or gluteal folds, limited abduction, persistent laxity without a clunk, or uncertainty regarding adventitious clicks at the 2-week visit), as well as healthy infants who exceed a threshold of concern for DDH based on risk factors, primarily females with a history of breech presentation in the newborn period. (7)

Ultrasonography with the use of static and dynamic assessments and performed after 3 weeks after birth is the AAP-preferred imaging method (7) (more recently, the American College of Radiology endorsed any time ≥ 2 weeks of age). (8) Ultrasonography performed earlier can lead to a high rate of false-positives (Fig 5), usually due to laxity that will resolve spontaneously; so the AAP recommendation of “3 to 4 weeks of age” remains consistent with that of the American College of Radiology. Being highly operator-dependent, ultrasonography is best performed by experienced personnel. Ultrasonography is not necessary for infants with positive Ortolani or Barlow maneuvers because findings or imaging will not change the need for an orthopedic consultation.

Ultrasonographic evaluation loses utility between age 4 and 6 months because of the ossification of the femoral head. Plain radiographs consisting of anterior-posterior and frog views of the pelvis showing both hips then become the preferred imaging modality when DDH is suspected in older infants and children (Fig 6). (8) Likewise, acetabular dysplasia is identified best on radiographs after age 6 months and should be considered in any child who has a history of breech presentation because acetabular dysplasia may occur in the presence of normal ultrasonography results at age 4 to 6 weeks. (9)

In 2006, the US Preventive Services Task Force performed a systematic review, with the conclusion that, because of “the high rate of spontaneous resolution of neonatal hip instability and dysplasia and the lack of evidence of the effectiveness of intervention on functional outcomes, the net benefits of screening are not clear.” (10) Concern was raised that treatment of DDH, either surgically or nonsurgically, carried a risk for the development of avascular necrosis (AVN), and that the quality of the existing data was not sufficient to determine the effectiveness of treatment.

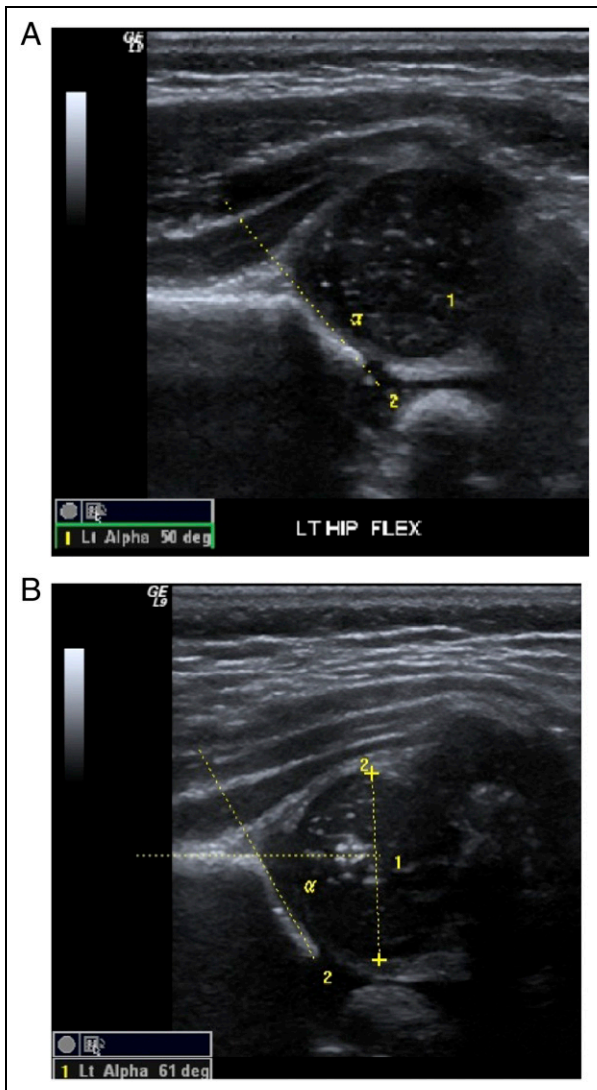


Figure 5. Ultrasonographic findings in a female born by cesarean delivery for breech presentation, who had normal findings on physical examination. A. Ultrasonography inappropriately obtained before discharge after birth demonstrates a femoral head (speckled circle) less than 50% covered relative to the edge of the bony acetabulum (dashed line) and an α -angle of 50 degrees. No instability was noted on dynamic ultrasonographic evaluation, but the infant was sent for orthopedic consultation because of "DDH." B. Without treatment, findings on ultrasonography were normal 3 weeks later.

This declaration was met with a response from the Pediatric Orthopaedic Society of North America acknowledging the lack of high-quality studies to guide clinical recommendations, but voicing concern that the tone of the US Preventive Services Task Force statement would

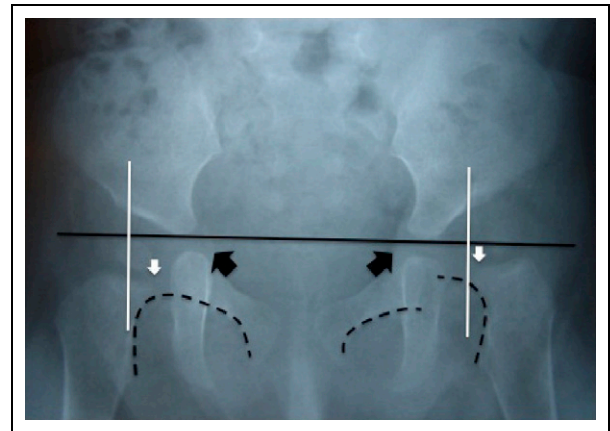


Figure 6. Radiograph of a patient presenting at age 8 months with DDH. The left hip is dislocated. Drawing a Hilgenreiner line (black) through the triradiate cartilage (black arrow) of both hips, and a Perkins line (white) perpendicular to the Hilgenreiner line at the lateral edge of the acetabulum, creates four quadrants. The medial metaphysis (white arrow) of the femur should sit within the inferomedial quadrant, as it does on the right. The position in the inferolateral quadrant on the left is consistent with dislocation. In addition, a Shenton line, drawn along the inferior edge of the femoral neck and pubic ramus, should form a contiguous arc, as on the right, but is disrupted on the left.

deter screening. (11) Because the risk of AVN occurs primarily in cases of late DDH treated surgically, screening is the preferred approach. As a result, the Pediatric Orthopaedic Society of North America promoted the model-driven method used in the AAP guidelines and reinforced the guidelines with a few additional clarifications. Clinical examination is the current standard of care and the best method of screening for instability. Ultrasonography or radiography at age 4 to 5 months is useful for infants who have uncertain findings or who have a high risk of having DDH. Pavlik harnessing was promoted as the safest and most effective treatment for early-detected DDH, clarifying that the risk of AVN occurs primarily in children being treated for DDH who present late (a number that would be expected to increase if screening were not performed).

A recent Cochrane review reiterated that there is insufficient evidence to guide clinical practice. The evidence that screening increased treatment was mixed, and studies were not powerful enough to identify differences in infrequent outcomes; however, ultrasonography and targeted treatment, although not definitively decreasing the rate of late DDH, did not increase the incidence or lead to more surgery. (12) At this time, the AAP guidelines remain the best resource regarding a clinical

approach to the diagnosis and management of DDH for primary care physicians.

Although screening ultrasonography in neonates is recommended to prevent late presentation of DDH, that is, dislocation, through the identification of instability on dynamic evaluation, radiologists may comment on dysplasia, as measured by the α -angle or femoral head coverage (as in Fig 5A). Because most cases will improve spontaneously, treatment is reserved for severe or persistent dysplasia on subsequent ultrasonography or plain radiographs. Pavlik harnesses typically are reserved for children younger than age 6 months, whereas a rigid hip abduction brace is used for older children. Treatment usually involves nighttime wear, although full-time use may be recommended in some cases. Determination of the significance of dysplasia identified by ultrasonography or plain radiograph should be performed by a consulting orthopedist, so referral in these cases is appropriate (Fig 7).

Management

Infants (newborn to 2 weeks old) who have a positive finding on an Ortolani or Barlow examination should be referred urgently (within 1–2 weeks) to an orthopedist comfortable with the management of DDH. Infants age 2 weeks who have equivocal findings may undergo ultrasonography or be evaluated by an orthopedist to confirm whether or not a dislocated hip is present.

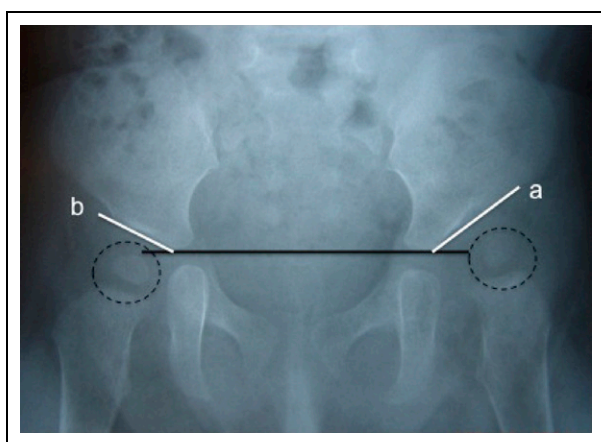


Figure 7. Same patient as Fig 6. Radiographs demonstrate left-sided dysplasia, in addition to the dislocation, as would be expected. The acetabular index, that is, the inclination of the superior portion of the acetabulum, is greater on the left (a), than on the normal right side (b). The ossifying femoral heads (circles) also are asymmetric, smaller on the left than on the right. Similar findings are seen in patients who have hip dysplasia without dislocation.

Initial management of DDH consists of the use of a hip abduction brace, usually a Pavlik harness in infants younger than age 6 months. Brace management protocols vary, but typically involve a period of full-time harness wear followed by nighttime wear. Frequent follow-up visits are necessary to adjust the harness and prevent complications resulting from a harness that is too small, specifically neuropathies and AVN (Fig 8).

Primary care physicians often play a role in initial identification of neuropathies, especially for families living far from the treating orthopedist. Parents are advised to look for symmetric, spontaneous movement of all extremities whenever the harness is removed. If abnormalities are seen, the harness should be left off and the child should be evaluated by the orthopedist shortly thereafter.

Pavlik harness treatment is most successful when initiated within the first 2 months after birth. Early treatment with the Pavlik harness results in reduced and stable hips in more than 95% of all cases of DDH, although complete dislocations are more likely to fail treatment.

Because hips that remain dislocated invariably progress to poor outcomes as early as young adulthood, hips that fail to reduce and stabilize with Pavlik harness treatment require reduction under anesthesia and hip spica casting. Often, only minimal surgical intervention is needed, but more extensive procedures may be necessary to correct any underlying abnormalities that prevent reduction (Fig 9). Traction before surgery seldom is used in the United States in favor of performing additional procedures at the time of reduction, but traction may be part of the treatment protocol in some locales.

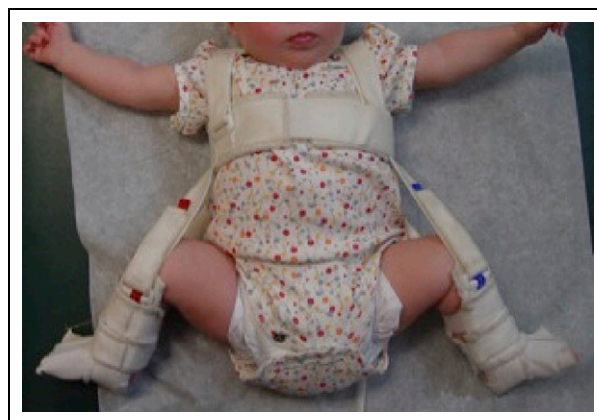

Figure 8. The Pavlik harness holds the hips in flexion, placing the femoral head deeper within the acetabulum and restricts adduction that leads to instability. The chest and shoulder straps anchor the harness, whereas the anterior straps control flexion and the posterior straps limit adduction.

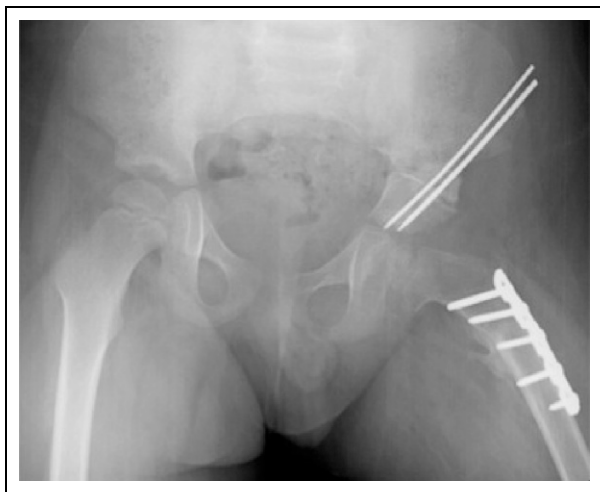

Figure 9. Surgical treatment to correct DDH may involve the acetabulum, femur, and soft tissue releases. This patient, who presented to orthopedics at age 4 years after having been followed elsewhere for presumed idiopathic leg length discrepancy, underwent all three.

Children who present at a later age should be referred within a few weeks to an orthopedic surgeon. Radiographic dysplasia may be addressed with rigid hip abduction bracing in children older than age 6 months, but late-presenting dislocations require surgical reduction, just as with teratologic dislocations.

Patients who have unresolved radiographic dysplasia or residual dysplasia, after operative or nonoperative treatment, benefit from additional surgical procedures to improve the relationship between the acetabulum and femoral head before skeletal maturity. Numerous procedures may be used, depending on the age of the patient and the configuration of the acetabulum and femoral head.

Prognosis

Early identification and treatment of unstable hips with a Pavlik harness generates the best outcomes. The complications of Pavlik harness treatment, AVN and nerve palsies, are rare and are best prevented with close monitoring during treatment.

Approximately 1% of patients have residual dysplasia requiring surgery during the first 5 years after birth, (13) and, despite normal radiographic findings at age 4 to 5 years, 10% to 15% may demonstrate dysplasia on radiographs obtained during adolescence. As a result, patients should be followed through skeletal maturity with periodic radiographic surveillance, usually by the treating orthopedist. Patients in whom Pavlik treatment

fails, or who present later in age, and who undergo closed or open reduction of their hips frequently require additional surgery before skeletal maturity, usually during the first 4 to 5 years after birth. (14)

The rate of development of osteoarthritis in patients treated for DDH is unknown. Those who have residual dysplasia certainly are at higher risk, but later osteoarthritis is a consideration even in those who have normal-appearing hips at skeletal maturity. Osteoarthritis in patients who have a history of DDH is a leading cause of joint replacement in adults, occurring as young as the third decade after birth.

Summary

- Based on strong research evidence, the primary risk factors for developmental dysplasia of the hip (DDH) include female gender, family history, and breech presentation. (7)(15)
- Based on current standards of care and published guidelines, all children should receive routine clinical evaluation of their hips at each scheduled health supervision visit. (7)(11)
- Based primarily on consensus due to the lack of relevant clinical studies, children who have equivocal findings or increased risk factors for DDH (and normal examination findings) should undergo imaging with ultrasonography at age 3 to 4 weeks, or plain radiographs at 4 to 5 months if reliable ultrasonography is not available. (7)(8)(11)
- Based on strong research evidence, infants who manifest adventitial hip clicks do not require further imaging or referral to an orthopedic surgeon. (5)(7)
- Based on consensus due to the lack of relevant clinical studies, children who have unstable hips on clinical examination should be referred for treatment by an orthopedist. (7)(11)
- Based on consensus due to the lack of relevant clinical studies, children who have abnormal findings on radiographic evaluation, either on ultrasonography or plain radiographs, should be referred to an orthopedist for evaluation and determination of appropriate management. (7)(11)

References

1. Paton RW, Choudry Q. Neonatal foot deformities and their relationship to developmental dysplasia of the hip: an 11-year prospective, longitudinal observational study. *J Bone Joint Surg Br.* 2009;91(5):655–658
2. von Heideken J, Green DW, Burke SW, et al. The relationship between developmental dysplasia of the hip and congenital muscular torticollis. *J Pediatr Orthop.* 2006;26(6):805–808

3. Hansson G, Nachemson A, Palmén K. Screening of children with congenital dislocation of the hip joint on the maternity wards in Sweden. *J Pediatr Orthop*. 1983;3(3):271–279
4. Ortolani M. Congenital hip dysplasia in the light of early and very early diagnosis. *Clin Orthop Relat Res*. 1976;(119):6–10
5. Bond CD, Hennrikus WL, DellaMaggiore ED. Prospective evaluation of newborn soft-tissue hip “clicks” with ultrasound. *J Pediatr Orthop*. 1997;17(2):199–201
6. Barlow TG. Congenital dislocation of the hip in the newborn. *Proc R Soc Med*. 1966;59(11 pt 1):1103–1106
7. American Academy of Pediatrics. Clinical practice guideline: early detection of developmental dysplasia of the hip. Committee on Quality Improvement, Subcommittee on Developmental Dysplasia of the Hip. *Pediatrics*. 2000;105(4 pt 1):896–905
8. Karmazyn BK, Gunderman RB, Coley BD, et al; American College of Radiology. ACR Appropriateness Criteria on developmental dysplasia of the hip—child. *J Am Coll Radiol*. 2009;6(8):551–557
9. Imrie M, Scott V, Stearns P, Bastrom T, Mubarak SJ. Is ultrasound screening for DDH in babies born breech sufficient? *J Child Orthop*. 2010;4(1):3–8
10. Shipman SA, Helfand M, Moyer VA, Yawn BP. Screening for developmental dysplasia of the hip: a systematic literature review for the US Preventive Services Task Force. *Pediatrics*. 2006;117(3):e557–e576
11. Schwend RM, Schoenecker P, Richards BS, Flynn JM, Vitale M; Pediatric Orthopaedic Society of North America. Screening the newborn for developmental dysplasia of the hip: now what do we do? *J Pediatr Orthop*. 2007;27(6):607–610
12. Shorter D, Hong T, Osborn DA. Screening programmes for developmental dysplasia of the hip in newborn infants. *Cochrane Database Syst Rev*. 2011;(9):CD004595
13. Cashman JP, Round J, Taylor G, Clarke NM. The natural history of developmental dysplasia of the hip after early supervised treatment in the Pavlik harness. A prospective, longitudinal follow-up. *J Bone Joint Surg Br*. 2002;84(3):418–425
14. Murray T, Cooperman DR, Thompson GH, Ballock T. Closed reduction for treatment of development dysplasia of the hip in children. *Am J Orthop (Belle Mead NJ)*. 2007;36(2):82–84
15. Goldberg MJ. Early detection of developmental hip dysplasia: synopsis of the AAP Clinical Practice Guideline. *Pediatr Rev*. 2001;22(4):131–134

PIR Quiz

This quiz is available online at <http://www.pedsinreview.aappublications.org>. NOTE: Since January 2012, learners can take *Pediatrics in Review* quizzes and claim credit online *only*. No paper answer form will be printed in the journal.

New Minimum Performance Level Requirements

Per the 2010 revision of the American Medical Association (AMA) Physician's Recognition Award (PRA) and credit system, a minimum performance level must be established on enduring material and journal-based CME activities that are certified for *AMA PRA Category 1 Credit™*. In order to successfully complete 2012 *Pediatrics in Review* articles for *AMA PRA Category 1 Credit™*, learners must demonstrate a minimum performance level of 60% or higher on this assessment, which measures achievement of the educational purpose and/or objectives of this activity.

Starting with the 2012 issues of *Pediatrics in Review*, *AMA PRA Category 1 Credit™* may be claimed only if 60% or more of the questions are answered correctly. If you score less than 60% on the assessment, you will be given additional opportunities to answer questions until an overall 60% or greater score is achieved.

1. On a routine health supervision visit, a 2-month-old boy exhibits a positive Ortolani sign on the right. The infant was born after a spontaneous, vaginal delivery with breech presentation. He has been growing normally, and the remaining findings of the examination are normal. The mother has been keeping the infant swaddled with hips in a flexed and abducted position. He is breastfed exclusively and refuses to take oral multivitamin drops. Which of the following is the most important risk factor for his hip abnormality?
 - A. Improper swaddling position
 - B. Male gender
 - C. Teratologic dislocation
 - D. Third trimester fetal positioning
 - E. Vitamin D deficiency
2. A mother is concerned about her 3-day-old girl having developmental dysplasia of the hip. Which of the following clinical findings is the strongest indicator of unstable hip joint?
 - A. Observation of asymmetric gluteal creases with infant lying in prone position and asymmetric thigh creases when lying in supine position

- B. With infant lying supine, and both hips and knees flexed 90 degrees, the knee on the side of the affected hip appears higher than the unaffected side
 - C. With infant lying supine and contralateral hip stabilized, and hip flexed 90 degrees, abducting the thigh while lifting greater trochanter anteriorly elicits a clunk
 - D. With infant lying supine and contralateral hip stabilized, flexion of the hip to 90 degrees and adduction of the thigh just past midline while pushing it posteriorly elicits a click
 - E. With infant lying supine and in frog-leg position, while the contralateral hip is stabilized, abduction of the hip is restricted and painful on the affected side
3. You are examining a 3-day-old infant and elicit a definite clunk while performing the Ortolani test on the right hip. Which of the following is the next most appropriate step?
- A. Arrange for a hip abduction brace (Pavlik harness) to be worn at night
 - B. Decision should be based on findings of magnetic resonance imaging of the right hip
 - C. Decision should be based on findings of ultrasound examination of the right hip
 - D. Reassure the mother and re-examine the infant in 1 to 2 weeks
 - E. Schedule an urgent consultation or appointment with pediatric orthopedist within 1 week
4. Examination of a 2-week-old girl, born via vaginal delivery after breech presentation, reveals asymmetric gluteal folds. Upon performing the Ortolani maneuver, you experience what appears to be a superficial adventitious click. Which of the following statements is most accurate in light of the total clinical picture?
- A. Immediate consultation with a pediatric orthopedist should be arranged
 - B. Infant should be cared for in a hip abduction brace (Pavlik harness) until physical examination is repeated at age 3 to 4 weeks
 - C. Ultrasonographic examination of the hip need not be performed if the clinician is convinced that the examination reveals a "click" and not a "clunk"
 - D. Ultrasonographic examination of the hip should be performed at age 3 to 4 weeks
 - E. Ultrasonographic examination of the hip should be performed now
5. A mother, who herself had developmental dysplasia of the hip as an infant, is concerned about her newly born son having the same condition. Which of the following is the most appropriate course of action?
- A. Clinical examination now to ensure hip stability and at each recommended health supervision visit until a normal gait is established
 - B. Clinical examination now to ensure hip stability and reassure the mother that her child, being a male, is not at risk for developmental dysplasia of the hip
 - C. Ultrasonographic examination of hips now to exclude the possibility of developmental dysplasia of the hip
 - D. Urgent referral to pediatric orthopedist now to exclude the possibility of developmental dysplasia of the hip
 - E. Radiograph of the hips to measure the α -angle of the femoral head now and at age 3 months

HealthyChildren.org Parent Resources From the AAP

The reader is likely to find material to share with parents that is relevant to this article by visiting this link:
<http://www.healthychildren.org/English/health-issues/conditions/orthopedic/pages/Hip-Dysplasia.aspx>

Developmental Dysplasia of the Hip

Blaise A. Nemeth and Vinay Narotam

Pediatrics in Review 2012;33;553

DOI: 10.1542/pir.33-12-553

Updated Information & Services

including high resolution figures, can be found at:
<http://pedsinreview.aappublications.org/content/33/12/553>

References

This article cites 12 articles, 2 of which you can access for free at:
<http://pedsinreview.aappublications.org/content/33/12/553#BIBL>

Permissions & Licensing

Information about reproducing this article in parts (figures, tables) or in its entirety can be found online at:
<http://pedsinreview.aappublications.org/site/misc/Permissions.xhtml>

Reprints

Information about ordering reprints can be found online:
<http://pedsinreview.aappublications.org/site/misc/reprints.xhtml>

American Academy of Pediatrics

DEDICATED TO THE HEALTH OF ALL CHILDREN™





Celebrating
35 Years

Pediatrics in Review

An Official Journal of the American Academy of Pediatrics

Developmental Dysplasia of the Hip

Blaise A. Nemeth and Vinay Narotam

Pediatrics in Review 2012;33;553

DOI: 10.1542/pir.33-12-553

The online version of this article, along with updated information and services, is located on the World Wide Web at:

<http://pedsinreview.aappublications.org/content/33/12/553>

Pediatrics in Review is the official journal of the American Academy of Pediatrics. A monthly publication, it has been published continuously since 1979. Pediatrics in Review is owned, published, and trademarked by the American Academy of Pediatrics, 141 Northwest Point Boulevard, Elk Grove Village, Illinois, 60007. Copyright © 2012 by the American Academy of Pediatrics. All rights reserved. Print ISSN: 0191-9601.

American Academy of Pediatrics

DEDICATED TO THE HEALTH OF ALL CHILDREN™

