

## Pulse Oximetry and the Neonate

Philip Roth, MD, PhD\*

\*Staten Island University Hospital, Hofstra-North Shore/LIJ School of Medicine, Staten Island, NY.

**AUTHOR DISCLOSURE** Dr Roth has disclosed no financial relationships relevant to this article. This commentary does not contain a discussion of an unapproved/investigative use of a commercial product/device.

Evaluation of the newborn who has cyanosis requires prompt and logical assessment. Although entities such as polycythemia and methemoglobinemia must be considered, the diagnoses that must be addressed most urgently are primary respiratory disease, congenital heart disease (CHD), and persistent pulmonary hypertension of the newborn (PPHN). These categories of disease are not mutually exclusive, as in the case of meconium aspiration with PPHN, but their distinct pathophysiologic mechanisms account for different results in diagnostic testing.

The essence of PPHN lies in the pathologic failure of pulmonary artery pressure to decline postnatally. Although pulmonary artery pressure varies directly with pulmonary vascular resistance (PVR), pulmonary blood flow, and pulmonary capillary wedge pressure, the first of these plays the most prominent role in PPHN. Persistently elevated PVR may result from the perinatal failure to elaborate nitric oxide and/or prostaglandin I<sub>2</sub> in addition to increased production of phosphodiesterase-3 or -5, endothelin-1, reactive oxygen species, and rho-kinase. The net effect is right ventricular dysfunction as well as right-to-left shunting across fetal channels (ie, the patent foramen ovale and ductus arteriosus), which results in decreased pulmonary blood flow. The affected infant develops ventilation/perfusion mismatch, hypoxemia, and acidosis that can lead to left ventricular dysfunction, decreased output, and shock. When differentiating PPHN from cyanotic CHD, the clinician must pay careful attention to patient history; familial occurrence of CHD; and risk factors for PPHN, including sepsis, perinatal asphyxia, intrauterine growth restriction, and maternal medications (eg, selective serotonin reuptake inhibitors, indomethacin) (Table 1).

On physical examination, the clinician should auscultate for heart murmurs, compare upper and lower extremity pulses, assess for hypotension associated with the patient's cyanosis, and examine the cardiac silhouette on chest radiography. For many years, the "hyperoxia test" was used to distinguish the 3 major causes of cyanosis. Arterial blood gases were obtained before and after infants were placed in 100% oxygen. If an initially low Pao<sub>2</sub> rose to equal to or greater than 150 mm Hg following hyperoxia, the likely diagnosis was respiratory disease. Nonresponders with either cyanotic CHD or PPHN were subsequently hyperventilated. Decreased Paco<sub>2</sub> and alkalosis would dilate the pulmonary vasculature in PPHN, resulting in increased Pao<sub>2</sub>, which would not be the case in cyanotic CHD. Recently, echocardiography with color Doppler directional flow has supplanted the hyperventilation phase of the hyperoxia test. However, use of blood gases is limited by the technical difficulty in obtaining them by arterial puncture; a falsely low Pao<sub>2</sub> may result when an infant's crying leads to increased right-to-left shunting. Also, changes in clinical status may not be evident during the interval between the 2 samplings. Consequently, the routine introduction of pulse oximetry into the care of neonates has had a significant impact.

**Critical Congenital Heart Disease Screening Using Pulse Oximetry.** Frank LH, Bradshaw E, Beckman R, Mahle WT, Martin GR. *J Pediatr.* 2013;162(3):445–453

**Diagnosis and Treatment of Pulmonary Hypertension in Infancy.** Steinhorn RH. *Early Hum Dev.* 2013;89(11):865–874

**Role of Pulse Oximetry in Examining Newborns for Congenital Heart Disease: A Scientific Statement from the AHA and AAP.** Mahle WT, Newburger JW, Matherne GP, et al; American Heart Association Congenital Heart Defects Committee of the Council on Cardiovascular Disease in the Young, Council on Cardiovascular Nursing, and Interdisciplinary Council on Quality of Care and Outcomes Research; American Academy of Pediatrics Section on Cardiology and Cardiac Surgery; Committee on Fetus and Newborn. *Pediatrics* 2009;124(2):823–836

**Persistent Pulmonary Hypertension of the Newborn: Advances in Diagnosis and Treatment.** Jain A, McNamara PJ. *Semin Fetal Neonatal Med.* 2015;20(4):262–271

**Meconium Stained Fluid: Approach to the Mother and the Baby.** Welsh NC, Fanaroff JM. *Clin Perinatol.* 2007;34(4):653–665

**TABLE 1. Disorders Associated with Persistent Pulmonary Hypertension of the Newborn**

- Idiopathic
- Meconium aspiration syndrome
- Respiratory distress syndrome
- Transient tachypnea of the newborn
- Pneumonia/sepsis
- Lung hypoplasia
- Congenital diaphragmatic hernia
- Medications: Indomethacin, selective serotonin reuptake inhibitors
- Other
  - Alveolar capillary dysplasia
  - Surfactant protein B deficiency
  - ABCA<sub>3</sub> surfactant deficiency
  - Pulmonary lymphangiectasia
  - Congenital lobar emphysema
  - Cystic adenomatoid malformation

*Adapted from Steinhorn R. Diagnosis and treatment of pulmonary hypertension in infancy. Early Human Dev. 2013;89(11):865-74.9, with permission from Elsevier.*

A pulse oximeter uses 2 diodes emitting light at 640 nm (red) and 940 nm (infrared), which are selectively absorbed by oxyhemoglobin and deoxyhemoglobin, respectively. Measurement of red and infrared light emerging from the tissue and calculation of their ratio are used to determine the oxygen saturation. Because visual recognition of cyanosis requires the presence of equal to or greater than 5 g/dL of deoxyhemoglobin, pulse oximetry allows detection of more subtle levels of desaturation. In addition, placement of 1 pulse oximeter probe on a preductal site (eg, right hand) and a second on a postductal site (eg, either foot) allows detection of ductal shunting, which occurs in 90% of cases of PPHN. With a threshold pre-to-postductal saturation difference of equal to or greater than 10%, oximetry can be used initially at diagnosis as well as to detect onset of shunting with patient agitation or clinical interventions (eg, suctioning). Unlike the labile oxygenation of the infant with PPHN, patients with cyanotic CHD have fixed low oxygen saturations. However, once prostaglandin E<sub>1</sub> infusion is initiated to maintain

ductal patency in CHD lesions dependent on it for oxygenation, achievement and maintenance of higher saturations are readily noted. In PPHN associated with meconium aspiration syndrome, once the shunting resolves, the effects of parenchymal lung disease may persist for days to weeks. Consequently, every effort should be made to minimize barotrauma through “gentler” ventilation, use of high-frequency oscillatory ventilation to optimize lung volumes, and tolerance of lower pH (7.25-7.29) and higher PaCO<sub>2</sub> (50-60 mm Hg) in arterial blood.

Aside from its use in the early evaluation of cyanotic CHD, pulse oximetry can also play a key role in the detection of critical congenital heart disease (CCHD) in asymptomatic infants. CCHD, defined as lesions that require intervention in the first postnatal year for survival, account for approximately 25% of CHD cases, but the condition may not be evident initially because of incomplete transition from the fetal circulation (ie, elevated PVR and/or continued patency of the ductus arteriosus). Heart lesions with ductal-dependent pulmonary or systemic blood flow are most prominent in this category (Table 2). Because fetal ultrasonography detects only about 50% of CCHDs, particularly lesions with

**TABLE 2. Critical Congenital Heart Disease Defects**

- Left-sided obstructive lesions
  - Hypoplastic left heart syndrome
  - Interrupted aortic arch
  - Critical coarctation of the aorta
  - Critical aortic stenosis
- Right-sided obstructive lesions
  - Pulmonary atresia with intact septum
  - Tricuspid atresia
  - Critical pulmonary stenosis
  - Tetralogy of Fallot
- Mixing lesions
  - Total anomalous pulmonary venous return
  - Transposition of the great arteries
  - Truncus arteriosus communis

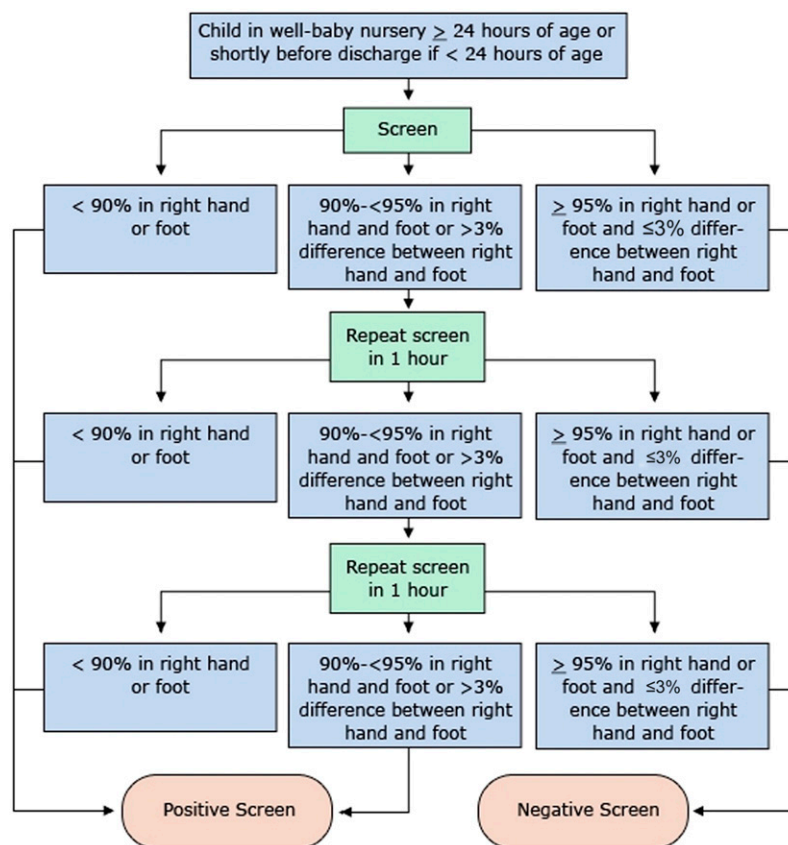
*Reprinted from Bruno CJ, Havranek T. Screening for critical congenital heart disease in newborns. Adv Pediatr. 2015;62(1):211-226, with permission from Elsevier.*

single-ventricle configurations, its overall reliability is limited. Therefore, in the absence of effective screening, delays in diagnosis occur, leading to increased mortality, surgical morbidity, and neurodevelopmental disability. Echocardiography would be the gold standard for detection, but use of this modality in every baby would be impractical and cost-ineffective. As a result, newborn screening with pulse oximetry has become the standard in an increasing number of states. Recently, screening has expanded from pulse oximetry on a single site to 2 measurements: one preductal and the second postductal. As shown in the algorithm (Figure), a positive result of screening when performed at more than 24 hours of age consists of a single reading of less than 90% on any site OR 3 consecutive hourly readings of either 90% to 94% on any site or a difference of greater than 3% between upper and lower extremities.

This methodology for CCHD screening provides sensitivity between 75% and 80%, specificity greater than 99%, positive predictive value of 26%, and negative predictive value of greater than 99%. Even with the fewer than 1%

of neonates who have false-positive screening results for CCHD, echocardiography performed on these children may reveal other clinically relevant conditions, such as pulmonary hypertension. On this basis, CCHD screening is cost-effective; with \$5 to \$10 expended per child screened, detecting 1 case of CCHD before clinical deterioration offsets the cost of screening approximately 2,000 healthy newborns. Lesions that are the most difficult to detect include aortic outflow obstruction, which often presents later compared to other CCHDs. Further studies are required to determine the proper timing, if any, for CCHD screening in the NICU, where pulse oximetry is already being used for regular monitoring and other coexisting conditions (eg, prematurity, sepsis, and primary lung disease) and can complicate analysis.

Pulse oximetry has had a dramatic impact on neonatal care in the: 1) detection of subtle cyanosis (<5 g/dL deoxyhemoglobin), 2) differentiation of CHD and PPHN in the infant with acute cyanosis, and 3) detection of CCHD in the asymptomatic newborn.



**Figure** Pulse oximetry screening protocol. Reprinted from the public domain from the U.S. Centers for Disease Control and Prevention. Available at <http://www.cdc.gov/ncbddd/heartdefects/hcp.html>, as adapted from Kemper AR, Mahle WT, Martin GR, et al. Strategies for implementing screening for critical congenital heart disease. *Pediatrics*. 128(5). Available at: [www.pediatrics.org/cgi/content/full/128/5/e1259](http://www.pediatrics.org/cgi/content/full/128/5/e1259).

**COMMENT:** For those of us who felt like medieval torturers when jabbing the radial arteries of cyanotic neonates in a search for that arterial blood flow that seemed stubbornly resistant to our desperate efforts, the advent of pulse oximetry has been akin to the alchemist's dream of turning lead into gold. How much easier for us, and of course, more importantly, how much nicer for the children. Further, if we

can't yet prevent the occurrence of critical congenital heart disease, at least we have a safe and efficient tool for identifying affected infants before they suffer irreversible harm, which is progress indeed!

– Henry M. Adam, MD  
Associate Editor, *In Brief*

## Parent Resources from the AAP at HealthyChildren.org

### Pulse Oximetry and the Neonate

- <https://www.healthychildren.org/English/ages-stages/baby/Pages/Newborn-Screening-Tests.aspx>
- Spanish: <https://www.healthychildren.org/spanish/ages-stages/baby/paginas/newborn-screening-tests.aspx>
- <https://www.healthychildren.org/English/ages-stages/baby/preemie/Pages/When-Baby-Needs-Oxygen-At-Home.aspx>
- Spanish: <https://www.healthychildren.org/spanish/ages-stages/baby/preemie/paginas/when-baby-needs-oxygen-at-home.aspx>

### CME Quiz Corrections

An error was found in the CME quiz for the December 2015 article “Pain and Symptom Management in Pediatric Palliative Care” (Komatz K, Carter B. *Pediatrics in Review*. 2015;36(12):257–534, doi: 10.1542/pir.36-12-527). The correct answer for Question 4 should be “C. Ondansetron,” with the following rationale: “Ondansetron, a serotonin 5-HT<sub>3</sub> receptor antagonist, may be used in children older than 4 years to prevent postoperative nausea and vomiting, or that associated with chemotherapy.” The quiz has been corrected. A correction notice has been posted with the online version of the article. The journal regrets the error.

In the CME quiz for the August 2016 review “Inflammatory Bowel Disease” (Shapiro JM, Subedi S, LeLeiko NS. *Pediatrics in Review*. 2016;37(8):337–347, DOI: 10.1542/pir.2015-0110), the correct answer for Question 3 is “A. Endoscopy.” The quiz has been corrected. A correction notice has been posted with the online version of the article. The journal regrets the error.

### ANSWER KEY FOR SEPTEMBER 2016 PEDIATRICS IN REVIEW:

Acid-Base Disorders: 1. A; 2. B; 3. E; 4. C; 5. B.  
Evaluation and Initial Management of Hypopituitarism: 1. A; 2. E; 3. D; 4. D; 5. E.  
Chronic and Recurrent Abdominal Pain: 1. B; 2. B; 3. B; 4. D; 5. C.

## Pulse Oximetry and the Neonate

Philip Roth

*Pediatrics in Review* 2016;37;402

DOI: 10.1542/pir.2015-0174

### Updated Information & Services

including high resolution figures, can be found at:  
<http://pedsinreview.aappublications.org/content/37/9/402>

### References

This article cites 5 articles, 1 of which you can access for free at:  
<http://pedsinreview.aappublications.org/content/37/9/402#BIBL>

### Subspecialty Collections

This article, along with others on similar topics, appears in the following collection(s):  
**Fetus/Newborn Infant**  
[http://classic.pedsinreview.aappublications.org/cgi/collection/fetus:newborn\\_infant\\_sub](http://classic.pedsinreview.aappublications.org/cgi/collection/fetus:newborn_infant_sub)  
**Neonatology**  
[http://classic.pedsinreview.aappublications.org/cgi/collection/neonatology\\_sub](http://classic.pedsinreview.aappublications.org/cgi/collection/neonatology_sub)  
**Birth Defects**  
[http://classic.pedsinreview.aappublications.org/cgi/collection/birth\\_defects\\_sub](http://classic.pedsinreview.aappublications.org/cgi/collection/birth_defects_sub)

### Permissions & Licensing

Information about reproducing this article in parts (figures, tables) or in its entirety can be found online at:  
<http://classic.pedsinreview.aappublications.org/site/misc/Permissions.xhtml>

### Reprints

Information about ordering reprints can be found online:  
<http://classic.pedsinreview.aappublications.org/site/misc/reprints.xhtml>

American Academy of Pediatrics

DEDICATED TO THE HEALTH OF ALL CHILDREN™





# Pediatrics in Review

An Official Journal of the American Academy of Pediatrics

## **Pulse Oximetry and the Neonate**

Philip Roth

*Pediatrics in Review* 2016;37;402

DOI: 10.1542/pir.2015-0174

The online version of this article, along with updated information and services, is located on the World Wide Web at:

<http://pedsinreview.aappublications.org/content/37/9/402>

Pediatrics in Review is the official journal of the American Academy of Pediatrics. A monthly publication, it has been published continuously since 1979. Pediatrics in Review is owned, published, and trademarked by the American Academy of Pediatrics, 141 Northwest Point Boulevard, Elk Grove Village, Illinois, 60007. Copyright © 2016 by the American Academy of Pediatrics. All rights reserved. Print ISSN: 0191-9601.

American Academy of Pediatrics

DEDICATED TO THE HEALTH OF ALL CHILDREN™

