

PediatricsinReview®

Seizures in Children : Determining the Variation

Philippe Major and Elizabeth A. Thiele

Pediatrics in Review 2007;28;363

DOI: 10.1542/pir.28-10-363

The online version of this article, along with updated information and services, is located on the World Wide Web at:

<http://pedsinreview.aappublications.org/content/28/10/363>

Pediatrics in Review is the official journal of the American Academy of Pediatrics. A monthly publication, it has been published continuously since 1979. Pediatrics in Review is owned, published, and trademarked by the American Academy of Pediatrics, 141 Northwest Point Boulevard, Elk Grove Village, Illinois, 60007. Copyright © 2007 by the American Academy of Pediatrics. All rights reserved. Print ISSN: 0191-9601.

American Academy of Pediatrics

DEDICATED TO THE HEALTH OF ALL CHILDREN™



Seizures in Children: Determining the Variation

Philippe Major, MD,*
Elizabeth A. Thiele, MD,
PhD*

Author Disclosure
Dr Major did not disclose any financial relationships relevant to this article. Dr Thiele disclosed that she is a consultant to Abbott Laboratories.

Objectives After completing this article, readers should be able to:

1. Classify the different seizure types.
2. Distinguish seizures from other paroxysmal phenomena.
3. List the possible causes of seizures according to age and mode of presentation.

Introduction

Seizures are among the most common pediatric neurologic disorders. The overall prevalence of epilepsy is approximately 1%, and as many as 5% of all children experience febrile seizures before the age of 6 years. Seizures are caused by an abnormal and excessive discharge of neurons, usually accompanied by behavioral or sensorimotor manifestations. Epilepsy is defined classically as the occurrence of two or more unprovoked seizures.

A seizure can be viewed as a symptom of an underlying central nervous system disorder that requires thorough evaluation and specific treatment. In addition to the consequences of the seizures, 50% of those who have epilepsy experience learning difficulties, and 30% to 50% have mental health and behavioral issues.

In this first of two articles on seizures in children, we review the diagnosis and classification of seizures as well as possible causes of seizures in childhood. The second article, to be published in the November 2007 issue of *Pediatrics in Review*, focuses on the laboratory diagnosis and management of seizure disorders.

Diagnosis and Causes of Seizures

The diagnosis of epilepsy and classification of specific seizure types are essential to determining a prognosis and choosing an appropriate treatment. The investigation of a child experiencing seizures begins with a medical history and physical examination. Although significant technologic advances have been made in electrophysiology and neuroimaging, the diagnosis of seizures and epilepsy remains largely clinical. Table 1 lists key features of the medical history and physical examination of a child presenting with paroxysmal events.

The first diagnostic step is to determine if the clinical presentation is compatible with seizures or with other paroxysmal phenomena. Although this distinction often is easy to make clinically, certain conditions (especially syncope, pseudoseizures, and tics) can be confused with seizures (Table 2). Syncope generally is preceded by dizziness, blurring of vision, feeling of imminent loss of consciousness, and pallor; seizures typically begin suddenly or are preceded by a brief specific aura. Syncope usually occurs during the daytime when the patient is in the upright position; seizures can occur at any time, in any position. Brief tonic or clonic movements sometimes follow syncope, but they are not classified as epileptic seizure activity.

Pseudoseizures should be suspected when the events are triggered by emotional disturbance or by suggestion, when the abnormal movements are not compatible with a typical seizure (pelvic thrusting, side-to-side head movement, forced eye closure), when the events occur most frequently during the daytime in the presence of other people, and when there is no postictal state. Tics are stereotyped, recurrent paroxysmal events that can be differentiated from seizures by the patient's ability to suppress them consciously.

When epilepsy is diagnosed, the cause remains unknown in 65% to 70% of patients. If no identifiable cause is determined following a complete investigation, the epilepsy is labeled

*Department of Neurology, Massachusetts General Hospital, Boston, Mass.

Table 1. Questionnaire and Physical Examination of the Patient Experiencing Paroxysmal Events

Questionnaire

- Handedness
- Pregnancy history: Ultrasonography results, infections, medications, alcohol use, cigarette smoking, drug abuse, trauma, prematurity
- Prenatal history: Labor duration, spontaneous vaginal delivery or cesarean section, birth difficulties (resuscitation, intubation), birthweight, head circumference at birth
- Development: Fine motor, language, gross motor, and social skills
- School functioning
- General medical history: Head trauma, meningitis, stroke
- Medications
- Family history: Epilepsy, febrile seizures, mental retardation
- Description of the events: aura; motor (myoclonic or clonic jerk, hypertonia, atonia, chewing movements), sensory (somesthetic, auditive, visual, gustatory), autonomic, or psychologic phenomena; automatisms; level of consciousness; tongue-biting; fecal or urinary incontinence; episode length; postictal state
- Age at event onset
- Event frequency
- Precipitating factors: Fever, sleep deprivation, stress, photosensitivity, drugs, alcohol withdrawal, or others
- Diurnal and nocturnal patterns
- Travel history
- Employment
- Driving

Physical Examination

- State of consciousness, language, social interactions
- Observation of the events (if possible); hyperventilation sometimes can provoke absence seizures
- Global development
- Dysmorphic features, limb asymmetry, neurocutaneous skin findings, organomegaly
- Head circumference
- Neurologic examination: Cranial nerves, motor strength and tone, osseotendinous reflexes, sensory and cerebellar function tests, gait

as “idiopathic” in patients who have normal development and physical findings. The epilepsy is labeled as

“probably symptomatic” or “cryptogenic” in patients who have signs of abnormal brain function. When the seizures are the result of an identifiable brain lesion, the epilepsy is termed “symptomatic.”

The potential causes of symptomatic epilepsy can be categorized as inherited genetic, congenital, and acquired (Table 3). Although the proportion of epilepsies of unknown cause remains stable at different ages, the causes of symptomatic epilepsies differ greatly, depending on the patient’s age (Figure). In newborns, the most frequent symptomatic causes of epilepsy are brain malformations, infections, metabolic disorders (pyridoxine deficiency, hypoglycemia, hyponatremia, hypocalcemia, urea cycle disorders), hypoxic-ischemic encephalopathy, intracranial hemorrhage, and familial neonatal convulsions. In children, inherited metabolic or developmental diseases, idiopathic/genetic syndromes, infections, cortical dysplasias, and degenerative disorders may be causative. Symptomatic epilepsy in adolescents is caused pri-

Table 2. Differential Diagnosis of Seizures (abbreviated list)

- Syncope
- Daydreaming
- Parasomnias
- Migraine
- Breath-holding spells
- Transient ischemic events
- Vestibular disorders
- Gastroesophageal reflux
- Movement disorders (tics, paroxysmal choreoathetosis)
- Psychotic hallucinations and delusions
- Nonepileptic events (pseudoseizures)
- Panic attacks

Table 3. Causes of Symptomatic Epilepsy (abbreviated list)

Inherited Genetic

- Channelopathies, defined as mutations of neuronal ion channels (eg, one sodium channel defect is associated with benign familial neonatal seizures)
- Chromosomal abnormalities
 - Trisomies 13, 18, 21, 22
 - Deletion of chromosome 4p (Wolf-Hirschhorn syndrome)
 - Partial 5p monosomy (cri du chat)
 - Ring chromosome 14 and 20
- Mitochondrial DNA disorders
 - Myoclonic epilepsy and ragged red fibers (MERRF)
 - Mitochondrial myopathy, encephalopathy, lactic acidosis, strokelike episodes (MELAS)
- Metabolic disorders
 - Aminoacidopathies
 - Galactosemia
 - Lysosomal lipid storage diseases (eg, Tay-Sachs)
 - Leukodystrophies
 - Mucopolysaccharidoses
 - Peroxisomal disorders
 - Pyridoxine deficiency
- Hereditary neurocutaneous disorders
 - Tuberous sclerosis complex
 - Neurofibromatosis
 - Sturge Weber syndrome

Congenital (Inherited or Acquired)

- Developmental cortical malformations
- Cerebral tumor
- Vascular malformations
- Prenatal injury

Acquired

- Trauma
- Neurosurgery
- Infection
- Vascular disease
- Hippocampal sclerosis
- Tumors
- Neurodegenerative disorders
- Metabolic disorders
- Toxic disorders

marily by mesial temporal sclerosis, degenerative diseases, trauma, and tumors.

Classification of Epileptic Seizures

In 1981, the International League Against Epilepsy (ILAE) classified epilepsy according to partial or generalized seizure types (Table 4). The 1989 ILAE classification delineated specific epileptic syndromes (Table 5).

Partial seizures are caused by the abnormal activation of a limited number of neurons and are manifested by signs and symptoms that often allow clinical localization of the epileptic focus. Table 6 provides key features of partial seizure semiology. In contrast to simple partial seizures, complex partial seizures are associated with loss of consciousness. They also can be preceded by an aura and accompanied by various types of automatisms. Partial seizures generalize secondarily if the epileptic activity propagates to the entire brain.

Generalized seizures are caused by a global synchronous activation of neurons and always impair consciousness. Motor changes and electroencephalography (EEG) abnormalities are observed bilaterally in a grossly synchronous and symmetric pattern.

Typical absence seizures (formerly referred to as petit mal) are characterized by frequent, brief, abrupt losses of consciousness, often accompanied by eyelid flickering, that typically end abruptly with resumption of activity. The ictal EEG shows 3-Hz symmetric and synchronous spike and wave activity; the interictal tracing typically appears normal. Absence seizures occasionally can be induced by hyperventilation or photic stimulation. Although typical absence seizures are considered idiopathic, atypical absence seizures most frequently are associated with symptomatic or probably symptomatic epilepsies. Table 7 compares typical and atypical absence seizures.

Myoclonic seizures consist of brief contractions of a muscle, muscle group, or several muscle groups caused by a cortical discharge. Action, noise, startle, photic stimulation, or percussion sometimes can provoke such seizures. The ictal EEG shows generalized spike, spike and wave, or polyspike and wave discharges, often asymmetric or irregular and with frontal predominance.

Clonic seizures are characterized by jerking that often is asymmetric and irregular. Clonic seizures occur more frequently in neonates, infants, or young children. The ictal EEG shows fast activity (10 Hz), often mixed with higher-amplitude slow waves or polyspike and wave discharges.

Tonic seizures cause sustained muscle contraction without a clonic phase. They occur at any age and frequently are associated with diffuse cerebral damage and often are seen in children who have Lennox-Gastaut syndrome. The ictal EEG shows a flattening or attenuation of the background activity and fast activity (15 to 25 Hz), with increasing amplitude as the seizure progresses. The interictal EEG often shows generalized epileptic discharges.

Tonic-clonic seizures (grand mal) are characterized

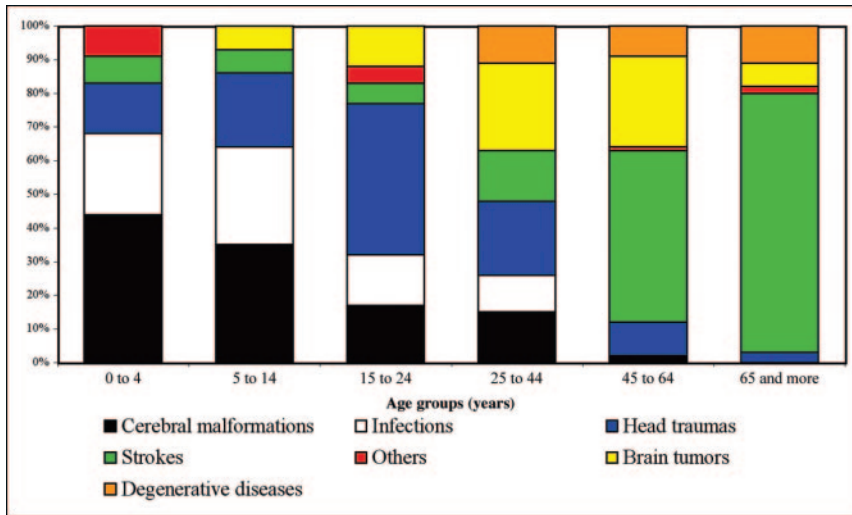


Figure. Proportional incidences for symptomatic epilepsies according to age and etiology. Adapted from Annegers JF. The epidemiology of epilepsy. In: Willie E, ed. *The Treatment of Epilepsy: Principles and Practice*. Philadelphia, Pa: Lea & Febiger; 2001:135.

by three successive phases: tonic, clonic, and postictal. The tonic phase typically lasts 10 to 30 seconds and is associated with desynchronization or attenuation on EEG. The seizure progresses to a clonic phase that lasts 30 to 60 seconds in which bursts of faster activity are seen on the EEG. The postictal period usually consists of a state of confusion and fatigue for 2 to 30 minutes and is characterized by diffuse slowing on EEG.

Epileptic Syndromes

The 1989 ILAE classification defines epileptic syndromes (Table 5) by the association of specific clinical, electroencephalographic, and imaging characteristics. Of the several epilepsy syndromes, many are associated with significant neurologic impairment. Following are descriptions of some of the most frequent types of epilepsies and epilepsy syndromes in childhood. Specific treatments for these conditions are discussed in the second article.

Major Focal (Partial) Epilepsies

Benign partial epilepsy with centrotemporal spikes (also called benign rolandic epilepsy) is the most common partial epilepsy syndrome in children. The typically affected child presents between 3 and 13 years of age with partial seizures characterized by tonic or clonic activity and paresthesias of the lower face, which often are unilateral and associated with drooling and dysarthria. Seizures are infrequent, commonly occur nocturnally, and rarely become secondarily generalized. The EEG

shows characteristic unilateral or bilateral centrotemporal high-voltage sharp waves activated by drowsiness and sleep. Neuroimaging studies should be performed to rule out other disorders, such as parasagittal tumors.

Temporal lobe epilepsy generally begins with partial seizures in childhood, followed by a seizure-free period until adolescence, when seizures reappear. A history of febrile seizures (mostly atypical) is found in about 35% of patients who have intractable temporal lobe epilepsy. Seizures frequently are preceded by an aura (epigastric discomfort, déjà vu [“already seen”], déjà entendu [“already heard”]), psychic symptoms such as fear, or automatisms (oroalimentary repet-

itive movements, vocalizations). Compared with frontal lobe epilepsy, secondary generalization happens less often and seizures occur less frequently.

Frontal lobe epilepsy is characterized by short (10 to 30 sec), frequent partial seizures that tend to occur in clusters, mostly at night. A familial history of frontal lobe seizures sometimes is found. The auras are nonspecific. Automatisms may be bizarre (eg, pedaling movements) and sometimes are mistaken for nonepileptic events. Aversive head and eye deviation may occur. A jacksonian motor seizure (the spread of clonic movements that progresses along contiguous body parts in a pattern corresponding to the body representation on the primary motor strip) sometimes is observed. Complex partial status epilepticus occurs relatively frequently. Postictal Todd paralysis (transient paralysis following a seizure) sometimes is noted, particularly if the seizure focus is located near the motor cortex.

Parietal lobe epilepsy generally causes simple partial seizures with somatosensory symptoms such as paresthesias (sometimes painful), apraxia, and distortion of body image. Visual phenomena consisting of well-formed hallucinations sometimes are reported; pictures of people, animals, or scenes may be perceived. A receptive type of aphasia can occur if the epileptic activity is located on the dominant hemisphere.

Occipital lobe epilepsy is characterized by simple elementary visual symptoms, such as patterns or flashes of light or colors. Contralateral eye deviation and ictal blindness also are described.

Table 4. International Classification of Epileptic Seizures

Partial (Focal, Localized) Seizures

- Simple partial seizures
 - With motor signs
 - With somatosensory or special sensory systems
 - With autonomic symptoms and signs
 - With psychic symptoms
- Complex partial seizures
 - Simple partial onset followed by impairment of consciousness
 - With impairment of consciousness at onset
- Partial seizures evolving to secondarily generalized seizures
 - Simple partial seizures evolving to generalized seizures
 - Complex partial seizures evolving to complex partial seizures evolving to generalized seizures

Generalized Seizures (Convulsive or Nonconvulsive)

- Absence seizures
 - Typical absences
 - Atypical absences
- Myoclonic seizures
- Clonic seizures
- Tonic seizures
- Tonic-clonic seizures
- Atonic seizures

Unclassified Epileptic Seizures

Adapted from the Commission on Classification and Terminology of the International League Against Epilepsy. Proposal for revised clinical and electroencephalographic classification of epileptic seizures. *Epilepsia*. 1981;22:489–501.

Major Generalized Idiopathic Epilepsy Syndromes

Childhood absence epilepsy begins between 3 and 10 years of age in cognitively normal children. Numerous seizures can occur every day. The EEG shows classic ictal generalized 3-Hz spike-and-wave discharges lasting 5 to 10 seconds superimposed on a typically normal interictal background. Photic stimulation and hyperventilation are well-known precipitating factors.

Juvenile absence epilepsy develops around puberty and is associated with less frequent seizures compared with childhood absence epilepsy. Approximately 80% of patients experience tonic-clonic seizures in addition to their absences. A genetic predisposition is observed. The EEG shows generalized spike-and-wave discharges.

Juvenile myoclonic epilepsy (Janz syndrome) typically

begins between 8 and 18 years of age (peak incidence, 15 years old) and usually is characterized by upper limb myoclonic jerks that occur after waking (“morning myoclonus”). Generalized tonic-clonic seizures also occur frequently; many patients experience absence seizures. Sleep deprivation, alcohol, hyperventilation, and photosensitivity are common triggers. A family history of epilepsy is found in 40% of cases. Cognition and neurologic findings are normal. The EEG shows generalized 4 to 6-Hz polyspikes and spike-and-wave epileptic discharges with normal background activity.

Benign neonatal convulsions are characterized by short tonic, clonic, or apneic seizures that begin between 2 and 5 days after birth in neurologically normal infants. The prognosis generally is good, but 15% of patients develop epilepsy in the future. Familial autosomal dominant and sporadic cases are described. In familial cases, seizures occur on the second or third day after birth, and the EEG has no specific pattern. In comparison, seizures in sporadic cases begin at around the fifth postnatal day and show theta bursts on the EEG.

Major Generalized Symptomatic Epilepsy Syndromes

Infantile spasms usually start during the first postnatal year (typically 5 to 12 months of age) and are characterized by symmetric, bilateral, brief, and sudden contractions of the axial muscle groups. The features of the spasms depend on whether the flexor or extensor muscles are predominantly affected. Spasms tend to occur in clusters soon after awakening or on falling asleep. Sudden loud noises or tactile stimulation, but not photic stimulation, may precipitate them. The frequency of spasms varies from only a few times a day to several hundred a day. Periods of attenuated responsiveness may follow a spasm. Children who have infantile spasms often show hypsarrhythmia on EEG, which is a profoundly disorganized background of high-amplitude waves and multifocal spikes. Infantile spasms can be classified as symptomatic, cryptogenic, or idiopathic. The symptomatic group accounts for 75% of cases. Evaluating children for possible tuberous sclerosis complex is critical because this is the single most common cause. Early control of spasms with medication is associated with a better cognitive outcome. Without treatment, spasms tend to disappear spontaneously before 3 years of age. However, as many as 60% of children who have infantile spasms develop other seizure types and epileptic syndromes, such as Lennox-Gastaut syndrome. Also, most children who develop infantile spasms experience significant neurocognitive sequelae.

Table 5. International Classification of Epilepsies, Epileptic Syndromes, and Related Seizure Disorders

Localization-related (Focal, Local, Partial)

- Idiopathic (primary)
 - Benign childhood epilepsy with centrotemporal spikes
 - Childhood epilepsy with occipital paroxysms
 - Primary reading epilepsy
- Symptomatic (secondary)
 - Temporal lobe epilepsies
 - Frontal lobe epilepsies
 - Parietal lobe epilepsies
 - Occipital lobe epilepsies
 - Chronic progressive epilepsia partialis continua of childhood
 - Syndromes characterized by seizures that have specific modes of precipitation
- Cryptogenic, defined by
 - Seizure type
 - Clinical features
 - Anatomic localization

Generalized

- Idiopathic (primary)
 - Benign neonatal familial convulsions
 - Benign neonatal convulsions
 - Benign myoclonic epilepsy in infancy
 - Childhood absence epilepsy (pyknolepsy)
 - Juvenile absence epilepsy
 - Juvenile myoclonic epilepsy (Janz syndrome)
 - Epilepsies with grand mal seizures on awakening
 - Other generalized idiopathic epilepsies
 - Epilepsies with seizures precipitated by specific modes of activation
- Cryptogenic or symptomatic
 - West syndrome (infantile spasms)

- Lennox-Gastaut syndrome
- Epilepsy with myoclonic-astatic seizures
- Epilepsy with myoclonic absences
- Symptomatic (secondary)
 - Nonspecific cause
 - Early myoclonic encephalopathy
 - Early infantile epileptic encephalopathy with suppression burst
 - Other symptomatic generalized epilepsies
 - Specific syndromes
 - Epileptic seizures may complicate many disease states

Undetermined Epilepsies

- With both generalized and focal seizures
 - Neonatal seizures
 - Severe myoclonic epilepsy in infancy (Dravet syndrome)
 - Epilepsy with continuous spike and waves during slow-wave sleep
 - Acquired epileptic aphasia (Landau-Kleffner syndrome)
 - Other undetermined epilepsies
- Without unequivocal generalized and focal features

Special Syndromes

- Situation-related seizures
 - Febrile convulsions
 - Isolated seizures or isolated status epilepticus
 - Seizures occurring only with an acute or toxic event, due to factors such as alcohol, drugs, eclampsia, and nonketotic hyperglycemia

Adapted from Commission on Classification and Terminology of the International League Against Epilepsy. Proposal for a revised classification of epilepsies and epileptic syndromes. *Epilepsia*. 1989;30:389–399.

Lennox-Gastaut syndrome is a condition characterized by the clinical triad of diffuse slow spikes and waves on EEG, mental retardation, and multiple types of generalized seizures, especially atypical absences and tonic and atonic seizures. The disorder can be classified as symptomatic or cryptogenic; 70% of patients are symptomatic, 33% of whom have had infantile spasms. The age of onset is between 2 and 8 years. The prognosis is poor for neurocognitive outcome and seizure control, particularly in symptomatic cases. With age, the intellectual quotient tends to deteriorate and the tonic seizures persist, but the slow spike-and-wave pattern tends to resolve.

Febrile seizures occur in 5% of children between the ages of 3 months and 6 years. A familial predisposition

sometimes is present. The distinction between typical and atypical febrile seizures influences the management and determines the prognosis (Table 8). Typical febrile seizures are considered benign, but can recur in up to 30% to 50% of children, especially if the first seizure occurred during the first year after birth. Such seizures do not increase the risk of future epilepsy significantly. In contrast, 2% to 13% of children who have atypical febrile seizures subsequently develop epilepsy.

When a child presents immediately after a febrile seizure, the goal is to identify a possible infectious source. Usually, no ancillary testing is required for simple febrile seizures, although magnetic resonance imaging or computed tomography scan often is indicated for patients having atypical febrile seizures to evaluate for focal dis-

Table 6. **Partial Seizure Semiology**

Types of Manifestations	Description of the Clinical Manifestations	Brain Regions Involved
Motor	Jerking of extremities	Frontal or central lobes
Somatosensory or special sensory	Tingling or numbness Simple visual phenomena Rising epigastric sensation	Central or parietal lobes Calcarine cortex (occipital) Mesial temporal lobe
Autonomic	Changes in skin color, blood pressure, heart rate, pupil size, piloerection	Frontal or temporal lobes
Psychic	Dysphasia or aphasia Dysmnestic symptoms (flashbacks, déjà-vu, jamais vu, or panoramic experiences) Cognitive symptoms (dreamy state, sensations of unreality or depersonalization) Affective symptoms (fear, depression, anger, irritability) Illusions of perception (size [macro- or micropsia], shape, weight, distance, sound) Structured hallucinations (visual, auditory, gustatory, olfactory)	Frontal or temporoparietal regions Mesial temporal lobe Temporal lobe Mesial temporal lobe Temporal or temporoparietal regions Temporal or parietooccipital regions

case. A lumbar puncture should be performed if meningitis is suspected. Most experts agree that EEG is not required because it does not predict seizure recurrence or the development of epilepsy. Parental reassurance and education are crucial.

Status epilepticus is a neurologic emergency defined traditionally as a continuous seizure or the occurrence of serial seizures, between which there is no return of consciousness, lasting more than 30 minutes. Many experts now suggest that the time threshold should be reduced

to 15 minutes or less to heighten the urgency for treatment. Experimental models have shown that a continuous seizure lasting more than 30 minutes potentially can harm the brain. Excessively increased metabolic demand by constantly discharging neurons produces regional oxygen insufficiency that causes cell damage and necrosis. Three major subtypes of status epilepticus can occur in children: prolonged febrile seizures, idiopathic status epilepticus, and symptomatic status epilepticus. The last subtype is associated with the most morbidity and mor-

Table 7. **Comparison of Typical and Atypical Absence Seizures**

Factor	Typical	Atypical
Age of onset	Childhood	Any age
Onset/offset of seizure	Abrupt	Often gradual
Consciousness	Totally lost	Often partially impaired
Other clinical features during seizure	Slight (eye flickering)	Can be prominent, including aura, automatism
Duration of seizures	Short (usually <10 sec)	Long (usually several minutes)
Frequency of seizures	Numerous, frequently in clusters	Usually less frequent
Postictal	None	Confusion, headache, emotional disturbance are common
Coexisting seizure types	Sometimes tonic-clonic and myoclonic	Mixed seizure disorder is common; all seizure types
Cause	Idiopathic generalized epilepsy	Any focal pathology or probably symptomatic epilepsy
Underlying focal anatomic lesion	None	Limbic structures, neocortex
Other neurologic signs and symptoms	None	Usually learning difficulties
Ictal EEG appearance	3-Hz spike and wave	2 to 2.5-Hz spike and wave
Interictal EEG appearance	Usually normal	Abnormal

Table 8. Characteristics of Typical Febrile Seizures

- Seizure occurrence between ages 3 months and 6 years of age
- Normal development and normal neurologic examination findings
- Duration < 15 min
- Generalized tonic-clonic seizure
- Only one seizure during one febrile episode
- No postictal deficit (eg, Todd paralysis)
- Not caused by a central nervous system infection

tality; the cause of death usually is attributed directly to the underlying abnormality. The mortality associated with status epilepticus is approximately 5%.

Conclusion

Seizures occur frequently in the pediatric population. They have protean clinical manifestations, and the causes are age-dependent. Knowledge of the seizure classification is important to determine appropriate prognosis and treatments.

ACKNOWLEDGMENTS. We are very thankful to Dr Ron Thibert for his help in the preparation of this article.

Suggested Reading

- Commission on Classification and Terminology of the International League Against Epilepsy. Proposal for a revised clinical and electroencephalographic classification of epileptic seizures. *Epilepsia*. 1981;22:489–501
- Commission on Classification and Terminology of the International League Against Epilepsy. Proposal for revised classification of epilepsies and epileptic syndromes. *Epilepsia*. 1989;30:389–399
- Committee on Quality Improvement, Subcommittee on Febrile Seizures. Practice parameter: long-term treatment of the child with simple febrile seizures. *Pediatrics*. 1999;103:1307–1309
- Growing Up With Epilepsy*. (an educational resource on childhood epilepsy created by the MGH pediatric epilepsy program in collaboration with the WBGH Educational Foundation). Available at: www.massgeneral.org/childhoodepilepsy
- Hirtz D, Ashwal S, Berg A, et al. Report of the Quality Standards Subcommittee of the American Academy of Neurology, the Child Neurology Society, and the American Epilepsy Society. Practice parameter: evaluating a first nonfebrile seizure in children. *Neurology*. 2000;55:616–623
- Hirtz D, Berg A, Bettis D, et al. Report of the Quality Standards Subcommittee of the American Academy of Neurology and the Practice Committee of the Child Neurology Society. Practice parameter: treatment of the child with a first unprovoked seizure. *Neurology*. 2003;60:166–175
- Provisional Committee on Quality Improvement, Subcommittee on Febrile Seizures. Practice parameter: the neurodiagnostic evaluation of the child with a first simple febrile seizure. *Pediatrics*. 1996;97:769–775
- Sharma S, Riviello JJ, Harper MB, et al. The role of emergent neuroimaging in children with new-onset afebrile seizures. *Pediatrics*. 2003;111:1–5

PIR Quiz

Quiz also available online at www.pedsinreview.org.

1. Which of the following is the *most* likely cause of symptomatic epilepsy in the adolescent population?
 - A. Cortical dysplasia.
 - B. Genetic syndromes.
 - C. Head trauma.
 - D. Hypoxic-ischemic encephalopathy.
 - E. Pyridoxine deficiency.
2. A 10-year-old boy is brought to your clinic because his mother is worried about seizures. She reports that for the last few weeks, he calls out to wake her frequently at night because of numbness of one side of his mouth associated with twitching and drooling. He remains conscious during the episodes, and they last approximately 2 minutes. His neurologic examination and brain magnetic resonance imaging results are normal. Of the following, which is the *most* likely finding on electroencephalography?
 - A. Centrottemporal high-voltage spike discharges.
 - B. Continuous focal spike discharges that spread to a mirror focus on the other side.
 - C. High-amplitude waves and multifocal spikes.
 - D. Normal findings.
 - E. 3-Hz spike-and-wave discharges.
3. A 5-month-old girl is brought to the emergency department because of jerking episodes for the past 2 weeks. Her mother reports bilateral jerking of the arms and neck flexion that last for a few seconds. The episodes are more frequent in the morning right after she wakes up. She seems fine between episodes, with normal activity and appetite. The infant appears well, has normal findings on physical examination, and has no skin lesions. Electroencephalography shows a disorganized background with high-amplitude waves and multifocal spikes. Of the following, the *most* likely diagnosis is:
 - A. Absence epilepsy.
 - B. Benign myoclonus of infancy.
 - C. Frontal lobe epilepsy.
 - D. Infantile spasms.
 - E. Lennox Gastaut syndrome.
4. A 4-year-old girl who has a family history of epilepsy comes to the neurology clinic with a history of spells for 5 months. Her mother reports that the episodes consist of unilateral arm jerking for a few seconds but no loss of consciousness. The girl often reports feeling afraid before the episodes start. Findings on her neurologic examination are normal. Of the following, the *most* likely diagnosis is:
 - A. Absence epilepsy.
 - B. Benign rolandic epilepsy.
 - C. Generalized idiopathic epilepsy.
 - D. Juvenile myoclonic epilepsy.
 - E. Temporal lobe epilepsy.

Seizures in Children : Determining the Variation

Philippe Major and Elizabeth A. Thiele

Pediatrics in Review 2007;28;363

DOI: 10.1542/pir.28-10-363

Updated Information & Services

including high resolution figures, can be found at:
<http://pedsinreview.aappublications.org/content/28/10/363>

References

This article cites 7 articles, 5 of which you can access for free at:

<http://pedsinreview.aappublications.org/content/28/10/363#BIBL>

Subspecialty Collections

This article, along with others on similar topics, appears in the following collection(s):

Neurologic Disorders

http://pedsinreview.aappublications.org/cgi/collection/neurologic_disorders

Permissions & Licensing

Information about reproducing this article in parts (figures, tables) or in its entirety can be found online at:
</site/misc/Permissions.xhtml>

Reprints

Information about ordering reprints can be found online:
</site/misc/reprints.xhtml>

American Academy of Pediatrics

DEDICATED TO THE HEALTH OF ALL CHILDREN™

