



## Review

## What makes a simple partial seizure complex?

Andrea E. Cavanna<sup>a,b,\*</sup>, Hugh Rickards<sup>a</sup>, Fizzah Ali<sup>a</sup><sup>a</sup> The Michael Trimble Neuropsychiatry Research Group, Department of Neuropsychiatry, University of Birmingham and BSMHFT, Birmingham, UK<sup>b</sup> National Hospital for Neurology and Neurosurgery, Institute of Neurology, and UCL, London, UK

## ARTICLE INFO

## Article history:

Received 26 September 2011

Accepted 2 October 2011

Available online 13 November 2011

## Keywords:

Epilepsy

Complex partial seizures

Consciousness

Experiential phenomena

Limbic system

## ABSTRACT

The assessment of ictal consciousness has been the landmark criterion for the differentiation between simple and complex partial seizures over the last three decades. After review of the historical development of the concept of “complex partial seizure,” the difficulties surrounding the simple versus complex dichotomy are addressed from theoretical, phenomenological, and neurophysiological standpoints. With respect to consciousness, careful analysis of ictal semiology shows that both the general level of vigilance and the specific contents of the conscious state can be selectively involved during partial seizures. Moreover, recent neuroimaging findings, coupled with classic electrophysiological studies, suggest that the neural substrate of ictal alterations of consciousness is twofold: focal hyperactivity in the limbic structures generates the complex psychic phenomena responsible for the altered contents of consciousness, and secondary disruption of the network involving the thalamus and the frontoparietal association cortices affects the level of awareness. These data, along with the localization information they provide, should be taken into account in the formulation of new criteria for the classification of seizures with focal onset.

© 2011 Elsevier Inc. All rights reserved.

## 1. Introduction

International classification systems indicate our clinical and theoretical understanding of disease. Categorical schemes also function as a scaffold to assure the diagnostician; however, these systems need regular review alongside scientific advance as they are imperfect and can have an impact on the experimental and clinical approach of future generations.

In the field of epileptology, recent advances in imaging, monitoring, and molecular biology have led to significant changes in our understanding and categorization of seizure semiology. Researchers of each era combined the available diagnostic techniques with their theoretical and philosophical slants to manufacture their own compatible classification systems in accordance with knowledge of seizure mechanisms. Early records on the epilepsies, for instance, rely heavily on astute observation and witness accounts; consequently the earliest classifications were based primarily on the appreciation of ictal symptomatology. Initial observations discriminated “nonconvulsive” seizures as epileptic activity distinct from “convulsive” attacks. The ensuing major division between partial (focal) and generalized epilepsies formed the basis of the first Commission on Classification and Terminology of the International League Against Epilepsy (ILAE) classification system in 1970 [1].

Recent decades have witnessed a renewed interest in the concept of consciousness. Despite a catalogue of definitions crossing a host of academic domains, consciousness is of indisputed clinical relevance. In particular, alterations in consciousness have been long considered a signpost of seizure activity [2]. Likewise, the reversible and heterogeneous nature of ictal impairment in consciousness functions as a model for exploration of the brain mechanisms of altered conscious states. Although changes in the conscious states are a central part of epilepsy, the essential qualities remain to be clarified, despite a mass of contributions in this area. As a result, this key feature of epilepsy phenomenology has been incorporated into seizure classification relatively recently; the revised classification of 1981 applied the impairment of consciousness as a criterion for the differentiation between simple and complex partial seizures [3]. Defining consciousness as the patient’s responsiveness during the ictal state goes some way in enveloping various shortcomings of the classification. Recent years have permitted the use of sophisticated techniques in conjunction with direct observation of ictal behavior and accounts of the first-person perspective. Modern investigators therefore have the benefit of detailed description of alterations in ictal conscious state according to seizure type with synchronized knowledge of the underlying neuroanatomical foundation.

In this article, the evolution of the concept of “complex partial seizure” as part of a wider classification system is reviewed. Particular reference is made to the impact of a greater understanding of ictal consciousness at the conceptual and neurobiological levels on classification systems, with special focus on the simple versus complex dichotomy of partial seizures.

\* Corresponding author at: Department of Neuropsychiatry, University of Birmingham and BSMHFT, The Barberry National Centre for Mental Health, 25 Vincent Drive, Birmingham B152FG, UK.

E-mail address: [a.cavanna@ion.ucl.ac.uk](mailto:a.cavanna@ion.ucl.ac.uk) (A.E. Cavanna).

## 2. The concept of “complex partial seizure”: A historical perspective

Traditionally, two clinical features have been inextricably linked with epileptic seizures: convulsions and alterations of consciousness. A chronological review of the metamorphosis of the classification system demonstrates the eventual progression from an initial crude dichotomy to the contemporary classification system. The latter is arguably flawed if scrutinized under the modern refined understanding encircling the concept of consciousness.

### 2.1. Generalized seizures versus partial seizures

The elementary division between generalized seizures (involving diffuse brain regions throughout both hemispheres) and partial seizures (involving focal brain regions or confined to one hemisphere) heralds from the Hippocratic writings *On the Sacred Disease*. Here, a dichotomy of manifestations is evident: bilateral tonic–clonic seizures (with reference to mouth foaming, loss of speech, choking, and leg kicking) versus unilateral convulsions. The mention of warnings preceding attacks suggests simple partial seizures advancing into secondarily generalized tonic–clonic seizures [4]. Among this multiplicity of epileptic nomenclature, the term *partial* perhaps ranks as that most associated with a change in significance over time. Prichard (1822) has been credited with first employing this term, synonymous with “local convulsion” and representative of only the phenotypical aspect of a seizure, that is, motor seizures involving only a part of the body [5]. Bright (1831) analytically appraised local against generalized cerebral activity, establishing a correlation between partial seizures and the finding of focal cortical lesions, further consolidating the partial versus generalized dichotomy with a solid neuropathological basis [6].

### 2.2. Consciousness as categorical discriminator

The 1981 ILAE classification system [3] generated a second duality within the partial versus generalized dichotomy: “loss” or “impairment” of consciousness is used as a major definitional criterion for differentiation of partial seizures. Simple partial seizures (SPS) imply preservation of consciousness, whereas complex partial seizures (CPS) are characterized by impaired consciousness. SPS may consist of purely motor, sensory, autonomic, or psychic alterations depending on the cortical locus implicated. Previously, the term *complex partial seizures* had been incorrectly synonymously used with temporal lobe seizures, as these events often originate in mesial temporal limbic structures [7]. However, ictal activity in a variety of cortical regions outside of the mesial temporal area can generate impairment of consciousness.

Hughlings-Jackson quoted Herpin extensively and credited the latter for the first description of the modern CPS, but remains the first to have recognized these seizures as a distinct entity [8,9]. Historically, Herpin in his posthumous work, *Des Accès Incomplets d'Épilepsie* (1867), compartmentalized epileptic events with preservation of consciousness as *vertiges*, differentiating from other seizures, *accès*, where consciousness is fully or partially spared, that is, the contemporary equivalent of SPS and CPS [4,10]. Descriptions of preserved consciousness during epileptic seizures can be traced back to a selection of cases featured in the *London Lancet* illustrated with the remark *unconsciousness is not an unvarying characteristic of epilepsia* [11], plus an ensuing article consolidating the findings authored by Hughes and Stevens in 1880 [12]. This discourse impacted patients on various levels: inclusion of such events as epileptic permitted treatment, as well as advancement of medical understanding. Yet even at the beginning of the last century, authors continued to cite loss of consciousness as an essential feature [13] or principal element of seizure semiology [14]. In 1872, Reynolds documented that the diagnosis of epilepsy could

not be formulated without loss of consciousness [15]. Three years later, Jewell, editor of the publication later known as *Journal of Nervous and Mental Diseases*, remarked that “loss of consciousness must always exist” [16]. Likewise, Hammond declared “every disease which is attended with unconsciousness and spasm is epilepsy ... regardless of aetiology” [17]. Most definitions of the time alluded to disordered neural function underlying the observed clinical phenomena. The College of General Practitioners defined epileptic episodes “where there is a disturbance of movement, feeling, behaviour or consciousness.” In 1960, Lennox and Lennox expanded this definition, considering epileptic seizures to be a spectrum “composed of one or more of the following recurrent and involuntary phenomena: (1) loss or derangement of consciousness or remembrance (amnesia); (2) excess or loss of muscle tone and movement; (3) alteration of sensation ...; (4) disturbance of the autonomic nervous system ...; (5) other psychic manifestations” [18]. This clinical classification distinguished between petit mal, convulsive, temporal lobe semiology, plus autonomic and unclassified seizures: these clinical pictures were typified by “automatic” seizures (characterized by automatisms, displaying various degrees of awareness), “subjective” seizures (characterized by psychic symptoms), and “tonic focal” seizures (with arrest of motion or mentation) consecutively. An earlier classification presented an alternative system, based on severity, ranging from disturbances manifest as alterations in mental state to only those events characterized by paroxysms of convulsion minus loss of consciousness. In between, states of general muscular contraction combined with mental obscuration of variable intensity exist. In 1861, Reynolds presented this classification as follows:

1. Loss of consciousness
2. Loss of consciousness with local tonic spasmodic movements
3. Loss of consciousness with general tonic and clonic movements
4. General or partial convulsions, without complete loss of consciousness [19]

### 2.3. Discriminating seizures through spectrum alterations in consciousness

The early period of modern epileptology was dominated by investigators defining epilepsy with the symptom of either absolute loss of consciousness or total preservation of consciousness. Hughlings-Jackson revolutionized the pathophysiological models of epilepsy, as the proper recognition of an epileptic state with alterations in the state of consciousness began with his writings. Hughlings-Jackson's ideas on consciousness, in particular his observations and model derived from the “dreamy state,” continue to be relevant today, revealing the multilayered concept and subjective nature of consciousness. The concept of “dreamy state,” synonymous with the modern understanding of the ictal and immediate postictal semiology of certain medial temporal seizures, was considered akin to a higher degree of consciousness or “double consciousness” encompassing elements such as feelings of familiarity as well as some loss of responsiveness. Patients during the ictal state were described as vaguely aware of ongoing events (one consciousness) while being preoccupied with an invading sense of familiarity (second consciousness) [20–22]. “Crude sensations” conversely represent a lower degree of consciousness. Initially considered to be in the spectrum of the dreamy state, albeit less elaborate, these symptoms included epigastric sensations, fear, noises, colored vision, and tastes as well as smells preceding seizures [21,23]. In association with “dreamy states,” Hughlings-Jackson also noted the presence of automatisms as well as “reminiscences” and “voluminous mental states” in some of his patients. Subsequent identification of temporal lobe pathology on autopsy led to the designation of the term *uncinate fits* for these seizures. The differing seizure semiologies provided him with a vision of a diverse range of underlying neuroanatomical epileptogenic foci: “although the functional

alteration is the same in all epilepsies, the seats of those functional alterations are various" [24,25]. Moreover, his writings detailing auditory auras were incorporated into his ideas on the "dreamy state," as these auditory symptoms were connected to postmortem findings of lesions in the superior temporal gyrus. Such illustrations of Hughlings-Jackson's designs on epilepsy contributed toward the understanding of ideas of brain function and localization, as well as demonstrated the progression of his insight into localization-related epilepsy [26]. The modern concept of epilepsy, specifically the definition of partial seizures, is consistent with Hughlings-Jackson's prediction on the classification of epilepsies: "we shall ultimately be able not only to speak of certain symptoms as constituting genuine epilepsy or some variety of it, but of these or those particular symptoms as pointing to a 'discharging lesion' of this or that particular part of cortex" [23].

#### 2.4. On the use of the consciousness criterion

The practical use of the impairment/loss of consciousness criterion (Table 1) as the key discriminator between SPS and CPS is problematic, mainly because of the clinical difficulty in assessing alterations in consciousness. Despite its previously perceived centrality to most seizure types [18], distinction of episodes through consciousness is increasingly perceived as a matter of practical and clinical convenience, rather than a scientifically inspired solution. Hughlings-Jackson's resounding belief, "It is not a distinction analogous to that made by a botanist, but analogous to one made by a gardener. It has no anatomical or physiological warrant" [27], in combination with the modern reevaluation of the neurobiology of consciousness, clearly demands the botanist to lend his anatomical knowledge to the gardener. In other words, it is now necessary to effectively prune the epileptic seizure taxonomy with neuroanatomical foundations. The ILAE classification system of 1981 proved to be reasonably user-friendly and undeniably facilitated global clinical and research communication on epilepsy through a universally acceptable language. One of the main limitations of this seizure classification is the lack of reference to the anatomical origin of symptoms, and thus it harbors the potential for conceptual change. It has been argued that the current method of distinction between SPS and CPS may be reviewed in the light of detectable anatomical basis [28]. History provides several examples of efforts toward an anatomically based classification system. Hughlings-Jackson first observed that the "dreamy state" and

automatisms correlated with the uncinate region and related temporal areas [9,23]. Penfield and Jasper's investigations of patients with focal cortical lesions revealed the variable expressions of the seizure depending on ictal origin and extent of propagation of the epileptiform discharge [29]. In 1954, Gastaut offered the combination of age and etiology, as well as clinical and electroencephalographic evidence for anatomical substrates, as the basis for a comprehensive seizure classification [30]. A reevaluation of the classification would recognize associations between ictal semiology and cerebral regions or systems involved in seizure generation and corresponding ictal phenomena. An amalgamation of electroencephalographic studies and neuroimaging findings, as well as pathological analysis of structural lesions, would contribute in evidencing such associations [30]. The last few decades of research, with the advent of sophisticated functional neuroimaging and electrophysiological techniques (and their combined use), have witnessed an unprecedented acceleration in our understanding of the brain-behavior correlates underpinning the different types of epileptic seizures.

### 3. The neural correlates of ictal consciousness

This section provides a brief review of the neural activity underlying ictal impairment of the normal conscious state. Changes in both the subjective contents and the level of consciousness during partial seizures are considered, in the context of their significance for the simple versus complex seizure classification dichotomy (Table 2).

#### 3.1. Altered contents of consciousness

By definition, partial seizures originate in particular parts of the cortex, remaining either locally confined or propagating to other regions. Consequently, the clinical manifestations of these seizures depend on the seizure origin, extent of propagation, and seizure duration. Regardless of whether a seizure is classified as SPS or CPS, alterations in the contents are related to functional alterations in shared neuroanatomical structures within the temporal lobes (Fig. 1).

One of Hughlings-Jackson's final observations uncovered the post-mortem localization of the "uncinate group of fits," correlating with the clinical dreamy state, to the medial temporal region [9,22]. Early experiments on local electrical stimulation of the human temporal cortex during epilepsy surgery elicited specific changes in

**Table 1**

Consciousness as a classificatory criterion for partial seizures: A comparison between the 1970 and 1981 International Classification of Epileptic Seizures (ICES) systems.

| 1970 ICES                                                                                                                                                                                                                                                                                                                                                                                                                                                                                                                                                                                                | 1981 ICES                                                                                                                                                                                                                                                                                                                                                                                                                                                                                                                |
|----------------------------------------------------------------------------------------------------------------------------------------------------------------------------------------------------------------------------------------------------------------------------------------------------------------------------------------------------------------------------------------------------------------------------------------------------------------------------------------------------------------------------------------------------------------------------------------------------------|--------------------------------------------------------------------------------------------------------------------------------------------------------------------------------------------------------------------------------------------------------------------------------------------------------------------------------------------------------------------------------------------------------------------------------------------------------------------------------------------------------------------------|
| Partial seizures with elementary symptomatology (generally without impairment of consciousness):<br>With motor symptoms<br>With special sensory or somatosensory symptoms<br>With autonomic symptoms<br>(Compound forms)                                                                                                                                                                                                                                                                                                                                                                                 | Simple partial seizures (consciousness not impaired):<br><br>With motor signs<br>With somatosensory or special-sensory symptoms<br>With autonomic symptoms or signs<br>With psychic symptoms<br>Associated ictal EEG pattern: "local contralateral discharge starting over the corresponding area of cortical representation (not always recorded on the scalp)"<br>Associated interictal EEG pattern: "local contralateral discharge"                                                                                   |
| Partial seizures with complex symptomatology <sup>a</sup> (generally with impairment of consciousness; may sometimes begin with elementary symptomatology):<br>With impaired consciousness only<br>With affective symptomatology<br>With cognitive symptomatology<br>With dysmnestic disturbances (conscious amnesia, "déjà vu," "déjà vécu")<br>With ideational disturbances (including "forced thinking", dreamy state)<br>With "psychosensory" symptomatology<br>With "psychomotor" symptomatology (automatisms)<br>Illusions (e.g., macropsia, metamorphopsia)<br>Hallucinations<br>(Compound forms) | Complex partial seizures (with impairment of consciousness; may sometimes begin with simple symptomatology):<br>Simple partial onset followed by impairment of consciousness<br><br>With impairment of consciousness at onset<br><br>Associated ictal EEG pattern: "unilateral or, frequently, bilateral discharge, diffuse or focal in temporal or frontotemporal regions"<br><br>Associated interictal EEG pattern: "unilateral or bilateral generally asynchronous focus; usually in the temporal or frontal regions" |

<sup>a</sup> Complex (implying a joining together of elementary or (and/or) complex symptoms) versus elementary implies an organized, high-level cerebral activity.

**Table 2**

Proposed neural correlates underlying equivalent alterations in level of awareness and subjective contents of consciousness during partial seizures.

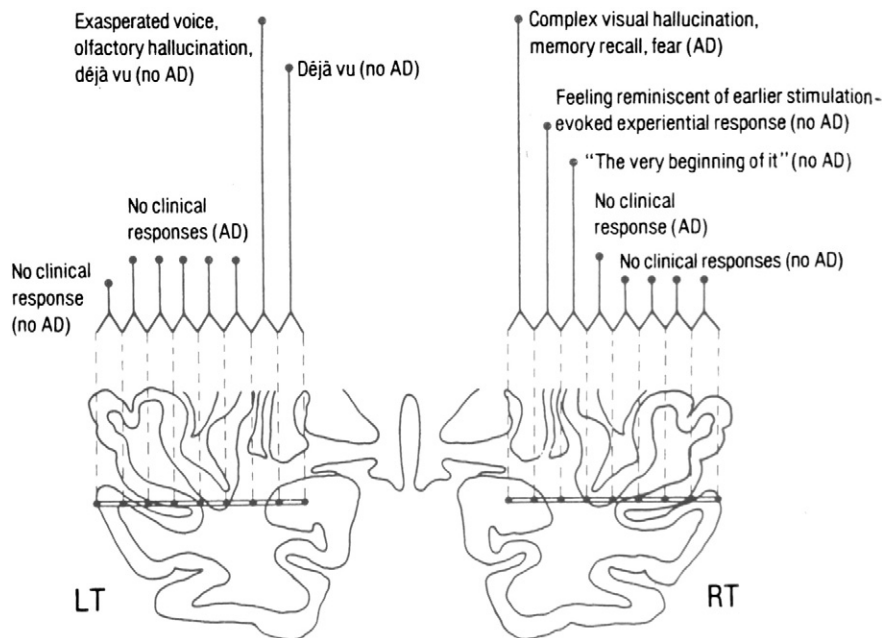
|                      | Level                                                                                                                             | Contents                                                                                     |
|----------------------|-----------------------------------------------------------------------------------------------------------------------------------|----------------------------------------------------------------------------------------------|
| Degree of alteration | Impaired responsiveness<br>Unresponsiveness                                                                                       | Psychic symptoms<br>"Zombie-like" states                                                     |
| Neural correlates    | Discharge spreading to subcortical structures with subsequent involvement of bilateral frontoparietal association cortex networks | Seizures with focus in the medial temporal lobe or involving medial temporal lobe structures |

consciousness content [29,31]. Similarly, the conscious recall of past events requires the integrity of medial temporal lobe structures [32,33]. Hughlings-Jackson's early observations on "psychical states which are much more elaborate than crude sensations" [22] illustrated that local epileptic activity arising from the temporal lobe can spawn experiential phenomena. Experiential phenomena are typically brief, and coincide with psychic epileptic aura or with the onset of a CPS [34], and encompass a variety of subjective experiences including affective, mnemonic, and composite perceptual phenomena. These psychic or experiential phenomena have been elicited by both experimental electrical stimulations and clinical seizures originating from the medial temporal lobe [35]. The affective elements of experiential phenomena (epileptic "qualia") include both unpleasant and pleasant ictal emotions, as well as symptoms of depersonalization and derealization. In particular, involvement of the amygdala and other limbic structures has been considered responsible for generating this affective element. Specific alterations of experience may also feature as an isolated phenomenon in SPS with experiential phenomena [36]. The majority of automatisms are not open to simple anatomic interpretation; however, they do appear to have in common a discharge involving areas of the limbic system [37]. Previous findings have yielded contradicting data: although different studies have indicated that the analysis of the aura

type does not supply valuable lateralizing information [38–40], other work has implied that autonomic and psychic auras are more frequently associated with a right-sided focus [41].

Following Penfield's pioneering studies, Gloor's classic experiments on the stimulation of limbic structures in the temporal lobe in awake patients demonstrated that it is possible to artificially induce intense auras combining affective, mnemonic, and perceptive features [25] (Fig. 1). The multifaceted character of temporal lobe auras has been attributed to the mechanism that sets down the memory trace and couples it with its conceptual and affective components. The amygdala and hippocampus have been hypothesized as accountable for this pairing in conjunction with information fed in by the visual and auditory association areas. In 1990 Gloor suggested that information exists in a distributed manner, with limbic structures simply organizing storage and retrieval and the temporal lobes actually functioning as trigger points for memory [25,42]. Interestingly, in a single-photon-emission computed tomography (SPECT) study of CPS originating from the temporal lobe, development from epileptic aura to staring, automatisms, and dystonic postures was correlated with progression of hyperperfusion from ipsilateral temporal lobe to contralateral temporal lobe, insula, basal ganglia, and frontal lobe [43].

In comparison to the temporal lobe, the complex architecture of the cerebral cortex of the frontal lobe is less epileptogenic. Therefore, frontal lobe epilepsy not only poses as a less common clinical entity than temporal lobe epilepsy, but creates additional challenges from a consciousness perspective. The majority of frontal lobe seizure subtypes may be described as SPS, with typical features ranging from hemibody flailing or thrashing movements to motor aphasia and contraversive eye and head movements [44]. Although patients are unable to respond during the seizure, they are usually able to recollect commands offered during the seizure. Conversely, some prefrontal seizures can generate a swift loss of awareness, which is not surprising as the prefrontal cortex has connections with the dorsomedial thalamus and parietal and temporal cortices. It has been postulated that in both temporal and frontal lobe epilepsy, the thalamic



**Fig. 1.** Topographical distribution of responses obtained with stereotaxically implanted intracerebral depth electrodes in a 22-year-old patient with treatment-refractory temporal lobe epilepsy. Electrical stimulation was applied to adjacent pairs of contacts along the rows of electrodes in the left and right temporal lobes, from the amygdala (most internal contact) to the temporal neocortex (most external contact). The height of the vertical lines is proportional to the degree of intensity ("vividness") of the subjective experience elicited in the patient by the stimulation. AD, afterdischarge; LT, left temporal lobe; RT, right temporal lobe. Reproduced with permission from Gloor et al. [33].

propagation of discharge plays a key role in determining the alteration in awareness [45,46].

### 3.2. Impaired level of consciousness

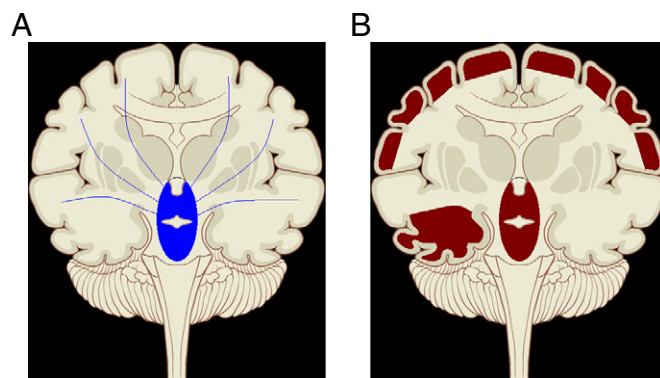
The integrity of the brainstem and at least one cerebral hemisphere has been long noted as essential for the preservation of the level of consciousness (arousal). Widespread, bilateral cerebral dysfunction or brainstem failure determines impairment of consciousness, with the depth of decrement being proportional to the extent of the insult [47,48]. The involvement of the ascending activating ponto-meso-diencephalic reticular formation, in conjunction with its thalamic targets, has been identified as integral to the neural basis of arousal [49]. Further work over the last few years has focused on the role of thalamocortical networks [50]. Central nervous system lesions involving the reticular formation and/or nonspecific thalamic nuclei (nucleus reticularis and intralaminar nuclei) can result in bilateral cortical dysfunction, in turn leading to major impairment in the level of consciousness to the extent, for instance, of coma and persistent and vegetative state [51,52]. Functional neuroimaging findings have consistently demonstrated complete loss of consciousness in association with ictal disruption of thalamocortical network activity due to propagation of the epileptiform discharge to subcortical structures [53]. Similar protocols have identified selective thalamic hypometabolism in slow wave sleep [54,55], hypnotic states [56,57], and drug-induced anesthesia [58,59], further verifying the upper brainstem-diencephalic activating system as the neuroanatomical correlate of the general level of arousal [60].

In some CPS, the propagation of epileptic discharge from a medial temporal lobe focus to subcortical structures results in a significant impairment in the level of consciousness over the late ictal and immediate postictal phase. The same subcortical structures are responsible for the complete loss of consciousness associated with generalized tonic-clonic and absence seizures, whereby involvement of the bilateral thalamus and upper brainstem produces a selective disruption of frontoparietal association cortex activity [48]. Functional imaging studies have additionally delved into the neurobiological changes accompanying CPS. Interictal and ictal SPECT studies in patients with hippocampal sclerosis showed ictal hyperperfusion in the ipsilateral temporal lobe, middle frontal and precentral gyrus, and bilateral occipital lobes, whereas the remaining portions of the frontal lobes, ipsilateral precuneus, and contralateral posterior cerebellum demonstrated hypoperfusion [61]. Analysis of ictal cerebral blood flow changes in CPS of temporal lobe origin also demonstrated functional activation in the temporal lobe preceding increased activity in midline subcortical structures bilaterally, including the upper brainstem and mediodorsal thalamus [62]. Additionally, bilateral hypometabolism in the frontal and parietal association cortices (orbital frontal, anterior cingulate, lateral prefrontal and lateral parietal cortex) was evident. On the contrary, SPS of temporal lobe origin are accompanied by less florid changes, limited largely to the temporal lobe and without the extensive functional impairment of the frontoparietal association cortices [63]. Such findings indicate that impairment of consciousness in temporal lobe seizures is related to focal abnormal activity in the temporal lobe and subcortical networks connected to widespread impaired function of the association cortex. The current neuroimaging evidence on the mechanisms of the ictal alterations of the level of consciousness in partial seizures can therefore be summarized as follows: (1) In the early phase of the temporal lobe seizure the greatest increase in cerebral blood flow is noted in the temporal lobe. (2) In SPS, these physiological changes are limited largely to the boundaries of the temporal lobe with “sparing” of consciousness, in the traditional sense. (3) In CPS, conversely, the epileptiform discharges propagate extensively, such that a decline in blood flow is noted in the frontoparietal cortex alongside increases in the medial diencephalon and

upper brainstem; ultimately this interferes with maintenance of consciousness, which is especially prominent late in the ictal phase and in the early postictal period [62]. Interestingly, abnormal increases in activity in the frontoparietal association cortex and subcortical structures result in complete loss of consciousness in generalized seizures, whereas decreases in the same regions may produce impairment of consciousness in CPS [63].

Converging intracranial electroencephalographic findings from CPS of temporal lobe origin demonstrate significant slowing in bilateral frontal and parietal association cortices, particularly pronounced in the late ictal phase and extending into the early postictal period. These observations are in accordance with the notion that focal seizures originating in the medial temporal lobe extend to subcortical structures (medial diencephalon, pontomesencephalic reticular formation) and interfere with their normal activating function, indirectly causing inhibition of nonseizing regions of the frontal and parietal association cortex [64]. This selective impairment of cortical function seems essential to the loss of awareness and wider behavioral alterations in temporal lobe epilepsy. This “network inhibition hypothesis” (Fig. 2) has recently been proposed to replace the enduring notion of a critical load of cerebral tissue implicated in seizure propagation generating impairment of consciousness, by providing a better account for the impairment in consciousness reported in the late ictal and immediate postictal phases of some CPS [65]. Evidence from preliminary functional MRI with simultaneous EEG recordings (EEG-fMRI) links the transient and complete loss of consciousness during generalized seizures with involvement of selective networks and sparing of others [66,67]. Bilateral thalamic activation and cortical signal decrease have been noted, in particular, in a characteristic distribution involving areas most active during conscious rest, such as the lateral parietal, prefrontal, and midline precuneus/posterior cingulate cortex. The “default mode of brain function” hypothesis deems these areas to demonstrate transient deactivations whenever healthy individuals are investigated in conditions of reduced vigilance, such as deep sleep, drug-induced general anaesthesia, and vegetative states [68]. Evidence indicates these “default mode” areas constitute an integral component of neural mechanisms maintaining the general level of consciousness.

The emerging picture suggests that the frontoparietal association cortex can play a role in both the level and the contents of consciousness, as a conscious perception is a complex phenomenon associated with extensive brain activity. In particular, frontoparietal activity has been noted in studies on conscious visual perception, working memory, episodic memory retrieval, as well as attention. A recent comprehensive review tied the four functions together through study of



**Fig. 2.** Norden and Blumenfeld's “network inhibition hypothesis.” (A) Normal state: Normal consciousness is maintained through interaction between the upper brainstem-diencephalic and the cerebral cortex. (B) Focal seizure: Propagation of seizure activity from the mesial temporal lobe disrupts the activating functions of the midline subcortical structures. Resulting reduced activity of the frontoparietal association cortex bilaterally results in loss of consciousness.

anatomically overlapping activation patterns [69]. Visual awareness is perhaps the most extensively studied conscious experience: although the ventral visual cortex is implicated in visual perception, the additional involvement of the parietal and prefrontal areas in producing visual awareness has been noted [70–72]. Visual awareness arguably requires both “phenomenal” and “access” consciousness [73], where phenomenal consciousness equates to the subjective element of experience, whereas access consciousness refers to the control of experience through reasoning or action. The distinction between phenomenal and access consciousness discussed above bears importance when considering the role of the frontoparietal regions in conscious perception. Phenomenal consciousness is likely to be associated primarily with activation of the sensory and limbic areas, whereas access consciousness may require the involvement of the frontoparietal associative areas, a secondary process dependent on the effect of earlier perceptual processing [72]. Whereas primary sensory areas of the brain may be responsible for low levels of integration, common frontoparietal activations associated with working memory, episodic memory retrieval, conscious perception, and attention represent a high level of integration, which poses as a prerequisite for numerous cognitive demands [69]. Working memory and episodic memory, as well as visual awareness and attention, share common activity patterns in dorsolateral prefrontal and parietal cortex [74,75].

#### 4. Consciousness and seizure classification: Botanists or gardeners?

Progress in neurodiagnostic technology, deeper insight into neuronal mechanisms of epilepsy, as well as some clarification on the concept of consciousness have considerably enhanced our understanding of seizures since the adoption of the current International Classification of Epileptic Seizures (ICES). Despite universal acceptance and extensive clinical use, the ICES is not free of controversial points. Although critics have argued that “from a heuristic point of view, using the concept of ‘consciousness’ as a feature in studies in which one attempts to understand what is going on in the brain during the course of a seizure leads nowhere” [2], failure to incorporate localization information based on the assessment of the level and content of consciousness features poses as a modern shortcoming. Moreover, the division of “simple” and “complex” focal seizures presents some difficulties, particularly in light of the bidimensional model of consciousness.

The focus on both electrophysiological and behavioral features in the 1981 classification resulted from the fact that knowledge on underlying seizure mechanisms at the time was considered inadequate to generate anything more than a wholly phenomenological approach [28,76]. Likewise, the more recent introduction of a seizure classification based entirely on epileptic semiology by Luders, alongside a syndrome classification informed by all available clinical information [77], fell short of fully integrating consciousness within the wider picture. This latter classification was rather perceived as a “descriptive terminology for clinical ictal events” with greater use in pre-surgical evaluations, whereby accurate phenomenology is key to anatomical localization of epileptic loci [28]. Whereas Luders’ classification has been regarded as too complicated for general application, the 1981 ICES has been regarded as overly complicated for epidemiological purposes [78]. Recent findings from invasive clinical studies in epilepsy surgery centers, advancement in structural and functional neuroimaging, as well as experiments on chronic animal models have paved the way for a classification of seizures based on presumed pathophysiological and anatomical substrates [28]. However, the practical difficulties of incorporating consciousness into a revised classification must be noted. First, various seizures generate different ictal consciousness profiles. Second, as the concept of consciousness has proved difficult to define, reaching universal consensus on the

best terminology to define seizure-specific alterations in consciousness may prove troublesome. Consideration must be given to a number of practical aspects related to the assessment of ictal behaviors, for instance, to factors such as whether the report is an eyewitness account or a third-party narration, whether the event is incidentally observed in the physician’s office or through investigation by long-term video/EEG monitoring, whether the ictal features are constant or variable, and so on [79].

Most importantly, caution should be used when using the terms *simple* and *complex*. This dichotomy has previously incorrectly generated the assumption that impairment of consciousness has certain mechanistic implications linked to limbic system involvement in causing unresponsiveness [80]. Central to this is the previous usage of the term *complex partial seizures* for *temporal lobe seizures* in the 1970 classification of epileptic seizures [1]. Over the past two decades, exploration of the anatomical substrates of ictal semiology has implied that mechanisms of certain limbic seizures vary from those of neocortical seizures: as a result, the simple–complex dichotomy is progressively losing its original representation [80]. Converging lines of evidence from neuroimaging and neurophysiological investigations of seizure-induced alterations in the normal conscious state provide initial support for a classification system whereby data on neuroanatomical localization are associated with phenomenological descriptions. For example, the division of seizures into “neocortical” or “limbic” origin may be a more accurate description than the simple versus complex partial seizure dichotomy [81].

Hughlings-Jackson repeatedly makes reference to the botanist–gardener dichotomy as a metaphor for the epilepsy classification conundrum. The botanist (the scientist) requires a reliable categorization, whereas the clinician (the gardener) needs a reference catalogue for daily use [76]. This idea was expanded on in the chapter “On Classification and on Methods of Investigation” (1874), in which Hughlings-Jackson illustrated two types of classification systems. The first classification, described as “empirical,” was designed to allow the application of structured knowledge for practical purposes. The second classification, the “scientific” one, was intended to assist the organization of existing knowledge and guide further investigation [27,76]. The viewpoint that these classification types are mutually exclusive requires reconsideration, as it is crucial that a clinically appropriate classification both is based on and reflects the dynamic and available scientific information [82].

There are different reasons for incorporating consciousness into an improved classification system for epileptic seizures. The original inclusion of the consciousness criterion as a major differentiator between SPS and CPS stems from impact on patient daily living (including job and driving implications). It is therefore not surprising that impairment of consciousness during recurrent seizures has considerable influence on most items of the Epilepsy Foundation of America Concerns Index [53]. Moreover, ictal aggressive behaviors associated with a normal level of arousal but altered contents of consciousness can potentially have legal relevance [48,83]. Finally, acceptance of the “supervenience” theory, the notion that every change at the experiential level is accompanied by a corresponding alteration at the neural level, demands the recognition that subjective alterations such as those of consciousness must be associated with specific patterns of neurobiological activity [84,85]. Based on this premise, incorporating consciousness into the seizure classification system could be crucial to further enhance our understanding of the biological bases of epilepsy [86,87].

The ILAE Commission on Classification and Terminology has recently revised concepts, terminology, and approaches for classifying seizures and forms of epilepsy [88]. For focal seizures, the distinction between complex partial seizures and simple partial seizures was eliminated. However, it was clearly recognized that impairment of consciousness/awareness or other dyscognitive features, localization, and progression of ictal events can be of primary importance in the

evaluation of individual patients and for specific purposes, such as differential diagnosis of nonepileptic events from epileptic seizures, randomized trials, and surgery [88–90]. Significantly, nothing in this recommendation precluded describing focal seizures according to ictal responsiveness or other subjective features of consciousness.

This review has argued that defining consciousness as the patient's responsiveness during the ictal state can be deceptive, as, for example, both generalized seizures and complex partial seizures can be associated with ictal unresponsiveness. Previous work has shown the reliability of assessing seizure-induced changes in aspects of consciousness in accordance with the bidimensional model level-versus-content of consciousness [54,55,91], and such findings may be integrated into a modern classification system as a contributory feature in defining the seizure type. Specifically, it will be interesting to see whether the systematic analysis of ictal experiential phenomena will ever be incorporated into a diagnostic classification scheme: this will provide a good opportunity to improve our understanding of the brain mechanisms underlying the so far elusive subjective contents of consciousness [84,85,92,93].

## References

- [1] Gastaut H. Clinical and electroencephalographical classification of epileptic seizures. *Epilepsia* 1970;11:102–13.
- [2] Gloor P. Consciousness as a neurological concept in epileptology: a critical review. *Epilepsia* 1986;27:14–26.
- [3] Commission on Classification and Terminology of the International League Against Epilepsy. Proposal for revised clinical and electrographic classification of epileptic seizures. *Epilepsia* 1981;22:489–501.
- [4] Eadie MJ, Bladin PF. A disease once sacred: a history of the medical understanding of epilepsy. London: John Libbey; 2001.
- [5] Wolf P. Epileptic seizures and syndromes: terms and concepts. In: Wolf P, editor. *Epileptic seizures and syndromes*. London: John Libbey; 1994. p. 3–8.
- [6] Bright R. Diseases of the brain and nervous system. Reports of medical cases, Vol. 2. London: Longman, Brown, Green & Longmans; 1831.
- [7] Engel J, Schwartzkroin PA. What should be modeled. In: Pitkanen A, Schwartzkroin PA, Moshe SL, editors. *Models of seizures and epilepsy*. London: Elsevier Academic Press; 2006. p. 1–14.
- [8] Temkin O. The falling sickness: a history of epilepsy from the Greeks to the beginnings of modern neurology. Baltimore: Johns Hopkins Univ. Press; 1945. p. 324–7.
- [9] Hughlings-Jackson J, Stewart JP. Epileptic attacks with a warning of a crude sensation of smell and with the intellectual aura (dreamy state) in a patient who had symptoms pointing to gross organic disease of the right temporo-sphenoidal lobe. *Brain* 1899;22:534.
- [10] Lipson SE, Montes JA, Devinsky O. Epilepsy in *The Alienist and Neurologist*, 1880–1920. *Epilepsia* 2002;43:912–9.
- [11] Hughes CH. Clinical notes illustrative of consciousness in epilepsy. *Alien Neurol* 1881;2:236–9.
- [12] Hughes CH, Stevens CW. Apparently conscious epileptic automatism with a sequel of aphasia. *Alien Neurol* 1880;1:190–2.
- [13] Turner WA. *Epilepsy: a study of the idiopathic disease*. London: McMillan; 1907. p. 1.
- [14] Lennox WG, Cobb S. Epilepsy from the standpoint of physiology and treatment. *Medicine* 1928;7:105–290.
- [15] Reynolds R. Epilepsy. In: Reynolds JR, editor. *A system of medicine*, vol. 1. Philadelphia: H.C. Lea; 1872. p. 292.
- [16] Jewell J. The pathology of epilepsy. *Chicago J Nerv Ment Dis* 1875;2:1–18.
- [17] Hammond WA. Clinical lecture on epilepsy. *NY Med J* 1883;37:337–40.
- [18] Lennox WG, Lennox MA. *Epilepsy and related disorders*. Boston: Little, Brown; 1960.
- [19] Reynolds JR. Epilepsy: its symptoms, treatment and relation to other convulsive diseases. *Br Med J* 1861;2:609–12.
- [20] Hughlings-Jackson J. Remarks on dissolution of the nervous system as exemplified by certain post-epileptic conditions. In: Taylor J, editor. *The selected writings of John Hughlings-Jackson*, vol. 2. New York: Basic Books; 1958. p. 276–307.
- [21] Hughlings-Jackson J. Lectures on the diagnosis of epilepsy (Harveian Society). In: Taylor J, editor. *The selected writings of John Hughlings-Jackson*, vol. 1. New York: Basic Books; 1958. p. 276–307.
- [22] Hogan RE, Kaiboriboon K. The 'dreamy state': John Hughlings-Jackson's ideas of epilepsy and consciousness. *Am J Psychiatry* 2003;160:1740–7.
- [23] Hughlings-Jackson J. On a particular variety of epilepsy ('intellectual aura'), one case with symptoms of organic brain disease. *Brain* 1888;11:179–207.
- [24] Critchley M, Critchley EA. *John Hughlings Jackson: the father of English neurology*. Oxford: Oxford Univ. Press; 1998.
- [25] Kalamangalam GP. Epilepsy and the physical basis of consciousness. *Seizure* 2001;10:484–91.
- [26] Hogan RE, Kaiboriboon K. John Hughlings-Jackson's writings on the auditory aura and localization of the auditory cortex. *Epilepsia* 2004;45:834–7.
- [27] Taylor J. *The selected writings of John Hughlings Jackson*, vol. 2. New York: Basic Books; 1958. p. 204.
- [28] Engel Jr J. Classification of the International League Against Epilepsy: time for reappraisal. *Epilepsia* 1998;39:1014–7.
- [29] Penfield W, Jasper H. *Epilepsy and the functional anatomy of the human brain*. Boston: Little, Brown; 1954.
- [30] Gastaut H. *The epilepsies: electro-clinical correlations*. Springfield, IL: Charles C Thomas; 1954.
- [31] Jasper HH. Sensory information and conscious experience. *Adv Neurol* 1998;77:33–48.
- [32] Penfield W. The interpretive cortex: the stream of consciousness in the human brain can be electrically reactivated. *Science* 1959;129:1719–25.
- [33] Gloor P, Olivier A, Quesney LF, Andermann F, Horowitz S. The role of the limbic system in experiential phenomena of temporal lobe epilepsy. *Ann Neurol* 1982;12:129–44.
- [34] Alvarez-Silva S, Alvarez-Silva I, Alvarez-Rodriguez J, et al. Epileptic consciousness: concept and meaning of aura. *Epilepsy Behav* 2006;8:527–33.
- [35] Penfield W. *The mystery of the mind: a critical study of consciousness and the human brain*. Princeton, NJ: Princeton Univ. Press; 1975.
- [36] Cavanna AE, Monaco F. Brain mechanisms of altered consciousness states during epileptic seizures. *Nat Rev Neurol* 2009;3:1–10.
- [37] Wolf P. The classification of seizures and the epilepsies. In: Porter RJ, Morselli PL, editors. *The epilepsies*. London: Butterworths; 1985. p. 106–24.
- [38] Marks WJ, Laxer KD. Semiology of temporal lobe seizures: value in lateralizing the seizure focus. *Epilepsia* 1998;39:721–6.
- [39] Janati A, Nowack WJ, Dorsey S, Chesser MZ. Correlative study of interictal electroencephalogram and aura in complex partial seizures. *Epilepsia* 1990;31:41–6.
- [40] Palmieri A, Gloor P. The localizing value of auras in partial seizures: a prospective and retrospective study. *Neurology* 1992;42:801–8.
- [41] Guptka AK, Jeavons PM, Hughes RC, Covanis A. Aura in temporal lobe epilepsy: clinical and electroencephalographic correlation. *J Neurol Neurosurg Psychiatry* 1983;46:1079–83.
- [42] Gloor P. Experiential phenomena of temporal lobe epilepsy: facts and hypotheses. *Brain* 1990;113:1673–94.
- [43] Shin WC, Hong SB, Tae WS, Kim SE. Ictal hyperperfusion patterns according to the progression of temporal lobe seizures. *Neurology* 2002;58:373–80.
- [44] Jobst BC, Siegel AM, Thadani VM, Roberts W, Rhodes HC, Williamson PD. Intractable seizures of frontal lobe origin: clinical characteristics, localizing signs, and results of surgery. *Epilepsia* 2000;41:139–52.
- [45] Penfield W. Epilepsy, neurophysiology, and some brain mechanisms related to consciousness. In: Jasper HH, Ward AA, Pope A, editors. *Basic mechanisms of the epilepsies*. London: J & A Churchill; 1969. pp. 791–805.
- [46] Niedermeyer E. Frontal lobe epilepsy: the next frontier. *Clin Electroencephalogr* 1998;29:163–9.
- [47] Plum F, Posner JB. The diagnosis of stupor and coma. *Contemporary Neurology Series*. Philadelphia: Davis; 1980.
- [48] Porter RJ. Disorders of consciousness and associated complex behaviors. *Semin Neurol* 1991;11:110–7.
- [49] Moruzzi G, Magoun HW. Brain stem reticular formation and the activation of the EEG. *Electroencephalogr Clin Neurophysiol* 1949;1:455–73.
- [50] Smythies J. The functional neuroanatomy of awareness: with a focus on the role of various anatomical systems in the control of intermodal attention. *Conscious Cogn* 1997;6:455–81.
- [51] Giacino JT. Disorders of consciousness: differential diagnosis and neuropathological features. *Semin Neurol* 1997;17:105–11.
- [52] Laureys S, Owen AM, Schiff ND. Brain function in coma, vegetative state, and related disorders. *Lancet Neurol* 2004;3:537–46.
- [53] Lee KH, Meador KJ, Park YD, et al. Pathophysiology of altered consciousness during seizures: subtraction SPECT study. *Neurology* 2002;59:841–6.
- [54] Cavanna AE, Mula M, Servo S, et al. Measuring the level and content of consciousness during epileptic seizures: the Ictal Consciousness Inventory. *Epilepsy Behav* 2008;13:184–8.
- [55] Ali F, Rickards H, Bagary M, McCorry D, Cavanna AE. Ictal consciousness in epilepsy and non-epileptic attack disorder. *Epilepsy Behav* 2010;19:522–5.
- [56] Maquet P, Faymonville ME, Degueldre C, et al. Functional neuroanatomy of hypnotic state. *Biol Psychiatry* 1999;45:327–33.
- [57] Rainville P, Hofbauer RK, Bushnell MC, et al. Hypnosis modulates activity in brain structures involved in the regulation of consciousness. *J Cogn Neurosci* 2002;14:887–901.
- [58] Fiset P, Paus T, Daloze T, et al. Brain mechanisms of propofol-induced loss of consciousness. *J Neurosci* 1999;19:5506–13.
- [59] Alkire MT, Haier RJ, Fallon JH. Toward a unified theory of narcosis: brain imaging evidence for a thalamocortical switch as the neurophysiologic basis of anesthetic-induced unconsciousness. *Conscious Cogn* 2000;9:370–86.
- [60] Ortinski P, Meador KJ. Neuronal mechanisms of conscious awareness. *Arch Neurol* 2004;61:1017–20.
- [61] Van Paesschen W, Dupont P, Van Driel G, et al. SPECT perfusion changes during complex partial seizures in patients with hippocampal sclerosis. *Epilepsia* 2003;42:857–62.
- [62] Blumenfeld H, McNally KA, Vanderhill SD, et al. Positive and negative network correlations in temporal lobe epilepsy. *Cereb Cortex* 2004;14:892–902.
- [63] Blumenfeld H. Why do seizures cause loss of consciousness? *Neuroscientist* 2003;9:301–10.
- [64] Blumenfeld H, Rivera M, McNally KA, et al. Ictal neocortical slowing in temporal lobe epilepsy. *Neurology* 2004;63:1015–21.
- [65] Norden AD, Blumenfeld H. The role of subcortical structures in human epilepsy. *Epilepsy Behav* 2002;3:219–31.

- [66] Gotman J, Grova C, Bagshaw A, et al. Generalized epileptic discharges show thalamocortical activation and suspension of the default state of the brain. *Proc Am Acad Sci* 2006;102:15236–40.
- [67] Laufs H, Lengler U, Hamandi K, et al. Linking generalized spike-and-wave discharges and resting state brain activity by using EEG/fMRI in a patient with absence seizures. *Epilepsia* 2006;47:444–8.
- [68] Cavanna AE, Trimble MR. The precuneus: a review of its functional anatomy and behavioural correlates. *Brain* 2006;129:564–83.
- [69] Naghavi HR, Nyberg L. Common fronto-parietal activity in attention, memory, and consciousness: shared demands on integration? *Conscious Cogn* 2005;14:390–425.
- [70] Rees G, Kreiman G, Koch C. Neural correlates of consciousness in humans. *Nat Rev Neurosci* 2002;3:261–70.
- [71] Crick FC, Koch C. Are we aware of neural activity in primary visual cortex? *Nature* 1995;375:121–3.
- [72] Pins D, Ffychte D. The neural correlates of conscious vision. *Cereb Cortex* 2003;13:461–74.
- [73] Block N. On a confusion about a function of consciousness. In: Block N, Flanagan O, Guzeldere G, editors. *The nature of consciousness: philosophical debates*. Cambridge: MIT Press; 1997.
- [74] Baars B. *A cognitive theory of consciousness*. New York: Cambridge Univ. Press; 1988.
- [75] Baars B. The conscious access hypothesis: origins and recent evidence. *Trends Cogn Sci* 2002;6:47–52.
- [76] Wolf P. Of cabbages and kings: some considerations on classifications, diagnostic schemes, semiology, and concepts. *Epilepsia* 2003;44:1–4.
- [77] Lüders H, Acharya J, Baumgartner C, et al. A new epileptic seizure classification based exclusively on ictal semiology. *Acta Neurol Scand* 1999;99:137–41.
- [78] Engel Jr J. Reply to “Of cabbages and kings: some considerations on classifications, diagnostic schemes, semiology, and concepts”. *Epilepsia* 2003;44:4–6.
- [79] Mannan JB, Wiesmann UC. How accurate are witness descriptions of epileptic seizures? *Seizure* 2003;12:444–7.
- [80] Engel Jr J. A proposed diagnostic scheme for people with epileptic seizures and with epilepsy: report of the ILAE Task Force on Classification and Terminology. *Epilepsia* 2001;42:796–803.
- [81] Engel Jr J. Classification of epileptic disorders. *Epilepsia* 2001;42:316.
- [82] Berg AT, Blackstone NW. Reply to “Of cabbages and kings: some considerations on classifications, diagnostic schemes, semiology, and concepts”. *Epilepsia* 2003;44:8–12.
- [83] Gloor P. Mesial temporal sclerosis: historical background and an overview from a modern perspective. In: Luders HO, editor. *Epilepsy surgery*. New York: Raven; 1991. p. 689–703.
- [84] Monaco F, Mula M, Cavanna AE. Consciousness, epilepsy and emotional qualia. *Epilepsy Behav* 2005;7:150–60.
- [85] Monaco F, Mula M, Cavanna AE. The neurophilosophy of epileptic experiences. *Acta Neuropsychiatr* 2011;23:184–7.
- [86] Cavanna AE. Epilepsy and disorders of consciousness. *Behav Neurol* 2011;24:1.
- [87] Cavanna AE, Ali F. Brain mechanisms of impaired consciousness in epilepsy. In: Trimble MR, Schmitz B, editors. *Neuropsychiatry of epilepsy*. Cambridge: Cambridge Univ. Press; 2011. p. 209–20.
- [88] Berg AT, Berkovic SF, Brodie MJ, et al. Revised terminology and concepts for organization of seizures and epilepsies: report of the ILAE Commission on Classification and Terminology, 2005–2009. *Epilepsia* 2010;51:676–85.
- [89] Blume WT, Luders HO, Mizrahi E, et al. Glossary of ictal semiology. *Epilepsia* 2001;42:1212–8.
- [90] Berg AT, Blackstone NW. Concepts in classification and their relevance to epilepsy. *Epilepsy Res* 2006;70:11–9.
- [91] Johanson M, Revonsuo A, Chaplin J, Wedlund J-E. Level and contents of consciousness in connection with partial epileptic seizures. *Epilepsy Behav* 2003;4:279–85.
- [92] Cavanna AE, Ali F. Epilepsy: the quintessential pathology of consciousness. *Behav Neurol* 2011;24:3–10.
- [93] Cavanna AE, Shah S, Eddy CM, Williams A, Rickards H. Consciousness: a neurological perspective. *Behav Neurol* 2011;24:107–16.