

# Ingested and Aspirated Foreign Bodies

S. Sarah Green, MD\*

*\*Pediatrics, Oregon Health & Science University, Portland, OR.*

## Practice Gaps

1. Choking and the aspiration of food or other foreign objects remain causes of death and morbidity, particularly in the young child. Clinicians must learn to recognize and treat children who have foreign body aspirations.
2. Foreign body ingestion, particularly if undetected, can cause significant morbidity. Clinicians must be aware of the signs and symptoms as well as the management of foreign body ingestion.

## Objectives After completing this article, readers should be able to:

1. Describe the symptoms and treatment of an esophageal foreign body.
2. Know the signs and symptoms of an aspirated foreign body.
3. Understand how to evaluate a patient with suspected foreign body aspiration.
4. Delineate the possible radiographic manifestations of foreign body aspiration.
5. Explain how to differentiate between asthma and foreign body aspiration.
6. Know how to treat a patient with foreign body aspiration.

## INTRODUCTION

The accidental ingestion of food, toys, and small household objects is a common pediatric complaint, resulting in many clinic and emergency department visits as well as hospitalizations. Infants and toddlers explore their world by putting objects in their mouths, placing themselves at risk for having foreign bodies in the esophagus or respiratory tract. This article reviews the current literature for signs and symptoms of both foreign body ingestion and aspiration as well as recommendations for appropriate evaluation and management.

## FOREIGN BODY INGESTIONS

### Background

Data from the American Association of Poison Control National Poison Data System suggest that more than 110,000 ingested foreign bodies were reported in

**AUTHOR DISCLOSURE** Dr Green has disclosed no financial relationships relevant to this article. This commentary does not contain a discussion of an unapproved/investigative use of a commercial product/device.

2011, 85% of which occurred in the pediatric population. In that same year, 73% of foreign body ingestions occurred in children younger than age 5 years, with a peak incidence between 6 months and 3 years. (1)(2) A combination of normal developmental curiosity, immature swallowing coordination, and the absence of molars and premolars puts this age group at a higher risk for ingestion and aspiration. (3) Because children who have ingested a foreign body are often asymptomatic, the true incidence probably is higher.

Commonly ingested items include coins, magnets, small toys, buttons, bones, jewelry, and retained pieces of food. Coins are the most common esophageal foreign bodies, comprising up to 80% of items retained in the esophagus. (2)

Most objects that are ingested pass through the gastrointestinal (GI) tract without incident, but 10% to 20% require endoscopic removal; fewer than 1% require surgical intervention. (1) Conditions that predispose children to retaining the ingested object include anatomic and functional abnormalities of the esophagus and GI tract, such as strictures, rings, esophageal dysmotility, achalasia, dysphagia, and a history of esophageal atresia or tracheoesophageal fistula. (2) In addition, food impaction can be a presenting symptom of eosinophilic esophagitis and should be considered, particularly in older children and adolescents. (4)(5)(6)(7)

### Symptoms and Clinical Presentation

The symptoms of foreign body ingestion are highly variable and largely dependent on the size and shape of the object, its location, and the duration of time that it has been retained. Up to 50% of children with known foreign body ingestion are asymptomatic. (8) The most common area of the esophagus in which a foreign body is retained is the upper esophagus, at the upper esophageal sphincter. This is the site in 60% to 75% of cases. Approximately 10% to 20% of esophageal foreign bodies are found in the mid-esophagus, which is at the level of the aortic notch. The lower esophageal sphincter is the site for up to 20% of objects retained in the esophagus. (2)(9)(10) If an object is lodged in the esophagus, particularly in the upper esophagus, symptoms can include drooling, blood in saliva, gagging, or dysphagia. If the object is large enough or oriented so as to compress the trachea, patients may present with coughing, respiratory distress, or stridor. Some children complain of a pressure sensation or pain in the neck, throat, chest, or abdomen. Patients may have vomiting, refuse food, or be irritable. Esophageal perforation may be characterized by swelling or crepitus of the neck. (2)(9)(11)

Objects that travel past the esophagus generally do not cause symptoms, unless rare complications such as bowel perforation or obstruction occur. (11) If the object passes into

the stomach, the child is usually asymptomatic but may exhibit clinical manifestations if the esophagus was injured during transit of the object. Uncommon complications of objects that travel through the pylorus relate to bowel obstruction. Symptoms may include abdominal pain, distention, vomiting, and feeding intolerance. Bowel perforation is another rare but significant complication that is characterized by abdominal pain, distention, vomiting, and fever.

Subacute or chronic complications of an esophageal foreign body may include damaged mucosa or strictures of the esophagus, decreased oral intake, failure to thrive, or recurrent aspiration pneumonia. (11)

### Evaluation

Although many children who have ingested foreign bodies have normal findings on physical examination, a full evaluation should be completed. Initial assessment should include examining the airway and assessing breathing efforts. Stridor or wheezing could suggest obstruction, compression of the trachea, or a foreign body aspiration. The neck should be examined for swelling or crepitus, suggestive of possible esophageal perforation. Abdominal pain, rigidity, or rebound tenderness could be a sign of intestinal or colonic perforation.

After completing the physical examination, radiographs are often used for further evaluation of a patient with suspected foreign body ingestion. A history of ingestion or a choking episode is sufficient indication to proceed with radiographs because many children with confirmed foreign body ingestions are asymptomatic. Radiographs of the chest, including both posterior-anterior and lateral projections, can be helpful in locating some radiopaque objects but can miss objects that are above the thoracic inlet or past the pylorus. (2) Thus, radiographs of the neck and abdomen should also be considered. Even if objects are radiolucent, there may be indirect signs of foreign body, such as air fluid levels in the esophagus.

If patients are symptomatic and radiographs are negative, endoscopy can be used for diagnosis and treatment. Metal detectors have been found to be useful in some situations, such as finding aluminum soda can flip tops or following coins that are known to have passed to the stomach. This practice is cost-effective and requires no additional radiation, but use of a metal detector cannot rule out all metal items, such as button batteries or needles. (2)

Special consideration is required if the ingested item is suspected to be a battery or magnet, as discussed later in this article.

### Management

The treatment of an esophageal foreign body depends on what the object is, where it is located, and what symptoms

the child is having. Although most ingested items pass through the GI tract without incident, there are a few situations in which removing the object is indicated. Most objects found in the esophagus at the time of examination remain there and may need to be removed by endoscopy.

If clinical evaluation suggests esophageal perforation, a surgery consultation should be obtained. Similarly, if there is concern that a foreign body is causing intestinal obstruction or intestinal or colonic perforation, further evaluation with abdominal imaging and a surgical consultation is indicated.

Coins are the most commonly ingested foreign body. On anteroposterior chest radiograph, a coin in the esophagus appears as a circular disc ("en face"), while the lateral view demonstrates a thick line ("on edge"). In contrast, a coin in the trachea appears en face on the lateral view and on edge on the anteroposterior view. (12)(13) It is important to distinguish coins from button batteries because a button battery in the esophagus should be removed urgently. A button battery has a "halo sign" or double density at the periphery of the object en face. In contrast, a coin appears as a discoid object of uniform attenuation (Fig 1).

Most coins pass into the stomach and through the GI tract without incident. Symptomatic patients require intervention, but asymptomatic patients can be observed for 12 to 24 hours. (14) An asymptomatic patient who has a coin lodged in the esophagus can be monitored for clinical changes. Because up to two thirds of coins in the distal esophagus pass spontaneously into the stomach (75% within the first 6 to 10 hours), affected patients can be treated conservatively with repeat radiography in 12 to 24 hours. (15) Coins in the middle third of the esophagus have been reported to have a 43% spontaneous passage rate compared with a 14% rate for coins in the proximal esophagus. (2) Once in the stomach, coins usually pass without intervention and can be monitored by checking the stool for passage and with weekly radiographs, if indicated. If the coin does not pass through the stomach by 4 weeks or if the patient is symptomatic, removal by endoscopy should be considered.

Button batteries are now used in many items, including watches, hearing aids, key fobs, toys, and remote controls. Made of lithium, they possess a strong electrical charge and can react quickly with saliva. When lodged in the esophagus, button batteries pose a specific threat of rapid mucosal damage, necrosis, and perforation and should be immediately removed endoscopically (Fig 2). Once in the stomach, button batteries that are larger than 2 cm in diameter, are causing symptoms, or are present for more than 48 hours should be removed endoscopically. If they pass into the duodenum, most pass in fewer than 72 hours and do not require additional intervention. (9)(11)(14)

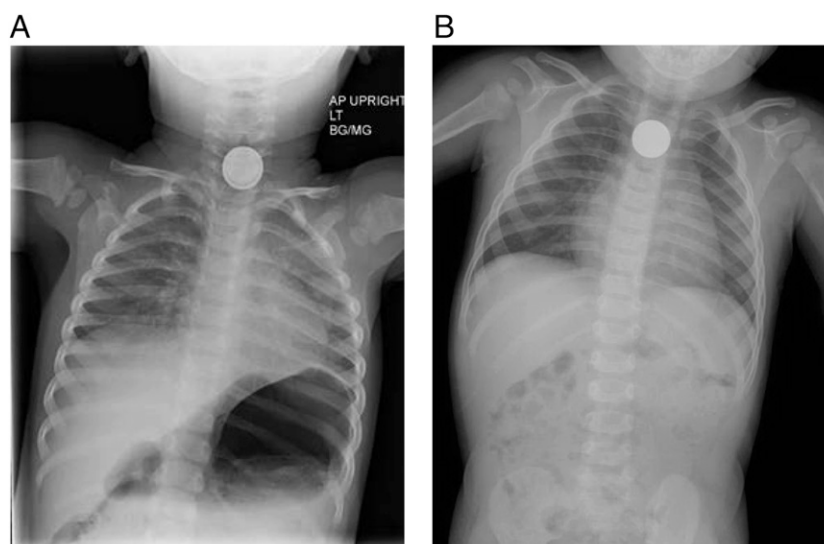
High-powered magnets have become a more common household item with the increasing popularity of magnetic toys. Complications of ingesting more than one magnet or a magnet and another metal object are now recognized. The attraction of two objects across the walls of multiple loops of bowel has led to ischemia, necrosis, perforation, and fistula. It is often difficult to determine the presence of one or more magnets on a single radiographic view and two views are recommended (Fig 3). In addition, space between magnets should be considered concerning for mural entrapment (Fig 4). (16) If there is concern for the ingestion of multiple magnets or radiographic evidence of gaps between magnets, endoscopy should be performed for exploration and removal. Although one magnet alone is unlikely to cause harm, the history of ingestion is often vague or absent. Imaging can help locate a magnet, but endoscopy should be considered because of the risk of morbidity and mortality. If magnets are out of endoscopic reach, surgical consultation is indicated. In addition, surgical consultation is urgently recommended if there are any clinical or radiographic signs of bowel entrapment or perforation and should be considered if magnets are failing to progress through the GI tract. (16)(17)(18)(19)

Sharp objects such as pins and needles also require special consideration. A sharp object in the esophagus should be removed regardless of symptoms because of the risk of perforation. (20) Most sharp objects in the stomach pass without incident, but there is an increased risk of complication. Thus, if endoscopic removal is feasible and safe, it should be considered. Sharp objects that have moved into the small intestine can be observed with serial radiographs and a low threshold for intervention if objects fail to progress after 3 days or if abdominal pain, vomiting, fever, hematemesis, or melena occur. (1)(11)(14)

Long objects, such as utensils and toothbrushes, and larger objects are another category for special consideration. In adults, objects larger than 2 × 5 cm have difficulty passing through the pylorus and objects longer than 6 cm are more likely to have difficulty passing through the duodenum; endoscopic removal is recommended in these situations. (14) Although no definitive guidelines exist for size limitations in smaller children, it has been suggested that objects greater than 1 × 3 cm or longer than 3 to 5 cm should be considered for endoscopic removal. (1)(11)

Adjunct therapies such as mineral oil, proteolytic enzymes, cathartics, laxatives, and glucagon are not recommended for treatment of any foreign body ingestion because they have the potential to cause additional harm. (2)(9)(21)

**Figure 1.** Chest radiography in a 14-month-old child who had a choking episode demonstrates a discoid foreign object in the esophagus (A). The “halo sign” or double density at the periphery of the object en face suggests that it is a button battery. This appearance must be carefully differentiated from that of a discoid object of uniform attenuation, which is more likely to be a coin (B, different patient).



## FOREIGN BODY ASPIRATION

### Background

Foreign body aspiration continues to be a significant concern in the pediatric population, accounting for more than 150 deaths annually in the United States as well as thousands of emergency department visits. (22) Young children are particularly vulnerable because of the narrowness of their airways and, thus, are at increased risk for significant airway obstruction. Children with developmental delay, anatomic abnormalities of their aerodigestive tract, or dysphagia are at further risk. The Centers for Disease Control and Prevention reported that 33% of choking episodes occur in infants and 75% in children younger than age 3 years. (23)

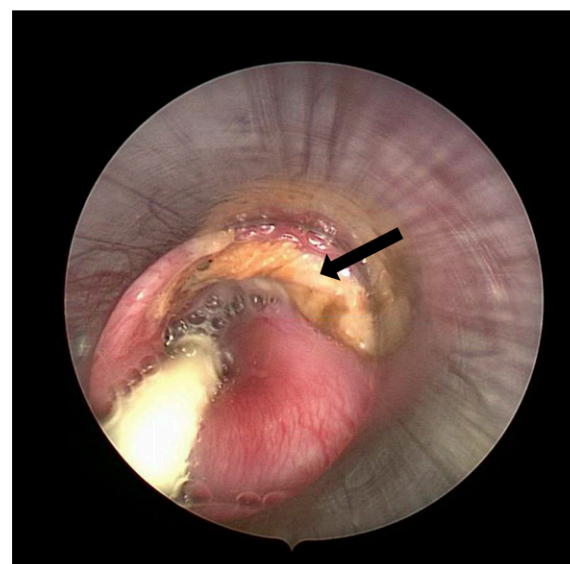
Although toys, coins, and small household items can be aspirated, food items comprise more than 50% of nonfatal choking episodes in the United States (Tables 1 and 2). High-risk foods include hot dogs, hard candies, nuts, seeds, raw fruits and vegetables, and gum. Among high-risk toys are latex balloons, marbles, balls, and spherical toys. (23) Qualities that make both toys and foods more dangerous include being small enough to fit in the airway, having a cylindrical shape, and being compressible, which can create a tight obstruction of the patient's airway. (24)

### Symptoms and Clinical Presentation

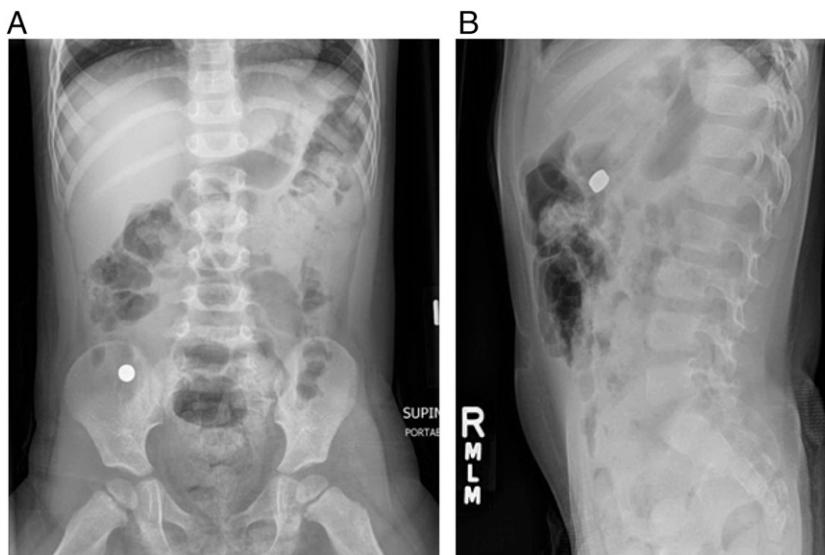
Just as there is great variability in the degree of airway obstruction when a foreign body is aspirated, so there is a wide spectrum of clinical presentations, ranging from asymptomatic to severe respiratory distress or asphyxiation. In addition, patients can present with symptoms that are vague and have significant overlap with other common

pediatric conditions, such as asthma, pneumonia, bronchiolitis, and upper respiratory tract infections.

The location, size, and quality of the foreign body contribute to the presenting symptoms. Laryngotracheal foreign bodies present with more acute respiratory distress, hoarseness, or stridor, while bronchial foreign bodies more commonly present with a wider variety of symptoms, including coughing, wheezing, dyspnea, decreased breath sounds, and fever. Cough has been found in 75% to 85% of patients and has a high sensitivity but low specificity.



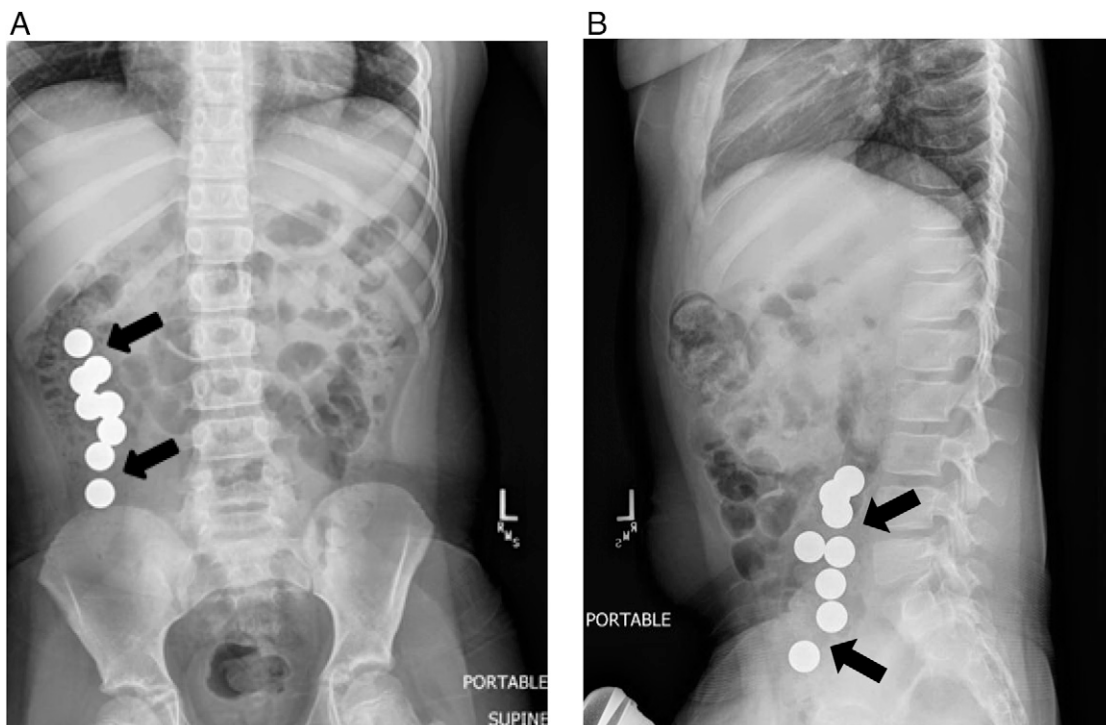
**Figure 2.** Esophagoscopy in the patient shown in Figure 1A revealed a button battery below the cricopharynx (not shown). The yellow discoloration in this image (arrow) corresponds to significant mucosal damage on nearly 180 degree of the anterior aspect of the esophagus. Image courtesy of Derek Lam, MD.



**Figure 3.** A 2-year-old child has a history of ingestion of two magnets, which are superimposed and simulate a single ingested object on anteroposterior abdominal radiograph (A). Two closely stacked magnets are distinguishable on an earlier radiograph obtained in the lateral projection (B).

History of choking is reported in 80% to 90% of children with foreign body aspiration, but the absence of choking does not rule out aspiration. (25) Differentiating between other common pediatric respiratory concerns (such as asthma) and foreign body aspiration can be difficult, making the history an important diagnostic tool.

A patient may be asymptomatic following an aspiration event or may present with persistent symptoms. A witnessed or reported episode of coughing and choking in association with an observed foreign object in the mouth should prompt consideration of bronchoscopy for further evaluation. (26)(27)(28)



**Figure 4.** Radiographs demonstrate multiple magnet ingestion in 9-year-old patient. Magnets of different shapes and sizes may simulate beads or other objects. Although the presence of bowel wall between magnets is not always evident on radiographs, spaces between magnets (arrows) should be considered highly suspicious for mural entrapment.



TABLE 1. Choking Hazard Household Items

Coins	Button batteries
Buttons	Magnets (refrigerator)
Toys with small parts	Magnets (high-powered magnets found in office supplies or toys)
Toys small enough to fit into a child's mouth	Rubber bands
Balloons	Marbles
Small hair bows and barrettes	Pen and marker caps

Adapted from AAP Healthy Children.org. <http://www.healthychildren.org/English/health-issues/injuries-emergencies/Pages/Choking-Prevention.aspx>.

If the diagnosis of aspirated foreign body has been delayed, patients may present with symptoms consistent with complications of retained foreign bodies, such as inflammation and infection. These patients may also be diagnosed with other respiratory illnesses, such as pneumonia, asthma, or viral infections, which may further delay diagnosis.

Thus, foreign body aspiration should be considered in children presenting with common diagnoses that do not respond to treatment as expected. Special consideration should be given to children with respiratory illnesses that are not following the expected clinical trajectory. A child with known asthma and persistent wheezing who is not improving with corticosteroids and bronchodilators should also be assessed for foreign body aspiration. A child with pneumonia who is not improving with antibiotics could be considered for further evaluation. Because foreign body aspiration can present with a wide variety of symptoms, especially if the diagnosis is delayed, evaluation for a foreign body should be considered when choking or aspiration is suspected.

TABLE 2. Choking Hazard Foods

Hot dogs/sausages	Whole grapes
Nuts	Hard or sticky candy
Seeds	Popcorn
Chunks of meat or cheese	Chunks of peanut butter
Chewing gum	Chunks of raw vegetables

Adapted from AAP Healthy Children.org. <http://www.healthychildren.org/English/health-issues/injuries-emergencies/Pages/Choking-Prevention.aspx>.

## Evaluation

Addressing airway concerns is the first priority. Supplemental oxygen should be offered as needed and clinicians should ensure that the patient is in an optimal place for further evaluation and management, with anesthesiology, otolaryngology, and pulmonology services available as needed.

Following evaluation for emergent airway concerns, a full physical examination should be completed. Although findings may be nonspecific, clinical manifestations of an aspirated foreign body can include stridor, wheezing, dyspnea, cough, unilateral decreased air entry, and fever.

After the history and physical examination, radiographs are often used for evaluation. However, they may not prove useful in the acute phase, particularly if the aspirated object is radio-lucent, and in the chronic phase, aspiration may be confused with a focal pneumonia. Some plain films may reveal a foreign body, but other findings, such as emphysema, atelectasis, or pneumonia, can be nonspecific. Although lateral decubitus and expiratory chest radiographs have been used in the past, studies suggest that they do not add significant diagnostic value. (29) Computed tomography scan and magnetic resonance imaging require coordination and possible sedation and may delay diagnosis. Thus, a high index of suspicion must be maintained if the clinical history is consistent with foreign body aspiration, even if radiographs are nondiagnostic, and early bronchoscopy should be considered. (30)

## Management

For life-threatening foreign body aspiration, the Heimlich maneuver in older children or back blows in infants should be attempted. If the patient is clinically stable, bronchoscopy can offer both diagnostic information and treatment.

Rigid bronchoscopy is the gold standard and the most commonly used tool for retrieval of foreign bodies, but flexible bronchoscopy has a diagnostic role. In emergent situations, where there is concern for tracheal foreign body, the airway should be managed and rigid bronchoscopy used. If the foreign body can be seen on radiography or clinical suspicion is very high, rigid bronchoscopy is recommended for both diagnosis and retrieval. Flexible bronchoscopy may be useful for diagnosis when there is suspicion but not a clear history or examination findings to suggest the presence of a foreign body. (31)

Long-term complications of retained aspirated foreign bodies include increased granulation tissue around the object, pneumonia, bronchiectasis, and atelectasis. (26) If there is evidence of an infection, a focal pneumonia, or abscess, empiric antibiotics with anaerobic coverage should be initiated and may be needed even after the foreign body is removed.

## PREVENTION

Education of caregivers is a key aspect of preventing both foreign body aspiration and ingestion. Guidance regarding age- and developmentally-appropriate toys is one preventive strategy. In addition, education about foods that are safe to give to children and in what form should be part of the anticipatory guidance given to parents during health supervision and other medical visits.

Non-food objects are regulated by federal legislation. The Child Safety Protection Act (CSPA) requires that the packages of toys and games that contain small parts, balls, marbles, or balloons have choking warning labels. The Federal Hazardous Substance Act uses the small-parts text fixture, a cylinder simulating a child's mouth and pharynx, to define a small object that requires a ban of the object for children younger than age 3 years and a hazard warning. The diameter is 3.17 cm (1.25 in), with a depth ranging from 2.54 cm (1 in) to 5.71 cm (2.25 in). In addition, the CSPA mandates balls to have a minimum diameter of 1.75 in if intended for children (23).

There are no similar regulations or legislation for food products, despite bills being presented to Congress. The American Academy of Pediatrics (AAP) recommends that hard candy and gum not be given to children younger than age 5 years and that raw vegetables and fruit be cut up into small pieces. In addition, the AAP recommends that children always be supervised while eating and that children be seated when eating—not running, walking, or lying down. Caregivers should also be familiar with choking-related rescue maneuvers (24).

## Summary

- Esophageal and aspirated foreign bodies have important clinical significance, and both should be considered carefully when the history or physical examination findings raise sufficient suspicion. The published evidence regarding the diagnosis and management of foreign body ingestion or aspiration is weighted disproportionately with observational

studies, case controls, expert opinion, and systematic reviews. Most of the publications would receive a categorization of C (observational studies including case-control and cohort design) and D (expert opinion, case reports, and clinical reasoning). One of the few prospective studies examining the diagnostic evaluation of foreign body aspiration in children could be considered level B evidence (randomized clinical trials, systematic reviews, or diagnostic studies with minor limitations). This study found that the medical history is the most important predictive part of the evaluation. There is evidence for considering bronchoscopy if there is significant history suggestive of foreign body aspiration, even in the setting of normal physical examination findings. (28)

- Most ingested foreign bodies spontaneously pass without incident. However, special attention should be paid to objects in the esophagus as well as to batteries and magnets. Based on a systematic review of the literature (level B evidence) and the potential for rapid and life-threatening damage, batteries in the esophagus should be removed immediately. (10) Other objects, such as coins, may be observed for passage in an asymptomatic patient. In addition, given the high risk of significant complications, ingestion of high-powered magnets should be quickly and carefully evaluated. Although single magnets are likely to pass without complication, multiple magnets or magnets ingested with other metal objects can cause significant damage and should be removed if there is any concern for mural entrapment, bowel perforation, or failure to progress. (10)(16)(17)(18)(19)
- Lastly, another systematic review of the literature (level B evidence) about the aspiration of food objects in children suggests that this is a significant public health concern with potentially devastating consequences. Despite clear legislation and regulation by the Consumer Product Safety Commission regarding toys, there is no similar regulation of high-risk foods. The data suggest that there is opportunity for improvement in legislation about the production and packaging of high-risk items as well as in the education of caregivers. (22)

*References for this article are at <http://pedsinreview.aappublications.org/content/36/10/430.full>.*

## Parent Resources from the AAP at HealthyChildren.org

- <https://www.healthychildren.org/English/news/Pages/Keeping-Kids-Safe-from-Swallowing-Dangerous-Items.aspx>
- <https://www.healthychildren.org/English/safety-prevention/at-home/Pages/Dangers-of-Magnetic-Toys-and-Fake-Piercings.aspx>
- <https://www.healthychildren.org/English/safety-prevention/at-home/Pages/Button-Battery-Injuries-in-Children-A-Growing-Risk.aspx>
- <https://www.healthychildren.org/English/safety-prevention/at-home/Pages/Childproofing-Your-Home.aspx>

## PIR Quiz

1. Which of the following is the most common retained esophageal foreign body in children?

- A. Button battery.
- B. Coin.
- C. Hard candy.
- D. Paper.
- E. Small toy.

2. A 4-year-old child presents with throat pain along with swelling and crepitus of the neck. His mother believes he may have swallowed a button battery in the last 24 hours. What complication of button battery ingestion is most likely to have occurred in this child?

- A. Aspiration.
- B. Esophageal obstruction.
- C. Esophageal perforation.
- D. Pneumothorax.
- E. Secondary bacterial infection of the soft tissues.

3. A 2-year-old child ingests a button battery that is approximately 2 cm in diameter. Initial radiographs show the battery in the stomach. The child is sent home for conservative management. Three days later the battery has not been found in the child's stool, so a repeat radiograph is performed. The battery is still located in the stomach. The child is in no distress and is eating and drinking normally. What is the recommended management at this point?

- A. Endoscopic removal.
- B. Further observation until the battery traverses the gastrointestinal tract.
- C. Glucagon administration.
- D. Continued observation until the battery passes.
- E. Repeat radiography in 12 hours.

4. A 5-year-old child swallows at least one small magnet. Radiographs show several round radiodense objects in the small intestine. Two of them are very close together but are separated by a few millimeters. What is the significance of this finding?

- A. The magnets are aligned with similar poles repelling each other.
- B. The magnets are likely embedded within adjacent pieces of stool.
- C. This is a nonspecific finding of no consequence.
- D. This is consistent with mural entrapment.
- E. This is consistent with perforation of the bowel.

5. A 2-year-old previously healthy child has had a cough for 2 weeks and a fever for the past 3 days. He has never had any rhinorrhea. Chest radiography reveals an obvious infiltrate in the right middle lobe. He is unable to tolerate oral liquids and, thus, is hospitalized. After 2 days in the hospital receiving intravenous ampicillin, the child is still febrile and becoming more tachypneic. What is the best next step in the management?

- A. Continue on ampicillin because pneumonia is not cured in just 2 days.
- B. Order flexible bronchoscopy to assess for an aspirated foreign body.
- C. Order immunologic studies to assess for an immune deficiency.
- D. Stop the ampicillin and begin administration of a third-generation cephalosporin.
- E. Obtain a sweat chloride test to assess for cystic fibrosis.

**REQUIREMENTS:** Learners can take *Pediatrics in Review* quizzes and claim credit online only at: <http://pedsinreview.org>.

To successfully complete 2015 *Pediatrics in Review* articles for AMA PRA Category 1 Credit™, learners must demonstrate a minimum performance level of 60% or higher on this assessment, which measures achievement of the educational purpose and/or objectives of this activity. If you score less than 60% on the assessment, you will be given additional opportunities to answer questions until an overall 60% or greater score is achieved.

This journal-based CME activity is available through Dec. 31, 2017, however, credit will be recorded in the year in which the learner completes the quiz.



## Ingested and Aspirated Foreign Bodies

S. Sarah Green

*Pediatrics in Review* 2015;36;430

DOI: 10.1542/pir.36-10-430

<b>Updated Information &amp; Services</b>	including high resolution figures, can be found at: <a href="http://pedsinreview.aappublications.org/content/36/10/430">http://pedsinreview.aappublications.org/content/36/10/430</a>
<b>References</b>	This article cites 31 articles, 2 of which you can access for free at: <a href="http://pedsinreview.aappublications.org/content/36/10/430.full#ref-list-1">http://pedsinreview.aappublications.org/content/36/10/430.full#ref-list-1</a>
<b>Subspecialty Collections</b>	This article, along with others on similar topics, appears in the following collection(s): <b>Journal CME</b> <a href="http://classic.pedsinreview.aappublications.org/cgi/collection/journal_cme">http://classic.pedsinreview.aappublications.org/cgi/collection/journal_cme</a> <b>CME</b> <a href="http://classic.pedsinreview.aappublications.org/cgi/collection/cme">http://classic.pedsinreview.aappublications.org/cgi/collection/cme</a>
<b>Permissions &amp; Licensing</b>	Information about reproducing this article in parts (figures, tables) or in its entirety can be found online at: <a href="https://shop.aap.org/licensing-permissions/">https://shop.aap.org/licensing-permissions/</a>
<b>Reprints</b>	Information about ordering reprints can be found online: <a href="http://classic.pedsinreview.aappublications.org/content/reprints">http://classic.pedsinreview.aappublications.org/content/reprints</a>



## Ingested and Aspirated Foreign Bodies

S. Sarah Green

*Pediatrics in Review* 2015;36;430

DOI: 10.1542/pir.36-10-430

The online version of this article, along with updated information and services, is located on the World Wide Web at:

<http://pedsinreview.aappublications.org/content/36/10/430>

Pediatrics in Review is the official journal of the American Academy of Pediatrics. A monthly publication, it has been published continuously since 1979. Pediatrics in Review is owned, published, and trademarked by the American Academy of Pediatrics, 345 Park Avenue, Itasca, Illinois, 60143. Copyright © 2015 by the American Academy of Pediatrics. All rights reserved. Print ISSN: 0191-9601.

## American Academy of Pediatrics

DEDICATED TO THE HEALTH OF ALL CHILDREN®

