

PediatricsⁱⁿReview[®]

Gynecomastia and Premature Thelarche : A Guide for Practitioners

Stavros Diamantopoulos and Yong Bao

Pediatrics in Review 2007;28:e57

DOI: 10.1542/pir.28-9-e57

The online version of this article, along with updated information and services, is located on the World Wide Web at:

<http://pedsinreview.aappublications.org/content/28/9/e57>

Pediatrics in Review is the official journal of the American Academy of Pediatrics. A monthly publication, it has been published continuously since 1979. Pediatrics in Review is owned, published, and trademarked by the American Academy of Pediatrics, 141 Northwest Point Boulevard, Elk Grove Village, Illinois, 60007. Copyright © 2007 by the American Academy of Pediatrics. All rights reserved. Print ISSN: 0191-9601.

American Academy of Pediatrics

DEDICATED TO THE HEALTH OF ALL CHILDREN™



Gynecomastia and Premature Thelarche: A Guide for Practitioners

Stavros Diamantopoulos,
MD,* Yong Bao, MD[†]

Author Disclosure
Drs Diamantopoulos
and Bao did not
disclose any financial
relationships relevant
to this article.

Introduction

Gynecomastia is the presence of breast tissue in males. The term comes from the Greek word *gyne* (woman) and *mastos* (breast). Gynecomastia is common and often is a concern for families, but it usually is a normal part of adolescent development. Pathologic gynecomastia does occur and can be related to a serious underlying problem. Any abnormal breast development in males warrants evaluation.

Premature thelarche (*thely*=female, *arche*=beginning) is isolated breast development in girls younger than 8 years of age. Premature thelarche usually is benign, but may signify a more complicated condition. Practitioners should know how to evaluate early breast development in girls.

Normal Breast Development and Physiology

A mature mammary gland consists of 15 to 25 lactiferous ducts and lobes. Development of the breast tissue anlage is identical in the male and female fetus. Before puberty, the breast consists of the same number of lactiferous ducts ending in small ductules lined with epithelial cells. It is not until puberty that mammary gland development progresses in females, reaching completion during the first pregnancy. The mature terminal alveolar buds formed in early pregnancy are called acini. The units of lactiferous ducts with their lobules compose a lobe. Lobes are separated by dense connective tissue septa.

Several hormones influence breast development. Under estrogen stimulation, ductal and stromal components proliferate. Duct growth and division result in lobules that consist of alveolar buds clustering around a terminal duct. Lobules lie within a growing stroma of loose, hormone-sensitive connective tissue that supports the mammary gland. Progesterone promotes acinar differentiation of the ductal system. Prolactin has a trophic effect on the alveolar buds, promoting acinar formation and the secretory differentiation of the mammary epithelium to support lactation. Receptors for luteinizing hormone (LH) / human chorionic gonadotropin (hCG) have been found in mammary tissue; it is believed that these hormones also may affect breast development. Insulin and insulin-like growth factor-1 also facilitate breast development. Androgens (testosterone and dihydrotestosterone) limit breast development.

Significant decreases in estrogenic stimulation result in atrophic changes of the ductal system, characterized by fibrosis and hyalinization of the supporting connective tissue. Such atrophic changes occur physiologically after menopause.

Sex Hormone Synthesis

To understand how gynecomastia can develop, a review of androgen and estrogen biosynthesis is necessary. Imbalance in the serum concentrations or in the synthesis of androgen or estrogen can lead to gynecomastia or premature thelarche.

The first step in the biosynthesis of androgen and estrogen is the uptake of cholesterol by mitochondria in the adrenals, ovaries, and testes (ie, the sex steroid-producing endocrine glands). The testes make testosterone primarily. Testosterone is converted irreversibly to the more biologically active androgen dihydrotestosterone in extragonadal tissues. The adrenal gland secretes dehydroepiandrosterone (DHEA) and androstenedione (Fig. 1). Androstenedione can be aromatized to estrogen in peripheral tissues. Testosterone produced in the ovary is converted to estradiol by the enzyme aromatase. Some estradiol

*Fellow.

[†]Assistant Professor, Division of Pediatric Endocrinology, Department of Pediatrics, Miller School of Medicine, University of Miami, Miami, Fla.

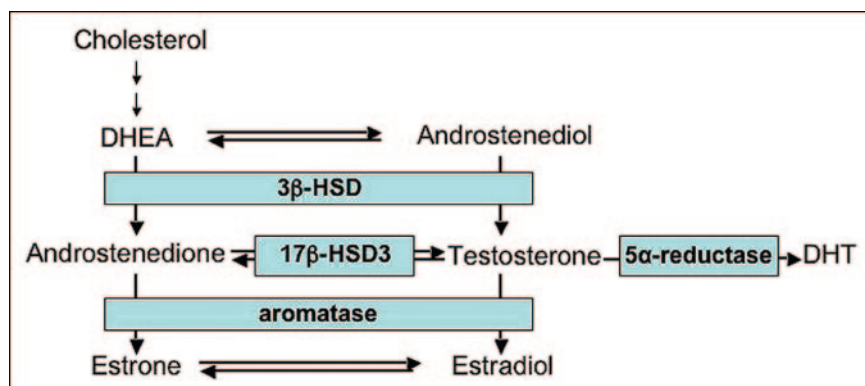


Figure 1. Simplified sex steroid production pathway. Androgens may be converted to estrogens by the enzyme aromatase. DHEA=dehydroepiandrosterone, DHT=dihydrotestosterone, 17β-HSD3=17-β hydroxysteroid dehydrogenase III, 3β-HSD=3-β hydroxysteroid dehydrogenase.

also is produced by this pathway in the testes and in other extragonadal sites such as adipose tissue, skin, and liver.

Sex steroids circulate in the blood either free or bound to sex hormone-binding globulin (SHBG) and other plasma proteins (Fig. 2). Because SHBG binds androgens with higher affinity than it binds estrogen, conditions that increase SHBG concentrations result in a relatively larger decrease in the free fraction of androgens than in the fraction of estrogen.

Fetal and Neonatal Hormone Secretion

The fetus is exposed to high concentrations of estrogen, primarily estriol, produced by the mother and the placenta. On the first and second days after birth, testoster-

one secretion in boys and estradiol secretion in girls surges due to neonatal hypothalamic-pituitary-gonadal axis activity. Gonadotropin secretion then declines, reaching a nadir 10 days after birth, and subsequently increases again, reaching a peak at 2 months of age. By 6 months of age, gonadotropin secretion drops to prepubertal levels. This “minipuberty of early infancy” is a physiologic process, often clinically apparent in both sexes, and can be persistent, which may explain the slight increase of breast tissue observed in some infants.

Because the fetal mammary gland is exposed to the hormonal perturbations of pregnancy, neonatal galactorrhea (“witch’s milk”) frequently develops as a result of the acute decrease of estrogen and progesterone concentrations shortly after delivery. The sudden decrease in serum estrogen and progesterone may facilitate prolactin and oxytocin secretion by the neonatal pituitary.

In childhood, sex steroid concentrations remain low until the onset of puberty. In females, gonadotropins stimulate the ovarian estradiol production responsible for the feminizing changes of puberty. In males, activation of the gonadotropin axis stimulates testosterone secretion. Sex steroid concentrations rise gradually until adult concentrations are achieved at the end of puberty. Estradiol concentration reaches the adult range before testosterone concentration does.

The testes are responsible for more than 95% of testosterone production and about 15% of estradiol production. Aromatization of androgens in extragonadal tissue is the primary source of estrogen in males.

Gynecomastia

True gynecomastia is difficult to distinguish from other entities, especially in obese individuals. Rare conditions that may mimic gynecomastia, such as neurofibromas, sarcomas, epithelial inclusion cysts, duct ectasia, and mastitis, often cause unilateral breast enlargement. Some of the conditions men-

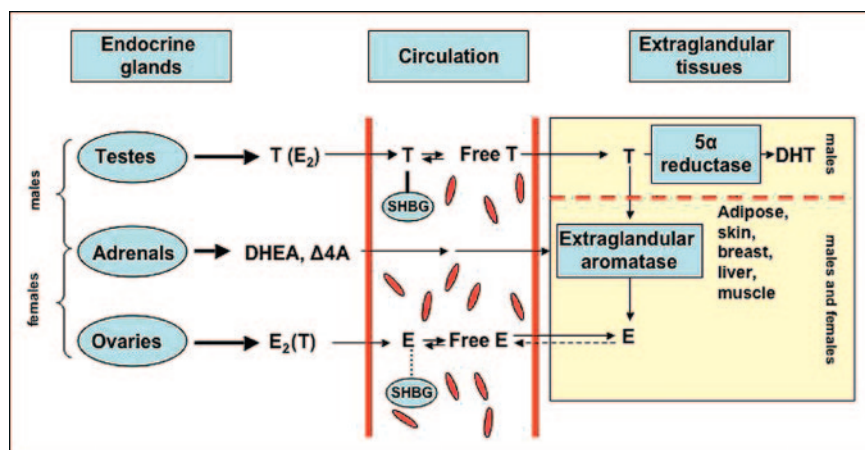


Figure 2. Sex steroid production in endocrine glands, circulation in blood stream, and conversion in extraglandular tissues. T=testosterone, E₂=estradiol, SHBG=sex hormone-binding globulin, DHT=dihydrotestosterone, DHEA=dehydroepiandrosterone, Δ₄A=androstenedione, E=estrogen.

tioned in this section affect girls as well as boys, in which case the breast enlargement technically represents premature thelarche rather than gynecomastia.

Epidemiology

Gynecomastia occurs primarily in three time periods: neonatal period/early infancy, adolescence, and old age. Up to 90% of neonates of both sexes may have palpable breast tissue that even may increase slightly after birth. In male infants, we use the term gynecomastia to describe this condition; in females, we use the term thelarche. Breast enlargement usually resolves within the first few months after birth but may persist for up to 12 months in males and 18 to 24 months in females. After early infancy, prepubertal gynecomastia occurs rarely and warrants careful evaluation.

In contrast, up to 60% of males may develop gynecomastia during adolescence. Peak incidence is observed in mid-puberty (13 to 14 years). Approximately 75% of cases resolve within 2 years of appearance, but gynecomastia may persist into adulthood. (1)

Pathogenesis and Conditions Associated With Gynecomastia

As noted previously, breast enlargement results from an imbalance between androgenic and estrogenic stimulation. In most conditions, the estrogen effect is increased, but the androgen effect also may be decreased. Sometimes, both estrogen increase and androgen decrease contribute to the development of gynecomastia, with either hormone having a predominant effect.

Neonatal Gynecomastia and Thelarche

Family members eager to resolve breast development by “extracting the milk” may prolong or exacerbate physiologic neonatal gynecomastia because breast stimulation promotes secretion of prolactin and oxytocin by the pituitary gland. Expressing milk from the neonatal breast also may result in mastitis or galactocele formation.

Physiologic Pubertal Gynecomastia

Physiologic pubertal gynecomastia most likely is related to a lag in maturation of testosterone secretion, thereby permitting greater estrogen effect. Detection of testosterone/estrogen imbalance requires a 24-hour evaluation because the estradiol-to-testosterone ratio in a single blood sample is similar in boys who have and do not have gynecomastia. However, the 24-hour secretion pattern of testosterone and estradiol in boys who have breast development indicates that the overall estradiol-to-testosterone ratio within 1 day is slightly higher. This

imbalance is considered transient, and the serum estradiol-to-testosterone ratio may be normal by the time medical attention is sought. (1) Physiologic pubertal gynecomastia usually presents at early to mid-puberty, with variable breast size and a peak incidence at 14 years of age.

Gynecomastia is a more common finding in obese males and typically persists longer than does gynecomastia in nonobese males. Breast enlargement may be due to increased aromatization of androstenedione to estrone by adipose tissue.

Idiopathic gynecomastia is a term used to describe abnormal breast development in males for which no pathologic cause has been identified after clinical and laboratory investigation. Most cases develop in puberty or adulthood, although idiopathic gynecomastia can occur in prepubertal boys. By definition, idiopathic gynecomastia represents a benign condition, but it may persist, cause cosmetic and psychological problems, and require treatment.

Pathologic Gynecomastia

Hormonal causes of pathologic gynecomastia, listed in the categories of increased estrogen or decreased androgen, are presented in Table 1. Male secondary hypogonadism may cause both decreased androgen and estrogen concentrations and rarely causes gynecomastia. Several drug classes associated with gynecomastia are listed in Table 2. Many drugs have an estrogenic or antiandrogenic effect, but the underlying mechanisms remain unknown for other drugs.

Table 1. Causes of Abnormal Breast Development in Males

Increased Estrogen

- Estrogen-secreting tumors
- Tumors secreting human chorionic gonadotropin
- Increased aromatase activity
- Exogenous estrogen
- Liver dysfunction
- Hyperthyroidism
- Congenital adrenal hyperplasia

Decreased Androgen

- Primary gonadal dysfunction
- Defects in testosterone biosynthesis
- Androgen insensitivity

Table 2. Drugs Associated With Gynecomastia

	Androgen Synthesis/ Androgen Receptor Antagonists	Antibiotics	Antitumor	Abuse	Chemotherapy	Cardiovascular	Psychiatric/ Neurologic	Other
Hormones	Ketoconazole, finasteride, cimetidine, cyproterone	Antituberculosis: Isoniazid, ethionamide	Histamine ₂ blockers: Cimetidine, ranitidine	Alcohol, marijuana, heroin, amphetamines	Methotrexate, alkylating agents, vinca, cyclophosphamide	Diuretics: Furosemide, spironolactone	Phenytoin, tricyclic antidepressants, phenothiazines, risperidone, diazepam, clonidine, selective serotonin reuptake inhibitors	Theophylline, D-penicillamine, cyclosporine
Growth hormone, human chorionic gonadotropin, estrogen, anabolic steroids	Antibacterial: Metronidazole	Antiviral: HAART (highly active antiretroviral treatment)	Proton pump inhibitors: Omeprazole			Angiotensin-converting enzyme inhibitors		
						Calcium channel blockers: Nifedipine, verapamil, reserpine		

Neoplasia

TESTICULAR TUMORS. Testicular tumors such as germ cell, Sertoli cell, and Leydig cell tumors account for 1.5% of childhood neoplasias and may be associated with gynecomastia. Germ cell tumors are the most common testicular neoplasms, with two peaks of occurrence: one in the first 2 years after birth and one after 14 years of age. Germ cell tumors may secrete hCG, resulting in increased secretion of both testosterone and estradiol by the testis, with the increase in estradiol secretion out of proportion to that of testosterone. Risk factors for germ cell tumors are cryptorchidism and gonadal dysgenesis (usually associated with ambiguous genitalia). Germ cell tumors typically develop within the testis but also may appear in the central nervous system (CNS), mediastinum, retroperitoneum, and sacrococcygeal area.

Gynecomastia may be present in 10% to 15% of patients who have Sertoli and Leydig cell tumors, with gynecomastia appearing before a testicular mass is palpable. Leydig or Sertoli cell tumors are extremely rare in childhood and may increase the production of estrogen. Precocious puberty is common in Leydig but rare in Sertoli cell tumors. Sertoli cell tumors usually present in the first postnatal year and typically are benign. However, Sertoli cell tumors can present after 5 years of age, at which time they are associated with more malignant behavior. Sertoli cell tumors may be seen in association with Peutz-Jeghers syndrome (characterized by mucosal lentigines, hamartomatous gastrointestinal polyps, and nongastrointestinal tumors). Leydig cell tumors have a peak incidence in children during middle childhood (5 to 6 years); unlike adult cases, they rarely metastasize in children.

LIVER TUMORS. Hepatoblastoma occurs almost exclusively in the first 3 years after birth. This tumor may secrete hCG, which rarely can induce breast enlargement. Hepatoblastoma that produces hCG usually causes signs of precocious puberty in females. Hepatocellular carcinoma may cause breast enlargement by increased aromatization of androgen precursors to estradiol.

ADRENAL TUMORS. Adrenal tumors associated with breast enlargement typically produce large amounts of DHEA and dehydroepiandrosterone sulfate (DHEAS) because the tumors are relatively deficient in 3-beta-hydroxysteroid dehydrogenase. These androgen precursors are aromatized into estrogen, whose increased concentrations may induce gynecomastia. Although rare, adrenal tumors also may produce estrogen directly. Ad-

renal tumors generally cause virilization in girls, but breast enlargement also may occur in combination with other signs of precocious puberty. In general, adrenal tumors that cause feminization are malignant.

Hypogonadism

Primary hypogonadism, also known as hypergonadotropic hypogonadism, is due to gonadal dysfunction. Primary hypogonadism is characterized by testicular dysfunction and abnormally elevated serum concentrations of gonadotropins (follicle-stimulating hormone [FSH] and LH). The increased serum concentrations of LH stimulate production of estradiol by Leydig cells within the testis, leading to gynecomastia.

The most common diagnosis associated with hypergonadotropic hypogonadism is Klinefelter syndrome, a condition that occurs in about 1 of every 600 newborn males. Salient features in adolescents include eunuchoid body habitus, testicular atrophy, gynecomastia, and behavioral problems. Gynecomastia in boys caused by Klinefelter syndrome may be associated with an increased risk of breast cancer, unlike other causes of gynecomastia.

Other causes of hypergonadotropic hypogonadism include testicular damage from orchitis (most commonly mumps orchitis), trauma, chemotherapy, radiation, renal failure, myotonic dystrophy, spinal cord injury, or abnormalities of testicular determination. The latter category includes a group of conditions such as 46,XY gonadal dysgenesis, 45X/46,XY gonadal dysgenesis, and 46,XX maleness.

Secondary hypogonadism is associated with conditions that disrupt gonadotropin-releasing hormone production by the hypothalamus or the production of LH and FSH by the pituitary. Gynecomastia is extremely unusual in secondary hypogonadism because both testosterone and estradiol secretion is low. However, testosterone production may be subnormal compared with that of estradiol, thereby causing an abnormal estrogen-to-androgen ratio. Three conditions that may lead to secondary hypogonadism with gynecomastia are craniopharyngioma resection, prolactin-secreting pituitary adenoma, and hyperprolactinemia of any cause. Although the peak incidence of craniopharyngioma is 5 to 9 years of age, obesity and hypopituitarism in adolescent boys may develop years after craniopharyngioma resection, leading to gynecomastia. Prolactin-secreting pituitary adenomas and hyperprolactinemia of any cause may suppress gonadotropin production, leading to secondary hypogonadism and gynecomastia. Milky nipple discharge (galactorrhea) may be an associated sign of hyperprolactinemia.

Hyperthyroidism

Gynecomastia is common in boys who have thyrotoxicosis, due primarily to increased production of androstenedione, which is aromatized to estrogen.

Aromatase Excess

Increased aromatase activity has been described in some cases of familial gynecomastia. (2) In these families, gynecomastia generally appears in the prepubertal years. Transmission usually is autosomal dominant, and the increase in serum estrone may be greater than that of estradiol in affected patients.

Defects in Testosterone Biosynthesis

Patients who have 17-beta-hydroxysteroid dehydrogenase III (also termed 17-ketoreductase) deficiency have a defect in the conversion of androstenedione to testosterone. Affected individuals typically develop gynecomastia in adolescence due to high serum LH concentrations, as well as to high concentrations of androstenedione that is aromatized to estrogen.

Abnormalities of End Organ Responsiveness to Androgen

Children afflicted with partial androgen insensitivity typically have ambiguous genitalia at birth and gynecomastia at puberty. Some who have subtle abnormalities of androgen receptor function may present with gynecomastia and normal-appearing male genitalia but experience infertility later in life.

Congenital Adrenal Hyperplasia (CAH)

Poorly controlled CAH due to 21-hydroxylase deficiency is a rare cause of gynecomastia. Breast development is due to increased aromatizable androstenedione. Other rare forms of CAH associated with gynecomastia include 11-beta-hydroxylase deficiency and 3-beta-hydroxysteroid dehydrogenase deficiency. Deficiency of 11-beta-hydroxylase typically is characterized by virilization and variable hypertension. Deficiency of 3-beta-hydroxysteroid dehydrogenase, characterized by impaired steroidogenesis of glucocorticoids, mineralocorticoids, and sex steroids, may present with salt wasting and ambiguous genitalia. As with adrenal tumors, CAH can affect girls. Virilization is the prominent feature, and breast enlargement may occur with other signs of precocious puberty.

Table 3. Elements of a History for Evaluation of Gynecomastia

Question	Rationale
Presenting Complaint	
Age at Onset of Puberty	
–Early (before 9 years of age)	Consider tumors that produce androgen and estrogen
–Normal	Physiologic gynecomastia more likely
–Late	Consider gonadal dysfunction, abnormalities of testosterone biosynthesis or action
Age of Onset of Gynecomastia	
–Before puberty	Consider causes of prepubertal gynecomastia such as steroid-secreting tumors
–During puberty	Physiologic gynecomastia more likely
–After puberty	Physiologic gynecomastia less likely; consider abnormalities such as gonadal dysfunction, tumors, drugs
Progression	Rapid progression is not typical of physiologic gynecomastia
Tenderness, pain	Suggestive of true gynecomastia (versus fatty pseudogynecomastia)
Nipple discharge	
–Milky	Consider increased prolactin secretion
–Serosanguineous/sebaceous	Consider local conditions
Past Medical History	
Surgery for cryptorchidism or hypospadias	Consider testicular dysfunction
Psychosocial functioning and learning problems	Consider substance abuse (alcohol, marijuana), Klinefelter syndrome
Recovery from chronic illness or weight loss	Consider refeeding gynecomastia
Drug Use	Drugs causing gynecomastia
Family History	
Family history of gynecomastia or abnormal sexual development	Hormonal abnormality more likely
Social History	
Participation in competitive sports (adolescents)	Anabolic steroid use
Other cases among peers (household or school)	Estrogen in food and cosmetics
Adoption history	Refeeding gynecomastia

Environmental Estrogen Exposure

Numerous drugs (Table 2), anabolic steroids, and marijuana can cause breast enlargement in both sexes, as can estrogen exposure from cosmetics or food. Environmental estrogen exposure is discussed in detail in the thelarche section.

Systemic Disease

Liver cirrhosis can cause gynecomastia through impaired catabolism of estrogens. Renal failure also is associated with gynecomastia, probably from testicular damage and abnormal elevation of serum LH concentrations. (1)

Refeeding gynecomastia also occurs. Proposed mechanisms for patients developing gynecomastia while recovering from prolonged starvation are a transient decrease in estrogen catabolism or recovery from a hypogonadic state with an abnormal ratio of estradiol to testosterone production, similar to the situation observed in puberty.

History and Physical Examination

Table 3 lists the specific information that should be sought when taking a history during the evaluation of gynecomastia.

A physical examination is important to confirm the presence of gynecomastia and to investigate other related conditions that may be present. The breasts are observed first, with the male patient wearing no clothes on the upper part of the body and sitting upright with his hands hanging loosely on his sides. (Some males prefer to wear a gown, especially if they have gynecomastia.) The breast and nipple shape and contour are noted with the patient lying down and putting his hands behind his neck. The examiner should palpate gently from the center of the nipple to the periphery to ascertain the margins of breast development and then measure breast diameter. A breast diameter greater than 4 cm defines macrogynecomastia, which warrants a more detailed investigation because the size of the breast tissue is a function of both the magni-

tude and duration of the estrogen-to-androgen imbalance. Although typically described as a “coiled rope,” the texture of glandular tissue may vary from a discrete elastic disc under the nipple to a diffuse mass indistinguishable from adipose tissue. Asymmetric or unilateral breast development is common and does not predict underlying disease. Applying soft pressure from the periphery of the breast toward the nipple may induce the nipple to discharge any underlying fluid.

Examination of the genitalia is important for documenting pubertal stage and detecting testicular tumors. In boys younger than 9 years, testicular volume greater than 3 mL (using a Prader orchidometer) or testicular length more than 2.5 cm (excluding the epididymis) indicates precocious puberty. The presence of pubertal signs in a boy younger than 9 years suggests an underlying malignancy or a CNS lesion until proven otherwise. Both testes should be palpated and transilluminated for tumors. Patients who have gonadal dysfunction (ie, Klinefelter syndrome) may have small, firm testes after puberty.

Physiologic gynecomastia usually appears when males are at Sexual Maturity Rating stages 2 to 3 for pubic hair and genitalia. The presence of gynecomastia associated with a discrepancy between testicular size (smaller than expected) and pubic hair development should alert the clinician to the possibility of hypogonadism because pubic hair development may be stimulated by adrenal steroids, creating the impression that pubertal progression is appropriate when it is not.

The general examination provides useful information such as growth and nutritional status, body habitus, liver size and texture, presence of abdominal masses, and presence of any physical stigmata suggestive of syndromic conditions. A bulky, tall phenotype frequently is seen in adolescents who have physiologic gynecomastia. Presence of eunuchoid body habitus is suggestive of Klinefelter syndrome.

Abnormal neurologic, visual field, or funduscopic findings together with small testes may indicate pituitary or other CNS disease that may be causing hypogonadotrophic hypogonadism.

Patients who have findings suggestive of physiologic gynecomastia should be reassured but followed regularly. Follow-up is important to monitor pubertal progression and breast development, whether or not laboratory investigations are performed. A full physical examination with particular attention paid to the features outlined previously should be undertaken at every follow-up visit.

Specialist Referral and Laboratory Evaluation

For those patients who appear to have pathologic gynecomastia, additional evaluation is necessary, including consultation with a pediatric endocrinologist. Candidates for specialist referral and laboratory evaluation include:

- Patients who have history or physical examination findings suggestive of underlying pathologic conditions.
- All patients who have gynecomastia and present between 3 months of age and before puberty, unless gynecomastia was present from birth. Onset of gynecomastia at a late stage of puberty also may require evaluation.
- Patients who have macrogynecomastia (>4 cm) or who experience rapid increase in breast size because either condition may indicate persistent estrogen and androgen imbalance due to an underlying pathologic condition rather than to a transient physiologic imbalance.

Patients who have galactorrhea should be evaluated for conditions that cause hyperprolactinemia. Other forms of nipple discharge (purulent, serous, sanguineous, brownish) suggest local disease or skin conditions that may require referral to a surgeon or a dermatologist. Although extremely rare, breast carcinomas and ductal papillomas do occur in males and may manifest with bloody discharge.

Other reasons for referral to a specialist include parental request, physician unease, and risk of patient noncompliance with follow-up.

Laboratory Testing

Laboratory investigations can precede specialist referral, but normal laboratory results do not necessarily exclude underlying pathologic conditions and do not obviate the need for continued follow-up. The initial laboratory investigation may include determining 8 AM fasting serum concentrations of LH, FSH, testosterone, estradiol, beta-hCG, DHEAS, and liver enzymes. A guide for interpreting these tests is presented in Figure 3.

Imaging studies for gynecomastia generally are not useful.

Management

The key role of the primary care pediatrician is to determine which cases represent physiologic gynecomastia and which are suspicious for pathologic gynecomastia and require specialist referral. For patients who have pathologic gynecomastia, specialists usually manage treatment. For physiologic gynecomastia, clinicians or specialists usually reassure patients and follow them

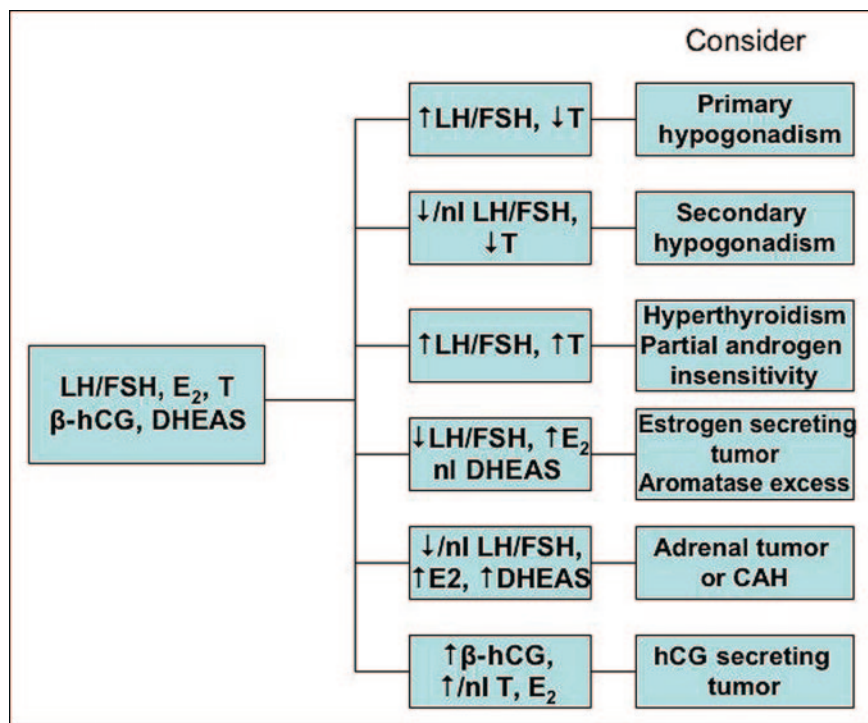


Figure 3. Interpretation of laboratory tests recommended for initial investigation of gynecomastia. LH=luteinizing hormone, FSH=follicle-stimulating hormone, T=testosterone, nl=normal, E₂=estradiol, beta-hCG=beta human chorionic gonadotropin, DHEAS=dehydroepiandrosterone sulfate

closely. There are various approaches to the management of marked idiopathic gynecomastia.

Pharmacologic treatment can decrease estrogen effect either by blocking estrogen receptors or by inhibiting aromatase activity. Two possible categories of drugs have been considered for the treatment of pathologic gynecomastia: 1) specific estrogen receptor modulators (also known as antiestrogens) such as tamoxifen, raloxifene, and clomiphene citrate, and 2) aromatase inhibitors such as testolactone, anastrozole, and letrozole. Current data are insufficient to demonstrate the effectiveness of either class of drugs. Some reports on tamoxifen and raloxifene have shown improvement in up to 91% of patients, (3) but no double-blind, placebo-controlled trials in this age group support these findings. The effectiveness of anastrozole was investigated recently in a double-blind, placebo-controlled study of 80 adolescent boys who had gynecomastia. The criterion for improvement was a greater than 50% reduction of breast volume. No benefit of anastrozole over placebo was demonstrated. (4) Surgery is an option to reduce breast size, but some experts advocate a trial of tamoxifen before considering surgery.

The dilemma of managing idiopathic excessive breast

development is whether to treat a condition early in its development, when it may resolve without intervention, or to defer treatment and risk the chance that treatment will be less effective if eventual breast development is much greater. The authors believe that reassurance and close follow-up are the mainstays of management until more data are available regarding the effectiveness of pharmacologic intervention.

Premature Thelarche

Breast development in females is considered premature if it occurs before 8 years of age. Premature thelarche is defined as isolated breast development without evidence of sexual hair development, estrogenization of vaginal mucosa, acceleration of linear growth, rapid bone maturation, adult body odor, or behavioral changes typical of puberty. Although some experts advocate using the lower age limit of 7 years for Caucasian girls, this decision

should be made by a pediatric endocrinologist in individual cases. The lower age limit for African-American and Mexican-American girls is younger than for Caucasian girls by approximately 1 year. Therefore, the 7-year criterion might be more appropriate for these groups.

Isolated premature thelarche usually is considered to differ from central precocious puberty, which is the early (before 8 years of age) maturation of the hypothalamic-pituitary-gonadal axis with development of two or more sexual characteristics. However, it has been suggested that premature thelarche may represent one end of a continuum from isolated breast development to central precocious puberty. (5)

Premature thelarche typically occurs during the first 2 years after birth, and breast size may fluctuate cyclically. Premature thelarche usually does not progress to precocious puberty and typically resolves during childhood, but may last until puberty. By definition, premature thelarche does not affect the time of pubertal onset. (6)

Exaggerated thelarche describes a variant of isolated breast development. Although there is no axillary or pubic hair, there may be some acceleration of growth

Table 4. Key Features of Premature Thelarche and Precocious Puberty

Feature	Premature Thelarche	Precocious Puberty
Incidence peak (range)	6 mo to 2 y (<8 y)	5 to 8 y (<8 y)
Breast		
Sexual Maturity Rating stage	Usually 2, early 3	2 through 5
Size fluctuation	In 80%	No
Pubic hair	No	At least one present plus breast development
Axillary hair	No	
Apocrine odor	No	
Menses	No*	Yes
Linear growth acceleration	No*	Yes
Advanced bone age	No*	Yes
Outcome	Considered benign	May be associated with short stature, early onset of puberty

*May be present in exaggerated thelarche.

velocity and bone maturation at the time of breast development. Limited numbers of patients who have exaggerated thelarche have been studied; the mean age at presentation in one study was 3.7 (1.9 to 6.9) years. The authors also noted that persistent thelarche until puberty was more common than noted before, with possible progression to central precocious puberty and early menstruation. (5)

As mentioned, breast development present from birth almost always is physiologic, and the tissue should decrease gradually and resolve within the first 2 postnatal years. Key features of premature thelarche and precocious puberty are presented in Table 4.

Pathophysiology and Causes

Isolated premature thelarche and exaggerated thelarche may be due to partial activation of the hypothalamic-pituitary-gonadal axis, principally by FSH secretion, or to failure of follicular involution with or without ovarian cyst formation. In the latter case, estrogen secretion may be sufficient to cause menstrual bleeding.

A less common cause is gonadotropin-independent estrogen production, as seen in McCune-Albright syndrome and rare ovarian or adrenal tumors (although these conditions usually present with precocious puberty). McCune-Albright syndrome generally presents with the classic triad of gonadotropin-independent precocious puberty, café au lait macules, and polyostotic fibrous dysplasia. Activating *GNAS1* mutations with mosaic distribution are the underlying cause of precocious puberty. *GNAS1* is a subunit of the G-protein coupled receptors involved in intracellular signal transduction of several hormones. The presence of such mutations in the ovaries results in estrogen production without gonado-

tropin stimulation. The mosaic distribution may account for differences in manifestations of McCune-Albright syndrome. Such mutations also have been identified in females who have premature or exaggerated thelarche without having other features of this syndrome. Other rare conditions that may present with thelarche due to gonadotropin-independent estrogen production include hepatocellular carcinoma, adrenal tumors, and CAH.

Premature thelarche may result from exposure to exogenous estrogen, including estrogen-containing cosmetic and hair products. One study reported an association between an increase in the incidence of premature thelarche and estrogen concentrations in poultry, (7) although this finding has not been confirmed. Infant formulas containing soy also may be associated with thelarche, but insufficient evidence is available to recommend avoidance of specific foods. An outbreak of cases of thelarche in female students and gynecomastia in male students at a school in Italy has been reported. (8) Although this event might suggest a common exposure, no cause has been established.

Xenoestrogens are chemical substances that bind to the estrogen receptor. A wide variety of chemicals, such as organochlorines, polychlorinated bisphenyls, parabens, bisphenol A, and phthalates, as well as synthetic estrogen diethylstilbestrol and other substances, have estrogenic properties. Some xenoestrogens are used in pesticides, cosmetics, and packaging material. However, only limited data suggest a relationship between their use and the onset of thelarche or gynecomastia.

Exposure to estrogen-containing cosmetics, especially certain hair products, is more common in African-American families and may cause early sexual development. (9) Caregiver use of estrogen-containing creams

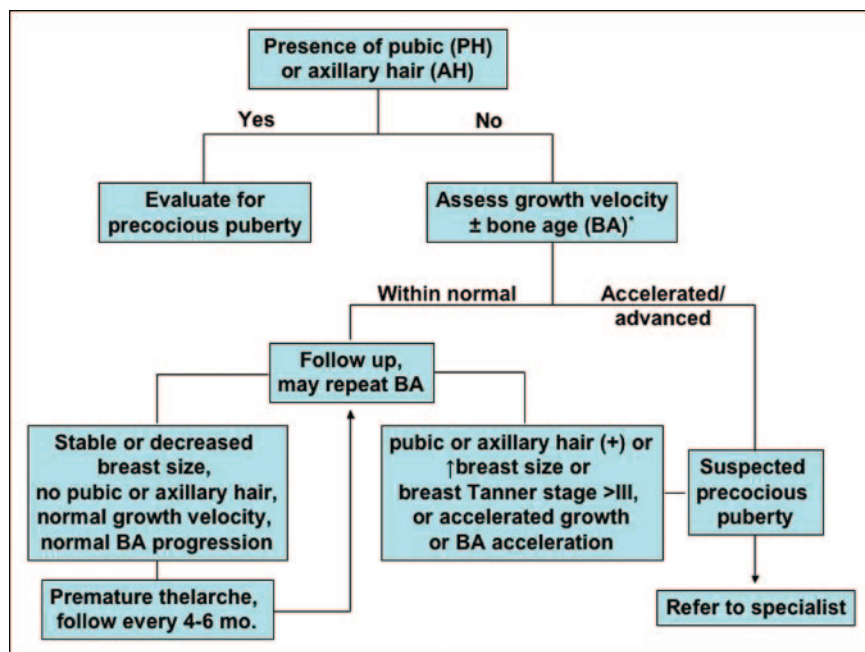


Figure 4. Algorithm for evaluation of females presenting with early breast development. BA=bone age. *See text for indications to measure BA.

may result in breast development in children. Although data on absorption and systemic effects of such products are lacking, it is important to exclude this possibility when evaluating prepubertal children presenting with breast development. A list of hormone-containing cosmetics may be found on the Internet at www.environmentaloncology.org/publications/care-products.htm. Such cosmetics should not be used in children.

Other mechanisms that may play a role in inducing thelarche include increased sensitivity of breast receptors to estrogen and increased aromatization of adrenal precursors.

Epidemiology and Course

A population-based study in Minnesota found an incidence of 20.8 cases of premature thelarche per 100,000 patient-years, with 60% of cases presenting in the first 2 years after birth and a less pronounced incidence peak at ages 5 to 7 years. (6) A more recent study found a prevalence of 2.1% among 3-year-old African-American and 0.7% among Caucasian girls. (10) However, the study did not specify how many children also had other pubertal signs. Although age of onset does not strictly predict course, breast enlargement before 2 years of age is considered suggestive of premature thelarche, with a benign course and resolution in 44% to 66% of cases. (6)

In contrast, later onset may predict persistence or exaggerated thelarche variant.

Breast development may be unilateral in up to 50% of patients. Time of resolution may range from 6 months to 6 years. (6) One study observed progression to precocious puberty in 14 of 100 females who presented with isolated breast development. (11) Although it is unclear whether these patients had true central precocious puberty or a high risk for developing precocious puberty, this study does indicate that close follow-up of children who experience premature thelarche is essential.

Evaluation

Premature thelarche must be distinguished from true precocious puberty. Features of true precocious puberty include breast development and estrogenization of the vaginal mucosa and labia minora associated with adult body odor, pubic and axillary hair development, acceleration of linear growth, and rapid bone maturation. When the patient presents with two or more signs of precocious puberty, premature thelarche is excluded.

When breast development is the only pubertal sign present, the history and physical examination may provide clues for environmental estrogen exposure or the presence of McCune-Albright features. If isolated breast development is observed, the previous pattern of growth should be evaluated. The breast should be examined and size determined (see "Physical examination" in the previous section on gynecomastia). Gentle retraction of the labia is important to determine if the mucosa has a reddish prepubertal appearance or a pinker, more estrogenized look. Serial measurements of breast size can be used to monitor changes over time.

If clues for environmental estrogen exposure or McCune-Albright features are not present, the most useful clinical tool is examination of growth velocity. A bone age radiograph should be obtained if accelerated growth velocity is present or if previous growth measurements are unavailable and breast development is substantial or increasing. An algorithm for evaluating females presenting with early breast development is provided in Figure 4. Follow-up is essential to establish the diagnosis

of premature thelarche. A normal growth velocity, the absence of additional pubertal features, and lack of significant progression of breast development support the diagnosis of premature thelarche.

Laboratory Investigation and Referral to a Specialist

The primary care practitioner should consider referral to a pediatric endocrinologist when the diagnosis of premature thelarche is uncertain and central precocious puberty is suspected. Radiographic determination of bone age estimates the extent of estrogenic stimulation because estrogen promotes bone maturation, and an advanced bone age suggests significant estrogen effect. Although studies have shown that patients who experience premature thelarche may have higher serum concentrations of FSH and estradiol as well as more mature ovarian morphology, as shown by ultrasonography, baseline values of FSH and estradiol usually are not helpful because they may be normal even in patients who have true precocious puberty. The specialist may order a gonadotropin stimulation test and pelvic ultrasonography to rule out central precocious puberty or ovarian neoplasms.

Outcome

Isolated premature thelarche is considered a benign condition that has no effect on the age of puberty onset, menses, final height, or fertility. Although menarche appeared to occur earlier in one study, (12) menarche in these females was consistent with the timing of maternal menarche. The theoretical risk of increased breast cancer due to prolonged estrogenic stimulation has not been supported by studies.

Other Breast Disorders

Other rare conditions that may mimic breast development in both sexes usually present with unilateral breast enlargement and include congenital breast anomalies, neurofibromas, sarcomas, epithelial inclusion cysts, duct ectasia, and mastitis. Among the congenital breast anomalies are accessory nipples (polythelia) or breasts (poly-mastia), lack of nipple development (athelia) or absence of breast development (amastia), and inverted nipples. Marked breast asymmetry, juvenile hyperplasia, and tuberous breasts are other breast anomalies. Neoplasms are extremely rare. In pubertal females, the most common breast tumor is benign fibroadenoma. Mastitis in neonates may be severe and require treatment with intravenous antibiotics.

Summary

Gynecomastia in males and premature thelarche in females are common conditions in the pediatric population. Although gynecomastia and premature thelarche represent benign physiologic conditions in most cases, it is important to recognize and treat those patients who may have underlying pathologic conditions. Clues to underlying disease include age of onset, extent and progression, presence of accompanying signs of pubertal development, and use of drugs. If clues to underlying conditions are identified, referral to a specialist is warranted.

ACKNOWLEDGMENTS. The authors would like to thank Dr Gary Berkovitz, Professor, Chief of the Division of Pediatric Endocrinology, Miller School of Medicine, University of Miami, for his help and guidance in editing the manuscript. We also wish to thank Dr Miltiades Douvovannis, Department of Pediatrics, University of Iowa, for providing help in bibliographic research and helpful discussions from the point of the general pediatrician.

References

1. Mahoney CP. Adolescent gynecomastia. Differential diagnosis and management. *Pediatr Clin North Am.* 1990;37:1389–1404
2. Berkovitz GD, Guerami A, Brown TR, MacDonald PC, Migeon CJ. Familial gynecomastia with increased extraglandular aromatization of plasma carbon19-steroids. *J Clin Invest.* 1985;75:1763–1769
3. Lawrence SE, Faught KA, Vethamuthu J, Lawson ML. Beneficial effects of raloxifene and tamoxifen in the treatment of pubertal gynecomastia. *J Pediatr.* 2004;145:71–76
4. Plourde PV, Reiter EO, Jou HC, et al. Safety and efficacy of anastrozole for the treatment of pubertal gynecomastia: a randomized, double-blind, placebo-controlled trial. *J Clin Endocrinol Metab.* 2004;89:4428–4433
5. Stanhope R, Brook CC. Thelarche variant: a new syndrome of precocious sexual maturation? *Acta Endocrinol (Copenh).* 1990;123:481–486
6. Van Winter JT, Noller KL, Zimmerman D. Natural history of premature thelarche in Olmsted County, Minnesota, 1940 to 1984. *J Pediatr.* 1990;116:278–280
7. Saenz de Rodriguez CA, Bongiovanni AM, Conde de Borrego L. An epidemic of precocious development in Puerto Rican children. *J Pediatr.* 1985;107:393–396
8. Nizzoli G, Del Corno G, Fara GM, Chiumello G. Gynaecomastia and premature thelarche in a schoolchildren population of northern Italy. *Acta Endocrinol Suppl (Copenh).* 1986;279:227–231
9. Tiwary CM, Ward JA. Use of hair products containing hormone or placenta by US military personnel. *J Pediatr Endocrinol Metab.* 2003;16:1025–1032
10. Herman-Giddens ME, Slora EJ, Wasserman RC. Secondary

sexual characteristics and menses in young girls seen in office practice: a study from the PEDIATR Res in Office Settings network. *Pediatrics*. 1997;99:505–512

11. Pasquino AM, Pucarelli I, Passeri F. Progression of premature thelarche to central precocious puberty. *J Pediatr*. 1995;126:11–14

12. Salardi S, Cacciari E, Mainetti B, Mazzanti L, Pirazzoli P. Outcome of premature thelarche: relation to puberty and final height. *Arch Dis Child*. 1998;79:173–174

Suggested Reading

Braunstein GD. Gynecomastia. *N Engl J Med*. 1993;328:490–495

Braunstein GD. Prevention and treatment of gynecomastia. *UpToDate Online*. 2007;15.1. Available at: www.uptodate.com

Herskovitz E, Leiberman E. Gynecomastia: a review. *The Endocrinologist*. 2002;12:321–332

Ilicki A, Prager Lewin R, Kauli R, Kaufman H, Schachter A, Laron Z. Premature thelarche—natural history and sex hormone secretion in 68 girls. *Acta Paediatr Scand*. 1984;73:756–762

Lazala C, Saenger P. Pubertal gynecomastia. *J Pediatr Endocrinol Metab*. 2002;15:553–560

Stanhope R. Premature thelarche: clinical follow-up and indication for treatment. *J Pediatr Endocrinol Metab*. 2000;13(suppl 1): 827–830

Gynecomastia and Premature Thelarche : A Guide for Practitioners

Stavros Diamantopoulos and Yong Bao

Pediatrics in Review 2007;28:e57

DOI: 10.1542/pir.28-9-e57

Updated Information & Services

including high resolution figures, can be found at:
<http://pedsinreview.aappublications.org/content/28/9/e57>

References

This article cites 17 articles, 4 of which you can access for free at:

<http://pedsinreview.aappublications.org/content/28/9/e57#BIBL>

Permissions & Licensing

Information about reproducing this article in parts (figures, tables) or in its entirety can be found online at:
</site/misc/Permissions.xhtml>

Reprints

Information about ordering reprints can be found online:
</site/misc/reprints.xhtml>

American Academy of Pediatrics

DEDICATED TO THE HEALTH OF ALL CHILDREN™

