

Worm Infections in Children

Jill E. Weatherhead, MD,*† Peter J. Hotez, MD, PhD*†

**Department of Pediatrics (Sections of Infectious Diseases and Tropical Medicine), National School of Tropical Medicine, Baylor College of Medicine, Houston, TX.*

†Sabin Vaccine Institute and Texas Children's Hospital Center for Vaccine Development, Houston, TX.

Educational Gaps

1. Clinicians should know that worm infections are among the most common pediatric infections in developing countries, led by intestinal helminth infections and schistosomiasis, and that these infections have chronic and disabling consequences for child growth and development.
2. Clinicians should know that some worm infections, such as toxocariasis and cysticercosis, are also common among children living in poverty in the United States and elsewhere in North America and Europe where, in some cases, they are important causes of epilepsy, cognitive impairments, and other illnesses.
3. Clinicians need a high index of suspicion for linking chronic disabilities in children to infections caused by worms.

Objectives After completing the article, the reader should be able to:

1. Recognize the global burden of disease of worms in children.
2. Discuss the age-intensity distribution for worms in children.
3. Recognize the unique signs and symptoms of worm infections found predominantly in developing countries, such as intestinal helminth infections (ie, ascariasis, trichuriasis, hookworm infection) and schistosomiasis, as well as those also found widely in impoverished areas in North America and Europe, such as toxocariasis, enterobiasis, and cysticercosis.
4. Recognize the advantages and disadvantages of diagnostic modalities for helminth infections, schistosomiasis, toxocariasis, taeniasis, and cysticercosis.
5. Discuss and deliver recommended treatment regimens for intestinal helminth infections, schistosomiasis, toxocariasis, taeniasis, and cysticercosis in nonendemic and endemic countries.

AUTHOR DISCLOSURE Drs Weatherhead and Hotez have disclosed no financial relationships relevant to this article. This commentary does contain a discussion of an unapproved/investigative use of a commercial product/device.

INTRODUCTION

Worm infections (also known as helminth infections) are considered among the most common diseases of children living in extreme poverty in the developing countries of Asia, Africa, and Latin America. In addition, a surprising number of children in the United States and Europe are infected with worms.

The major worm infections of children include the four intestinal helminth infections of ascariasis, trichuriasis, hookworm, and enterobiasis, which are transmitted through contaminated soil; schistosomiasis, a water-borne infection associated with an aquatic snail intermediate host; and toxocariasis and cysticercosis, two zoonotic infections caused by larval stages of parasitic helminths. In total, these worm infections rank among the leading global health threats to children.

GLOBAL IMPACT OF WORM INFECTIONS

Worms are not major killers of children, even in developing countries. According to a new estimate, fewer than 20,000 people die annually from the major pediatric helminth infections. (1) Instead, the importance of worms as contributors to global child health conditions is associated with their ability to cause chronic disability that often lasts throughout childhood and adolescence. Over this period, worms stunt growth, cause intellectual and cognitive deficits, and produce damage to selected target organs such as the brain, liver, and urinary tract. Using a metric known as disability-adjusted life years (DALYs) (ie, the number of life years lost either from premature death or disability), a recent analysis by the Global Burden of Disease Study 2010 determined that the major worm infections of children (Table 1) cause 9.0 million DALYs annually, a number approximately equivalent to the DALYs caused by such conditions as measles, pertussis, pervasive development disorder, or rheumatic heart disease. (2)(3)

Intestinal helminth infections, which are also known as soil-transmitted helminth infections, represent the most common worm infections of children. These are led by ascariasis (*Ascaris lumbricoides* roundworm infection), trichuriasis (*Trichuris trichiura* whipworm infection), and hookworm infections (mostly caused by *Necator americanus*, with fewer than 25% of the infections caused either by *Ancylostoma duodenale* or *A ceylanicum* or by mixed infections) as well as pinworm infection (*Enterobius vermicularis*). (15) Strongyloidiasis is a less common intestinal helminth infection that also occurs among selected refugee populations from Africa, Asia, and parts of Latin America and the Caribbean. New Global Burden of Disease Study 2010

estimates indicate that more than 800 million people have ascariasis, while approximately 450 million people each have trichuriasis or hookworm infection (hookworm). (4) Moreover, an extremely common occurrence, especially for a child, is simultaneous infection with two or even all three of these intestinal helminth infections. (4)(15) The number of children who harbor pinworm has not been determined. Hookworm leads the intestinal helminth infections in DALYs and global disability because of their important role in causing anemia. (16) Geographically, the largest number of infected individuals lives in South Asia (ie, Indian sub-continent), Southeast Asia, and East Asia, followed by sub-Saharan Africa and Latin America. (4) In terms of specific countries, the greatest numbers of children with intestinal worms live in India, followed by Nigeria, Indonesia, and Bangladesh. (17) In all, an estimated 874.5 million children require regular and periodic deworming in disease-endemic countries. (18)(19)

Schistosomiasis ranks just behind the intestinal helminth infections as the most common worm infection. (2)(3) Approximately 250 million people are believed to be infected with schistosomes, although some experts have suggested that the actual number of infections could be much higher. (20) Almost all of the cases (99%) are due to *Schistosoma haematobium*, the cause of urinary tract schistosomiasis, or *S mansoni*, the cause of intestinal schistosomiasis. (5)(6) Unlike the intestinal helminth infections that occur worldwide, schistosomiasis is predominantly an African disease. Today, more than 90% of schistosome infections occur in sub-Saharan Africa, with the largest number in Nigeria, Ethiopia, and Democratic Republic of Congo. (5)(6) Of the approximately 250 million people who require treatment for schistosomiasis, almost 50% are children. (5)(6) Another important and unique feature of *S haematobium* infection is the increasing recognition that these particular schistosomes affect the female genital tract to produce female genital schistosomiasis, an ulcerative condition that is strongly associated with an increased risk of acquiring human immunodeficiency virus (HIV)/AIDS. (7)

Two important larval worm infections are toxocariasis and cysticercosis, both of which have been linked to epilepsy. (8)(13) The former is a zoonotic infection acquired from dogs or cats when humans accidentally swallow the eggs of the dog or cat roundworm, *Toxocara canis* or *T cati*, respectively. Toxocariasis is widespread among children in both developing and developed countries, although there are no precise estimates of the number of people infected. Large numbers of cases are found in Brazil, but it may also be the most common worm infection in the United States, even exceeding pinworm. (9) Toxocariasis is more frequently

TABLE 1. Major Worm Infections of Children

DISEASE	MAJOR SPECIES IN HUMANS	ESTIMATED NUMBER OF CASES	LEADING GEOGRAPHIC AREAS OR COUNTRIES	DISABILITY-ADJUSTED LIFE YEARS (DALYs)	REFERENCES
Intestinal Helminth Infections		>1 billion	Asia	5.2 million	2, 3
Ascariasis	<i>Ascaris lumbricoides</i>	819 million	South Asia East Asia	1.3 million	2, 3, 4
Trichuriasis	<i>Trichuris trichiura</i>	465 million	Southeast Asia South Asia	0.6 million	2, 3, 4
Hookworm infection	<i>Necator americanus</i>	439 million	South Asia Southeast Asia	3.2 million	2, 3, 4
Strongyloidiasis	<i>Strongyloides stercoralis</i>	Not determined	East Africa Southeast Asia	Not determined	
Enterobiasis	<i>Enterobius vermicularis</i>	Not determined	Worldwide North America	Not determined	
Schistosomiasis	<i>Schistosoma haematobium</i> <i>Schistosoma mansoni</i>	252 million	Sub-Saharan Africa	3.3 million	2, 3, 5, 6, 7
Toxocariasis	<i>Toxocara canis</i>	Not determined	Worldwide North America	Not determined	8, 9, 10, 11, 12
Taeniasis/ Cysticercosis	<i>Taenia solium</i>	1.4 million cases of epilepsy	Latin America Sub-Saharan Africa South Asia	0.5 million	13, 14
Total		2 billion	Asia, Sub-Saharan Africa	9.0 million	

found in the southern United States and in degraded urban environments, where it is a health disparity disproportionately affecting African American populations. (9) In addition to epilepsy and cognitive delays, (10) the disease has been linked to reduced lung function and even asthma. (11)(12)

Cysticercosis is caused by the larval stages of the pork tapeworm *Taenia solium* and occurs most frequently when humans accidentally ingest the eggs shed from a household carrier with the adult tapeworm in their intestines. (14) In endemic areas of Latin America, sub-Saharan Africa, South Asia, and elsewhere, approximately 30% of epilepsy cases are estimated to be attributed to cysticercosis. (13) Cysticercosis is a chronic condition associated with 1.4 million cases of epilepsy globally and 0.5 million DALYs. (2)(13)

CHILDHOOD SUSCEPTIBILITY TO WORMS

Worms do not typically replicate in humans; disease or severe morbidity occurs primarily when an individual is infected with a large number of worms. An important concept for understanding the vulnerability of children and adolescents to these infections is worm intensity, which refers to the average number of worms per individual. As

shown in Figure 1, with some exceptions, the intensity of each of the major helminth infections primarily peaks in school-age children or adolescents. The basis for this age-dependent predilection is not well understood, and different theories have been proposed based on biological, environmental, or socioeconomic factors.

Thus, among the intestinal helminth infections, ascariasis and trichuriasis (acquired by ingestion of eggs found in contaminated soil) reach maximum age intensities among preschool- and school-age children. (21)(22)(23) Pinworm intensities also tend to peak in childhood and are associated with family size and exposure to pinworm eggs found on fingernails, house dust, and other fomites. (24)(25) In contrast, the maximum hookworm intensity is typically seen in adolescence or early adulthood, after which it often plateaus. (21)(22) Hookworm infection results from direct percutaneous invasion of infective larvae found in the soil. High hookworm intensities among older adolescents and adults may, in some cases, be linked to specific agricultural occupations and handling human feces used as fertilizer. (21) Because of increased worm burden in young adult populations and the risk of significant hookworm-associated iron deficiency anemia, hookworm is an important health

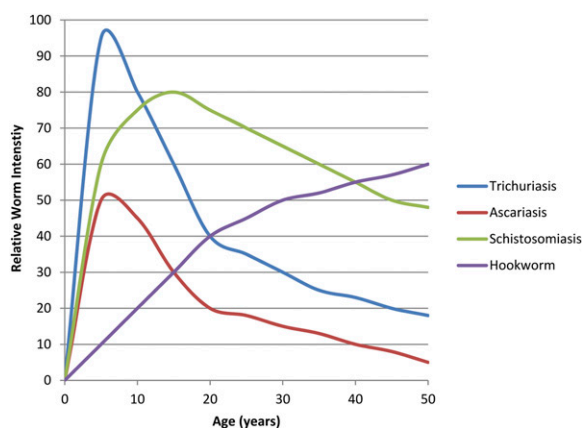


Figure 1. Age-intensity demographics for intestinal helminths and schistosomiasis. (Original figure, data from Hotez et al⁽²¹⁾)

threat to pregnant women and women of child-bearing age. (7)(22)

Schistosomiasis intensity peaks in adolescents and young adults, subsequently declining in adulthood. (21)(26) Because schistosomiasis transmission occurs through direct skin penetration of schistosome infective larvae known as cercariae in contaminated freshwater, (26)(27) its age-dependent predilection may partly reflect increased water exposure from swimming, bathing, fishing, agricultural work, and domestic work such as washing clothes, possibly followed by age-acquired immunity in adulthood. (26)(27)(28)

Toxocariasis can cause disease in all age groups but particularly affects young children. Transmission occurs through ingestion of eggs shed in the feces of dogs and cats that contaminate the soil in poor rural and urban environments. (29)(30) Children are at particular risk due to close contact with dogs or cats, geophagia behavior, and poor hygienic behaviors. In the United States, the disease prevalence and intensity is disproportionately related to poverty.

Cysticercosis, from *T solium* larval infection, results from fecal-oral transmission of eggs excreted in the feces from an asymptomatic human carrier of adult *T solium* worms. (31)(32)(33) Eggs can spread from asymptomatic carriers to household members, particularly in areas of poor hygiene. (33) This mode of transmission is of particular concern for infants living in crowded, poor environments who are exposed repeatedly to multiple infected family members. (31)

MATERNAL-TO-CHILD TRANSMISSION AND IMPACT

Increasing information suggests that pediatric worm infections are influenced by maternal-to-child effects. Hookworm and schistosomiasis are especially important

helminth infections that complicate pregnancies, (7) and the intensity of worm burden in pregnant women has direct and indirect effects on the developing fetus. Maternal infection during pregnancy may cause in utero sensitization to intestinal helminth infections as well as schistosomiasis. Sensitization has been documented through detection of both lymphocyte responses to parasite antigen and specific immunoglobulins in cord blood. (34) Such in utero exposure may be linked to an increased risk of acquisition of worm infections, particularly ascariasis and trichuriasis, during childhood. (35) In addition, infants have been noted in endemic areas of northern India and in some parts of China to be susceptible to hookworm infection caused by *A duodenale*. It has been suggested that the resulting neonatal hookworm syndrome could be related to either vertical transmission of hookworm larvae or lactogenic transmission of larvae to infants during breastfeeding. (36)

CLINICAL SIGNS AND SYMPTOMS

General

High-intensity worm infection in children translates to a number of chronic morbidities (Table 2), which include long-term effects on pediatric physical and cognitive development. (21)(22)(23) The physiologic basis by which worms disrupt physical and mental development of children is presumed to have a nutritional basis, although stronger evidence is needed to support this assumption. Hookworm infection causes both iron deficiency anemia and protein malnutrition, while trichuriasis can cause some anemia as well as chronic inflammation, and ascariasis can cause vitamin A malabsorption. (21)(22)(37)

Helminth-induced chronic malnutrition may result in growth stunting and decreased physical fitness that may resolve after deworming, although the deficits can be permanent in chronic cases. (20)(22) Beyond physical growth and fitness, chronic parasitism can cause decreased school attendance, decreased grade attainment, and reduced cognitive development. (20)(21)(38) Significantly lower cognitive test scores have been demonstrated in children with heavy hookworm infection compared to uninfected children. Cognitive testing has shown the largest gaps in working memory, which affects a child's reasoning ability and reading comprehension. (39) Heavy schistosomiasis has also been associated with decreased learning capacity and subsequent poor performance on standardized intelligence tests, particularly with verbal short-term memory and speed of information processing. (20)(38) A strong association between serologically confirmed infection with

Toxocara species and diminished cognitive function has been demonstrated. (10) In a study performed in the United States, children ages 6 through 16 years previously infected with *Toxocara* species had significant reductions in cognitive function in math, reading, block design performance, and verbal digit span compared to noninfected children. (10) In summary, the intestinal helminth infections, schistosomiasis, and toxocariasis are associated with either long-term growth stunting or cognitive deficits that could be permanent. The constellation of physical stunting and cognitive deficits has been linked to decreased productivity and reduced wage earnings in adulthood. (20)(22)(23)(38)(45)

In the majority of worm infections, the host immune system elicits a Th2 response, with increased production of cytokines, specifically interleukin-4 (IL-4), IL-5, IL-9, IL-10, and IL-13, when in contact with the worm or worm products. (46)(47) The increased cytokine release triggers an immune effector response composed of eosinophils and mast cells in tissue and serum and immunoglobulin E antibodies in the

serum. (46)(48) During the acute worm migration through tissue, markedly elevated eosinophilia can be detected. A spontaneous decrease in eosinophil levels in peripheral blood can be seen after worm migration ceases and the worm establishes barriers to the host immune system. Persistent eosinophilia occurs with worms that have continuous tissue invasion and contact with immune effector cells, such as hookworm, *Toxocara*, and *Strongyloides*. Worms that do not have a tissue invasion phase, such as *Taenia*, do not typically create a sustained eosinophilic response. (49)

Specific

The specific and chronic manifestations of each of the helminth infections partly reflect where the parasite resides in its human host (Fig 2). Hookworms typically inhabit the proximal one-third of the small intestine, *Strongyloides* worms are in the duodenum and jejunum, *Ascaris* worms are found in the jejunum and ileum, and *Trichuris* worms and pinworms inhabit the colon. Adult schistosomes live

TABLE 2. **Major Chronic Disease Syndromes Resulting From Worm Infections**

DISEASE	MAJOR SYNDROME OR CONDITION	REFERENCES
Intestinal helminth infections	Growth stunting Cognitive and intellectual deficits	21, 22, 23, 37, 38, 39
Ascariasis	Vitamin A malabsorption Intestinal obstruction Asthma	22, 37, 40
Trichuriasis	Colitis Trichuris dysentery syndrome	22, 23
Hookworm	Anemia	21, 22, 41
Strongyloidiasis	Enteritis Hyperinfection syndrome	40, 42, 43
Enterobiasis	Pruritus ani	24, 25
Schistosomiasis	Growth stunting Cognitive and intellectual deficits Inflammation Anemia	7, 27, 28, 40
Urogenital Schistosomiasis	Hematuria Hydronephrosis Renal failure Female genital schistosomiasis	7, 27, 28
Intestinal Schistosomiasis	Diarrhea Intestinal bleeding Liver fibrosis	27, 28
Toxocariasis	Epilepsy Lung dysfunction Asthma	8, 10, 29
Cysticercosis	Epilepsy	31, 32, 33, 44

in the small veins draining either the small and large intestines (*S. mansoni* and *S. japonicum*) or urogenital organs (*S. haematobium*). *Toxocara* species larvae migrate through the brain and lungs, while *T. solium* larvae in patients with cysticercosis are found in the skeletal muscles, brain, or eye.

Intestinal Helminth Infections

Along with the general growth and cognitive stunting associated with worm infections, intestinal helminth infections exhibit unique clinical manifestations.

Ascariasis can cause both acute and chronic severe infection after oral ingestion of infective eggs. The hatched larvae invade the intestinal mucosa, travel in the systemic blood circulation to the lungs, invade the pulmonary alveoli, and elicit pulmonary inflammation. (22)(50) During the early larval migrations, children may present acutely with nonspecific symptoms of wheezing, cough, dyspnea, hemoptysis, and status asthmaticus due to pulmonary eosinophilic infiltrates. (40) After lung invasion, the larvae pass over the epiglottis, are swallowed, and enter the small intestines. Stool eggs can be detected approximately 6 to 8 weeks after initial infection. (40) Although light infections often produce no symptoms, heavy *Ascaris* infection can cause chronic disease that can present with abdominal pain, abdominal distention, and malabsorption of nutrients, particularly vitamin A. (22)(37) If the worm burden is severe, worm aggregation can create partial obstruction of the small bowel, bowel infarction, and peritonitis. Intestinal obstruction most commonly occurs in the ileum, especially in young children. Adult worms can also enter the lumen of the appendix, leading to appendicitis, or block the ampulla of the common bile duct, leading to cholangitis and

pancreatitis, although this feature is more common in adults. (22)

Trichuriasis causes a form of inflammatory bowel disease in the cecum and elsewhere in the colon. The worm, which consists of both an intracellular and extracellular component, embeds into the colonic mucosa, causing local inflammation at the point of attachment. Moderate infection can subsequently cause colitis that leads to chronic abdominal pain, diarrhea, and decreased nutrient intake, resulting in impaired growth and anemia of chronic disease. (22) In heavy infections, *Trichuris* colitis can lead to a chronic dysentery syndrome that is clinically represented by bloody diarrhea, abdominal pain, tenesmus, severe anemia, protein-energy malnutrition, and cachexia. Heavy worm burden is also associated with rectal prolapse, likely related to straining at defecation or increased peristalsis associated with irritation of colonic nerve endings. (22)(23)

Hookworm larvae penetrate the skin, causing a local erythematous, papular rash and pruritus at the site of entry called "ground itch". (22) The larvae are subsequently carried through the afferent blood circulation to the lungs, penetrate the pulmonary alveoli, ascend the bronchial tree to the pharynx, and are swallowed. (22)(51) The larvae then mature in the small intestines where they elicit eosinophilia as they invade the mucosa. Adult worms extract and feed on host blood. In patients with moderate and heavy worm burden and poor iron reserves, particularly children and women of child-bearing age, chronic blood loss from the small intestines causes iron deficiency and anemia in the host. (41) Heavy hookworm-induced blood loss can also lead to protein losses, producing hypoproteinemia and subsequently anasarca. (21)(22)

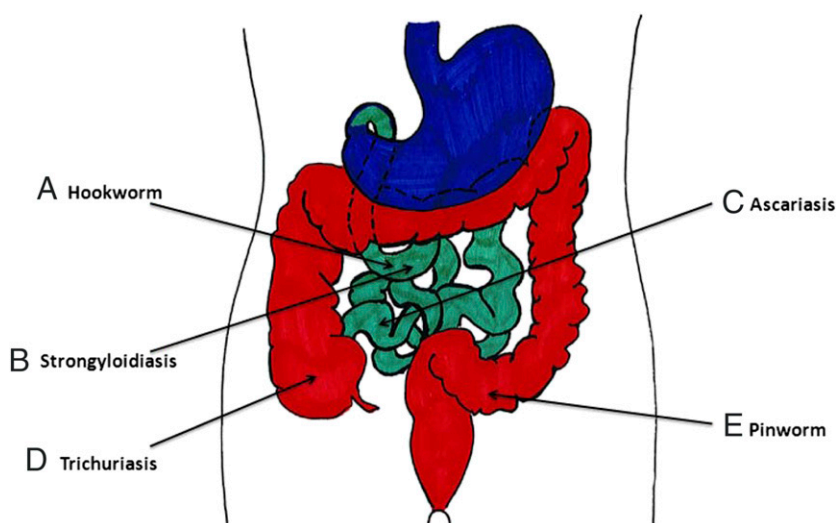


Figure 2. Location of intestinal helminths in the host gastrointestinal system.

A. Hookworm is located in duodenum and jejunum. B. *Strongyloides* is located in duodenum and jejunum. C. *Ascaris* is located in ileum. D. *Trichuris* is located in the cecum. E. Pinworm migrates from the cecum to the perianal area at night to deposit eggs.

Pinworm infections in humans range from asymptomatic disease to benign symptoms such as perianal pruritus. (24)(25) After ingestion of pinworm eggs, the hatched larvae migrate to the colon where they mature into adult pinworms. At night, female worms migrate to the perianal area to deposit eggs. The deposition of eggs on the skin causes perianal irritation in the host. (24) Although rare, serious infections have been reported, including colitis, abscess and fistula formation, and appendicitis. (25)

The diverse clinical manifestations of strongyloidiasis are attributed to the unique life cycle of the worm. Following penetration through the skin, the infective larvae migrate to the lungs by systemic circulation, penetrate into alveoli, ascend the tracheobronchial tree, and are subsequently swallowed, traveling to their final destination in the duodenum. Worms mature into adult females in the small intestines and release eggs, which hatch in the small intestine and give rise to first-stage larvae. While still in the host, these newborn larvae can molt to become infective larvae, which then migrate through the intestinal mucosa, causing autoinfection. (42) Autoinfection may last for years or decades. Although infected patients can have gastrointestinal symptoms, including bloating, nausea, diarrhea, and abdominal pain, approximately 50% remain asymptomatic throughout their lives. (42)(43) However, if a patient with strongyloides infection receives high-dose or long-term corticosteroids (commonly associated with the treatment of lymphoma, receipt of a kidney allograft, or autoimmune disease) or develops human T-lymphocyte virus-1 infection, dysregulation of autoinfection can lead to strongyloides hyperinfection syndrome or disseminated strongyloidiasis. (40) Affected patients exhibit an acute increase in worm migration through the intestinal mucosa, severe damage to the bowel wall, and subsequent enteric bacteremia leading to sepsis or meningitis. (40) Because of this risk, patients from endemic areas should be screened for strongyloidiasis before initiation of corticosteroid therapy. (40) Larval migration through the skin causes a migratory serpiginous rash called "larva currens." (42)(43)

Schistosomiasis

In nonimmune hosts, acute schistosomiasis can result in Katayama fever, which is an acute serum sickness-like illness of fever, malaise, headaches, hepatosplenomegaly, and myalgia that is associated with high morbidity and even mortality. (40) Katayama fever most commonly is seen with acute infection with *Schistosoma japonicum* and *S. mansoni* and less commonly with *S. haematobium*.

For all schistosome species, disease results primarily from chronic local granulomatous inflammation and fibrosis

in reaction to deposited eggs in tissue. However, the location of granuloma formation is species-specific. (27) Adult *S. haematobium* worm pairs reside in the venous plexus surrounding the urinary bladder and deposit eggs in the bladder to cause hematuria and anemia, bladder and urethral fibrosis, hydronephrosis, and late-stage squamous cell bladder carcinoma. (7)(27)(28) Furthermore, in girls and women, *S. haematobium* eggs are deposited in the lower and upper genital tract, leading to dyspareunia, ectopic pregnancy, and infertility. (7) "Sandy patches," mucosal inflammatory reactions to *Schistosoma* eggs, can be grossly visualized in the genital tissue. (7) Recently, female genital schistosomiasis has been shown to increase the acquisition of sexually transmitted disease such as HIV/AIDS. (7)(27) Adult *S. mansoni* and *S. japonicum* reside in the mesenteric veins that drain the intestines. Their eggs cause intestinal schistosomiasis associated with abdominal pain, diarrhea, hematochezia, and protein-losing enteropathy. When *S. mansoni* and *S. japonicum* eggs are swept from the mesenteric to the portal veins and then to the liver, high-intensity infections can result in periportal fibrosis, hepatosplenomegaly, and ultimately portal hypertension and ascites. (27)(28) Spinal and cerebral neuroschistosomiasis can occur when schistosome eggs are carried by the bloodstream to the central nervous system, with subsequent granulomatous lesion formation in neuronal tissue. Spinal neuroschistosomiasis, typically a transverse myelitis affecting the lower thoracic spine, is most commonly due to *S. mansoni* eggs and causes acute myelopathy. Patients can present with low back pain that radiates to the lower extremities and can progress to lower limb weakness and paresthesias, bladder dysfunction, and deep tendon reflex abnormalities. This syndrome is sometimes seen in expatriates working for the first time in Africa. Granulomatous lesions caused by *S. japonicum* eggs most commonly affect the cerebrum, causing focal neurologic deficits, seizures, or acute encephalopathy. (52)

Toxocariasis

Toxocara eggs are ingested, hatch in the duodenum, and migrate via the blood to other organ systems. The severity of the clinical disease appears to depend on the intensity of the infection, site of infection, and intensity of the host immune response as well as patient age. Classic visceral larva migrans is a relatively rare condition that is seen in younger children. Host inflammatory responses to migrating larvae in the liver, lungs, and brain produce a syndrome that includes myalgias, arthralgias, lymph node enlargement, hepatosplenomegaly, eosinophilic meningoencephalitis, and eosinophilic pneumonia. Ocular larva migrans occurs

in older children, often with a single larva migrating to the eye that produces granulomatous tracks on the retina, sometimes associated with detachment. (29) Endophthalmitis can also be present.

As noted previously, acute larva migrans syndromes are rare. More commonly, patients are asymptomatic or have an indolent chronic disease, sometimes referred to as covert toxocariasis. Children with covert toxocariasis may present with reduced lung function and episodic wheezing that can be confused with asthma exacerbations. (8)(10)(29) Covert toxocariasis has also been linked to neurocognitive delays as well as epilepsy in children. (10) The finding that toxocariasis disproportionately affects African American populations has led to the suggestion that this disease could be linked to the achievement gap among socioeconomically disadvantaged groups in the United States. (53)

Taeniasis and Cysticercosis

T solium infection manifests as taeniasis or cysticercosis, depending on the mode of transmission. In taeniasis, patients ingest cysticercoid cysts in uncooked pork. Following excystation, a parasite scolex attaches to the small intestines in the host and develops into adult tapeworms. (33) Patients infected with adult *T solium* tapeworms typically are asymptomatic carriers. (31) In cysticercosis, patients ingest embryonated *T solium* eggs, which hatch into oncospheres in the intestines. The oncospheres penetrate the intestinal wall and circulate to muscle tissue or the central nervous system where cysts are deposited. (32)(44) Cysts deposited in the central nervous system (neurocysticercosis) can elicit a host inflammatory response, particularly as the cysts are dying, causing foci of seizure activity, epilepsy, and ocular disorders. Patients typically present with partial seizures, severe chronic headaches, intracerebral hypertension, and cognitive behavioral dysfunction. (32)

DIAGNOSTIC TECHNIQUES

Microscopy

Diagnosing worm infections in children depends on the type and location of infection as well as the availability of diagnostic tools. The gold standard and most commonly used technique for evaluation of intestinal helminth and schistosome infections remains microscopy for direct egg detection in the stool and species identification. Several concentration techniques, including sedimentation, centrifugation, and filtration, have been applied to increase the ability to detect infections, particularly in the setting of light worm burden. (22) The Kato-Katz thick smear technique, which evaluates stool samples on specially adapted microscope

slides, is a common microscopic method in resource-limited settings for the quantitative diagnosis of worms when worm intensity must be measured. (22)(24)(28)(54)(55) The FLOTAC technique is a newer microscopic detection technique of helminth eggs in host samples. FLOTAC has been shown to have a higher sensitivity in identifying light infections compared to Kato-Katz. However, FLOTAC requires more expensive laboratory equipment, including a centrifuge and specific flotation solutions to facilitate separation of parasitic elements from fecal debris. Despite the availability of these microscopic techniques in resource-limited settings, both Kato-Katz thick smear and FLOTAC are low-throughput methods for worm diagnosis. (54)(55)

Serology

Serologic enzyme immune assays (EIAs) that measure host antibody to parasite antigens are available for diagnosing a limited number of tissue-invasive worm infections, including toxocariasis and strongyloidiasis. However, they are often performed only at selected specialty laboratories and at the Centers for Disease Control and Prevention (CDC), making them not always easily accessible for clinicians in a busy practice. EIA serology is the only diagnostic assay generally available for toxocariasis. Although the sensitivity, specificity, and positive predictive value for visceral larva migrans are generally good, this is not always true for ocular larva migrans. In addition, there is controversy about whether a positive result represents current infection rather than previous exposure for covert toxocariasis. EIA is considered sensitive and specific for strongyloidiasis, with antibody levels diminishing after effective treatment. (56) Several different antibody-based tests have been developed for schistosomiasis, but they are of varying sensitivity and specificity. The CDC uses a Falcon assay screening test-enzyme-linked immunosorbent assay (FAST-ELISA) with *S mansoni* antigen that has high sensitivity for *S mansoni* and *S haematobium* infections. (56) For cysticercosis, the CDC enzyme-linked immunoelectrotransfer blot using patient serum has a high sensitivity and specificity, but it does not distinguish present from past infections (56) and is often considered a confirmatory test following the appearance of cysticerci on radiographic imaging of the brain or other areas of the central nervous system (although false-negative results can occur in patients with a solitary cyst). (56)

Polymerase Chain Reaction

Due to limitations in microscopy and serologic assay, polymerase chain reaction (PCR)-based assays for intestinal helminths and schistosomiasis are becoming more widely available. (54)(57) PCR has been shown to be more sensitive than direct microscopy for detection of *Ascariasis*

lumbricoides, *Trichuris trichiura*, and *Ancylostoma duodenale*. More recently, a highly sensitive PCR assay has become available for detection of *Schistosoma* DNA in feces, sera, and plasma. (27)(58) The quantitative, multiplex PCR method has an added benefit of detecting poly-parasitism and has been validated against microscopy. (57) However, sensitivity and specificity varies according to the assay used. Newer methods such as Luminex-based assays, a bead-based flow cytometric assay, allow for simultaneous detection of multiple targets, either multiple organisms or different genotypes of one particular organism, with 94.5% sensitivity and 99% specificity. (59) These new methods could play an important role in epidemiologic investigations, such as during outbreaks. (59) PCR-based techniques require high costs for equipment but have been found to be more advantageous in intestinal helminth infections and in schistosomiasis due to higher throughput, ease of use, and increased detection of multiple organisms. (57)

MANAGEMENT AND TREATMENT

United States and Other Nonendemic Countries

In the United States and other nonendemic countries such as Europe and Japan, children with helminth infections are generally treated after establishing a specific diagnosis. However, there are some exceptions for children emigrating from highly endemic areas, including CDC recommendations on refugees from Sudan (“the lost boys and girls of Sudan”) and Somalia, who benefit from presumptive treatment for schistosomiasis (with praziquantel) and strongyloidiasis (with either ivermectin or albendazole). (60)

The recommended treatment regimens for the major pediatric helminth infections are provided in Table 3. A few noteworthy caveats include the finding that albendazole and mebendazole are not always equivalent for treating helminth infections. Albendazole is metabolized after absorption, and the resulting bioactive metabolite can distribute widely in human tissues, making it a drug of choice for the larval helminth infections of toxocariasis and cysticercosis as well as for most of the intestinal helminth infections. (61)(62) In contrast, mebendazole is not appreciably absorbed outside the intestine and can be considered a first-line drug when used in a single dose only for ascariasis and enterobiasis. Prolonged courses of albendazole or mebendazole are required to treat trichuriasis (61)(62) and mebendazole for hookworm. Combination therapies using albendazole and ivermectin can also be used for trichuriasis. (62) Both albendazole and mebendazole can cause transient abdominal pain, nausea, or diarrhea in children who are infected with large numbers of worms.

Ivermectin is a first-line treatment for strongyloidiasis, except in patients who immigrate to the United States from countries where loiasis (a filarial infection caused by *Loa loa*) is endemic; in these cases, albendazole is the drug of choice. (60) The reason for this finding is that ivermectin has been reported to produce a toxic encephalopathy in patients with high concentrations of *L loa* microfilariae in their circulations. In children with *Strongyloides* hyperinfection, a rare condition in the United States, prolonged or repeat courses of ivermectin or combination therapy with ivermectin and albendazole may be required. (61)(62) In some cases, even parenteral ivermectin treatment regimens are required. (61)(62) Children emigrating from *Strongyloides*-endemic areas (possibly including Appalachia in the United States) who require large or prolonged doses of corticosteroids (eg, for autoimmune conditions, solid organ transplants, or hematologic conditions) should be screened to evaluate their risk of *Strongyloides* hyperinfection and treated with ivermectin before beginning corticosteroid-based therapies.

Oral therapy with praziquantel is usually effective for schistosomiasis. In patients experiencing acute schistosomiasis that produces a serum sickness-like syndrome known as Katayama fever, corticosteroids may also be required. (62)

Of all of the helminth infections, cysticercosis has the most complicated treatment guidelines. Treatment differs between children with solitary versus multiple cysts, and seizures often result from host inflammation around dead or dying cysts in the brain. Strong evidence supports the use of anthelmintic drugs in children with multiple cysts, especially when there is radiographic evidence that the cysts are viable. (63) Corticosteroids are required for such children to reduce the resulting inflammation in the central nervous system. (62) Moreover, these children should be managed in consultation with a pediatric neurologist and/or neurosurgeon because the medicines themselves could precipitate seizures as additional cysts are destroyed, with resulting host inflammation in the brain. (62) Depending on the location of the cysts, neurosurgical intervention may be required. (62) Additional new evidence indicates that patients with a solitary cyst or lesion benefit from anthelmintic therapy using albendazole. (63) Albendazole has reduced the number of seizures and hastened the resolution of the lesions and resulting granuloma in such patients. (63) Prolonged anthelmintic chemotherapy, such as that used for cysticercosis, creates the potential for toxicities to the liver, bone marrow, cutaneous, and other target organs, and patients should be monitored accordingly. (62)

TABLE 3. Recommendations for Anthelmintic Treatment in the United States and Other Nonendemic Countries

DISEASE	FIRST-LINE MEDICATION AND DOSE	SECOND-LINE MEDICATION AND DOSE	REFERENCES
Ascariasis	Albendazole 400 mg PO once (taken with food/fatty meal, not FDA-approved for this indication) OR Mebendazole 100 mg PO bid × 3 d OR Mebendazole 500 mg PO once	Ivermectin 150–200 mcg/kg PO once (not FDA-approved for this indication; safety in young children <15 kg and in pregnancy not established) Pyrantel pamoate 11 mg/kg (maximum 1 g) PO × 3 d	61, 62
Trichuriasis	Albendazole 400 mg PO × 3–7 d (taken with food/fatty meal, not FDA-approved for this condition) OR Mebendazole 100 mg PO × 3–7 d	Ivermectin 200 mcg/kg/d PO × 3 d (not FDA-approved for this indication; safety in young children <15 kg and in pregnancy not established; should be taken on an empty stomach with water) Some synergy combining albendazole with ivermectin reported in the literature	61, 62
Hookworm infection	Albendazole 400 mg PO once (taken with food/fatty meal; not FDA-approved for this condition) OR Mebendazole 100 mg PO × 3 d	Pyrantel pamoate 11 mg/kg (maximum 1 g) PO daily × 3 d (not FDA-approved for this indication)	61, 62
Strongyloidiasis	Ivermectin 200 mcg/kg/d PO × 2 d (in children from areas where <i>Loa loa</i> infection is not co-endemic, i.e., Somalia; safety in young children <15 kg and in pregnancy not established; should be taken on an empty stomach with water) In patients suspected of having <i>Strongyloides</i> hyperinfection, prolonged (7–14 d after clearance of the parasite) or repeat courses may be required or parenteral administration may be required using veterinary formulations	Albendazole 400 mg PO bid × 10–14 d (in children from areas where <i>Loa loa</i> infection is co-endemic, ie, Sudan; taken with food/fatty meal; not FDA-approved for this condition) OR Albendazole and ivermectin combined in patients with <i>Strongyloides</i> hyperinfection	61, 62
Enterobiasis	Albendazole 400 mg PO once (taken with food/fatty meal, not FDA-approved for this condition); repeat in 2 wk OR Mebendazole 100 mg PO once; repeat in 2 wk	Pyrantel pamoate 11 mg/kg (maximum 1 g) PO once (not FDA-approved for this indication); repeat in 2 wk	61, 62
Schistosomiasis			
Urinary tract schistosomiasis (<i>S haematobium</i>)	Praziquantel 40 mg/kg/d PO in 2 doses × 1 d (taken with liquids during a meal)		61, 62
Intestinal schistosomiasis (<i>S mansoni</i>)	Praziquantel 40 mg/kg/d PO in 2 doses × 1 d (taken with liquids during a meal)	Oxamniquine 20 mg/kg/d PO in 2 doses × 1 d (Latin America and Caribbean region only; higher doses over 2–3 d may be required for Africa)	61, 62
Asian schistosomiasis (<i>S japonicum</i> , <i>S mekongi</i>)	Praziquantel 60 mg/kg/d PO in 3 doses × 1 d (taken with liquids during a meal)		61, 62
Toxocariasis	Albendazole 400 mg PO bid × 5 d (taken with food/fatty meal; not FDA-approved for this condition) For ocular larva migrans, 400–800 mg PO twice a day for 28 d Concomitant corticosteroids may be required and doses adjusted accordingly		61, 62

Continued

TABLE 3. (Continued)

DISEASE	FIRST-LINE MEDICATION AND DOSE	SECOND-LINE MEDICATION AND DOSE	REFERENCES
Cysticercosis	Albendazole 400 mg PO twice a day for 2–4 wk; can be repeated as necessary pending tests of liver function and blood counts (taken with food/fatty meal); with corticosteroids given before, during, and after treatment to decrease seizure risks Exclude ocular cysticercosis before initiating systemic therapy	Praziquantel 33 mg/kg PO 3 times a day for 1 d followed by 15 mg/kg PO 3 times a day for 2–4 wk, with corticosteroids given before, during, and after treatment to decrease seizure risks Exclude ocular cysticercosis before initiating systemic therapy	61, 62

FDA=U.S. Food and Drug Administration; PO=oral.

Endemic Countries

In developing countries of Asia, Africa, and the Americas, children who require anthelmintic drugs for intestinal helminth infections, schistosomiasis, or both often receive their medicines through organized programs of mass drug administration. Mass drug administration with a single annual dose of either albendazole (400 mg) or mebendazole (500 mg), together with praziquantel (administered as multiple tablets based on use of a height pole), became a standard practice for ministries of health in developing countries and their nongovernmental organization partners beginning in 2001. In that year, the member states of the World Health Assembly adopted a resolution to provide children with access to these anthelmintics, with a goal of deworming up to 100% of children by the year 2010. (62) Fundamental to this resolution was the excellent safety profile of anthelmintic drugs for use in children, with the recognition that in areas of high endemicity, it was acceptable to administer these medicines without first establishing a diagnosis for each child. Instead, the World Health Organization (WHO) established guidelines and algorithms for administering albendazole/mebendazole and praziquantel on the basis of the known prevalence and intensity of helminth infections in the community. (64) This low-cost approach, sometimes referred to by WHO as “preventive chemotherapy,” obviated the need for trained microscopists (because individual diagnoses were not determined) or even health professionals because the medicines could be safely administered by schoolteachers or community health workers. For example, in communities where the prevalence of intestinal helminth infections among children exceeds 50%, the recommendation is to provide children with at least a single annual dose of albendazole or mebendazole, with additional threshold targets set for schistosomiasis. (64) Further, in areas where the prevalence of intestinal helminth infections exceeds 70% (with a high percentage of moderate or heavy infections), twice or even thrice annual deworming are recommended on the presumption that the level of community

transmission is extremely high and reinfection occurs within a few months after treatment. (64) In practice, however, even achieving annual treatments can pose challenges in many resource-poor settings.

Among the projected benefits for annual deworming are improvements in childhood growth and physical fitness, anemia, intelligence and cognition, and school performance. Some studies even have demonstrated significant economic returns from deworming, including gains in future wage earnings. (65) Moreover, the cost-effectiveness of annual deworming is extremely high because the major pharmaceutical companies donate the medicines. This approach was challenged in a 2012 Cochrane Database Systematic Review, which could not confirm many of the benefits of regular and periodic deworming, (66) although some have suggested that there is a paucity of randomized trial data and limitations to the Cochrane approach itself. (66)

GLOBAL CONTROL AND ELIMINATION

Almost 15 years after the World Health Assembly resolution on deworming, WHO data indicate that only 30% of children who require access to albendazole or mebendazole actually receive these drugs for intestinal helminth infections, (18) while only 14% of adults and children receive praziquantel for schistosomiasis. (5) An important ongoing international effort to increase global coverage for helminth infections relies on bundling deworming programs for intestinal helminth infections and schistosomiasis with control and elimination programs for other neglected tropical diseases, including lymphatic filariasis, onchocerciasis, and trachoma. (67) In this approach a “rapid-impact” package of medicines is provided, which includes albendazole or mebendazole, praziquantel, ivermectin, and azithromycin. (67)(68) Since 2006, partial or complete rapid impact packages have now reached more than 450 million people in Africa, Asia, and Haiti through support from the United

States Agency for International Development's Neglected Tropical Disease program (www.neglecteddiseases.gov). Additional people and countries are being reached through support from the British Government's Department of International Development. Still another positive development to promote deworming is a 2012 London Declaration for Neglected Tropical Diseases, in which the major pharmaceutical companies reaffirmed their commitment to donate anthelmintic drugs.

Even if coverage rates in poor countries improve considerably, there is no consensus about whether this approach would lead to the elimination of intestinal helminth infections or schistosomiasis because of ongoing transmission and high rates of posttreatment reinfection. Therefore, integration of water, sanitation, and hygiene programs are paramount for envisioning effective control. (69) Even then, as noted previously, a single dose of albendazole or mebendazole is effective in curing ascariasis, but multiple doses are required to cure trichuriasis and hookworm infection (although a single dose of these medicines would reduce the number of whipworms and hookworms). A systematic review confirms the low cure rates achieved by currently available single-dose anthelmintics for trichuriasis and hookworms. (70) Whether these low efficacies might reflect some emerging drug resistance has been hypothesized but not yet proven. Adding ivermectin or a drug known as oxfantel-pamoate provides additional benefit for curing trichuriasis but not hookworm infection. (15)(68)(71) Accordingly, there is interest in developing new and improved anthelmintic drugs (15) and parallel projects are underway to develop innovative anthelmintic vaccines. (72)(73)

Summary

- On the basis of research evidence, worm infections are important global child health conditions causing chronic disability that lasts from childhood into adulthood (Table 1). (2)(3) Evidence Quality: B
- On the basis of research evidence, the major worm infections found in developing countries include ascariasis, trichuriasis, hookworm infection, and schistosomiasis; toxocarasis, enterobiasis, and cysticercosis are also found in poor regions of North America and Europe. (4)(9)(13) Evidence Quality: B

- On the basis of expert consensus, children and adolescents are often vulnerable to acquiring large numbers of worms, ie, high-intensity infections (Fig 1)(21)(22)(23) Evidence Quality: D
- On the basis of expert consensus and research evidence, moderate and heavy worm burdens cause increased morbidity because of growth and intellectual stunting in children and adolescents. Many of these effects may result from helminth-induced malnutrition. (21)(22)(23) Evidence Quality: C
- On the basis of expert consensus and research evidence, worm infections are also commonly associated with eosinophilia. (48)(49) Evidence Quality: B
- On the basis of research evidence as well as consensus, helminths can cause inflammation in the lung (asthma), gastrointestinal tract (enteritis and colitis), liver (hepatitis and fibrosis), and urogenital tract. (7)(21)(22)(23)(27)(28)(40)(41)(43) Evidence Quality: B
- On the basis of research evidence, microscopy techniques for diagnosis of worm infections in children often exhibit suboptimal sensitivities and specificities, necessitating new or improved diagnostic modalities such as polymerase chain reaction. (54)(55) Evidence Quality: A
- On the basis of research evidence and expert consensus, mass drug administration ("preventive chemotherapy") has become a standard practice for ministries of health in low- and middle-income countries to control intestinal helminth infections and schistosomiasis. (67)(68) Evidence Quality: B

References for this article are at <http://pedsinreview.aappublications.org/content/36/8/341.full>.

To view PowerPoint slides that accompany this article, visit <http://pedsinreview.aappublications.org> and click on the Data Supplement for this article.

Worm Infections in Children

Jill E Weatherhead MD

Peter J Hotez MD PhD



PIR Quiz

1. You are working in an impoverished community in Mississippi. Many of the children do not wear shoes and many animals roam the streets. A mother brings her 4-year-old son to see you in clinic because of recurrent seizures. He had a generalized tonic-clonic seizure earlier this morning that lasted 3 minutes, after which he had a brief postictal period. He has been afebrile and the mother denies any photophobia, stiff neck, or upper respiratory tract infection symptoms. On examination, the child is alert and awake and you find no focal findings. Of the following, which disease has been linked to neurocognitive delays and epilepsy in children living in some impoverished areas of the United States?
 - A. Enterobiasis.
 - B. Hookworm disease.
 - C. Schistosomiasis.
 - D. Strongyloidiasis.
 - E. Toxocariasis.
2. You are discussing the effects of helminth infections in young children with a group of medical students. Which of the following is a true statement regarding the effects of helminth infections on children?
 - A. Chronic ascariasis in childhood is associated with the development of epilepsy later in life.
 - B. Cognitive testing in children with heavy hookworm infection shows results similar to those in uninfected children.
 - C. High-intensity worm infection in children can have long-term effects on pediatric physical and cognitive development.
 - D. One common complication of helminth infections in young children is the development of visual impairment.
 - E. Severe hookworm infections are associated with vitamin A deficiency.
3. A 7-year-old girl presents to your office for a routine health supervision visit. She and her family recently emigrated from rural Guatemala. The mother reports that the child often complains of vague abdominal pain and does not eat well. On physical examination, the thin, pale, moderately malnourished girl is in no distress. Her abdomen is mildly distended but soft and there is no hepatosplenomegaly. The rest of her physical examination findings are within normal limits. Hemoglobin measures 8 g/dL (80 g/L). Of the following, which is the most likely infection in this child?
 - A. Ascariasis.
 - B. Hookworm disease.
 - C. Neurocysticercosis.
 - D. Pinworm infection.
 - E. Strongyloidiasis.
4. A 16-year-old teen presents to the emergency department after a first-time generalized tonic-clonic seizure. His mother reports that he has no past medical history of seizures and there is no family history of epilepsy. She tells you that the family is originally from Brazil and the teen lived there until he was 10 years old. Computed tomography scan of the brain reveals multiple calcified cysts in both parieto-occipital regions. You suspect neurocysticercosis. The mother asks how he could have acquired the disease. Of the following, the best response to her question is that the boy likely:
 - A. Had infective larvae penetrate through the skin that subsequently circulated to the central nervous system.
 - B. Ingested adult worms that subsequently migrated via the lymphatic system to the central nervous system where eggs were deposited in brain tissue.
 - C. Ingested embryonated eggs, which hatched into oncospheres, penetrated the intestinal wall, and circulated to the central nervous system.
 - D. Ingested infective larvae from contaminated water supplies, which then developed into adult worms in the intestines and migrated and embedded into brain tissue.
 - E. Ingested uncooked pork that contained larvae, and the ingested larvae then circulated to the central nervous system.

REQUIREMENTS: Learners can take *Pediatrics in Review* quizzes and claim credit online only at: <http://pedsinreview.org>.

To successfully complete 2015 *Pediatrics in Review* articles for AMA PRA Category 1 Credit™, learners must demonstrate a minimum performance level of 60% or higher on this assessment, which measures achievement of the educational purpose and/or objectives of this activity. If you score less than 60% on the assessment, you will be given additional opportunities to answer questions until an overall 60% or greater score is achieved.

This journal-based CME activity is available through Dec. 31, 2017, however, credit will be recorded in the year in which the learner completes the quiz.

5. You are seeing a 5-year-old boy and his family for the first time in your office. They recently emigrated from a refugee camp in West Africa. The parents report that the child has had diffuse abdominal pain, occasional bloody diarrhea, and anorexia for more than 1 month. You perform microscopic examination of a stool specimen and detect *Schistosoma* eggs. Which of the following drugs is the treatment choice for this infection?
- A. Albendazole.
 - B. Ivermectin.
 - C. Mebendazole.
 - D. Praziquantel.
 - E. Prednisone.

Parent Resources from the AAP at HealthyChildren.org

- <http://www.healthychildren.org/English/health-issues/conditions/skin/pages/Pinworms.aspx>
- Spanish: <http://www.healthychildren.org/spanish/health-issues/conditions/skin/paginas/pinworms.aspx>
- <https://www.healthychildren.org/English/health-issues/conditions/from-insects-animals/Pages/Hookworms.aspx>
- Spanish: <https://www.healthychildren.org/spanish/health-issues/conditions/from-insects-animals/paginas/hookworms.aspx>
- <https://www.healthychildren.org/English/health-issues/conditions/from-insects-animals/Pages/Tapeworms.aspx>
- Spanish: <https://www.healthychildren.org/spanish/health-issues/conditions/from-insects-animals/paginas/tapeworms.aspx>
- <https://www.healthychildren.org/English/health-issues/conditions/skin/Pages/Ringworm.aspx>
- Spanish: <https://www.healthychildren.org/spanish/health-issues/conditions/skin/paginas/ringworm.aspx>
- <https://www.healthychildren.org/English/health-issues/conditions/from-insects-animals/Pages/Roundworm-Ascariasis.aspx>
- Spanish: <https://www.healthychildren.org/spanish/health-issues/conditions/from-insects-animals/paginas/roundworm-ascariasis.aspx>

Worm Infections in Children
Jill E. Weatherhead and Peter J. Hotez
Pediatrics in Review 2015;36;341
DOI: 10.1542/pir.36-8-341

Updated Information & Services	including high resolution figures, can be found at: http://pedsinreview.aappublications.org/content/36/8/341
References	This article cites 71 articles, 12 of which you can access for free at: http://pedsinreview.aappublications.org/content/36/8/341#BIBL
Subspecialty Collections	This article, along with others on similar topics, appears in the following collection(s): Medical Education http://pedsinreview.aappublications.org/cgi/collection/medical_education_sub Journal CME http://pedsinreview.aappublications.org/cgi/collection/journal_cme Infectious Diseases http://pedsinreview.aappublications.org/cgi/collection/infectious_diseases_sub International Child Health http://pedsinreview.aappublications.org/cgi/collection/international_child_health_sub Public Health http://pedsinreview.aappublications.org/cgi/collection/public_health_sub
Permissions & Licensing	Information about reproducing this article in parts (figures, tables) or in its entirety can be found online at: http://pedsinreview.aappublications.org/site/misc/Permissions.xhtml
Reprints	Information about ordering reprints can be found online: http://pedsinreview.aappublications.org/site/misc/reprints.xhtml

American Academy of Pediatrics

DEDICATED TO THE HEALTH OF ALL CHILDREN™





Celebrating
35 Years

Pediatrics in Review

An Official Journal of the American Academy of Pediatrics

Worm Infections in Children

Jill E. Weatherhead and Peter J. Hotez

Pediatrics in Review 2015;36;341

DOI: 10.1542/pir.36-8-341

The online version of this article, along with updated information and services, is located on the World Wide Web at:

<http://pedsinreview.aappublications.org/content/36/8/341>

Data Supplement at:

<http://pedsinreview.aappublications.org/content/suppl/2015/07/23/36.8.341.DC1.html>

Pediatrics in Review is the official journal of the American Academy of Pediatrics. A monthly publication, it has been published continuously since 1979. Pediatrics in Review is owned, published, and trademarked by the American Academy of Pediatrics, 141 Northwest Point Boulevard, Elk Grove Village, Illinois, 60007. Copyright © 2015 by the American Academy of Pediatrics. All rights reserved. Print ISSN: 0191-9601.

American Academy of Pediatrics

DEDICATED TO THE HEALTH OF ALL CHILDREN™

