

# Early Puberty

Priyanka Bakhtiani, MD,\*<sup>†</sup> Mitchell Geffner, MD\*<sup>†‡</sup>

\*Keck School of Medicine of the University of Southern California, Los Angeles, CA

<sup>†</sup>Children's Hospital Los Angeles, Los Angeles, CA

<sup>‡</sup>The Saban Research Institute, Children's Hospital Los Angeles, Los Angeles, CA

## EDUCATION AND PRACTICE GAPS

- Primary care providers should be aware of secular trends in the timing and tempo of puberty, including variations between different racial and ethnic groups.
- Pubertal staging should be a part of annual routine pediatric patient visits.
- Children with normal variations in pubertal timing should be distinguished from patients with pathological precocious puberty.
- Because immediate access to a pediatric endocrinologist may not always be possible or necessary, primary care providers should be familiar with the initial evaluation and counseling for children with early puberty.

## OBJECTIVES *After completing this article, the reader should be able to:*

- Describe the physiologic process of puberty, including the key factors that determine onset and tempo of puberty.
- Document sexual maturity ratings and anticipate the course of pubertal progression.
- Recognize normal variations of puberty, including benign premature thelarche and benign premature adrenarche.
- Plan investigations according to a logical differential diagnosis for precocious puberty.
- Identify when a patient should be referred to a pediatric endocrinologist.
- Counsel patients and families about expected treatment for precocious puberty.

## INTRODUCTION

Puberty is defined as the process of gonadal maturation and development of secondary sexual characteristics, which culminates in reproductive competence. Anatomically, the main sites involved in pubertal maturation are the hypothalamus, anterior pituitary gland, and gonads (ovaries or testes), known collectively as the hypothalamic-pituitary-gonadal (HPG) axis. Also, there is critical communication between adipose tissue and the hypothalamus mediated by the hormone leptin.

**AUTHOR DISCLOSURE:** Drs Bakhtiani and Geffner have disclosed no financial relationships relevant to this article. This commentary contains a discussion of an unapproved/investigative use of a commercial product/device.

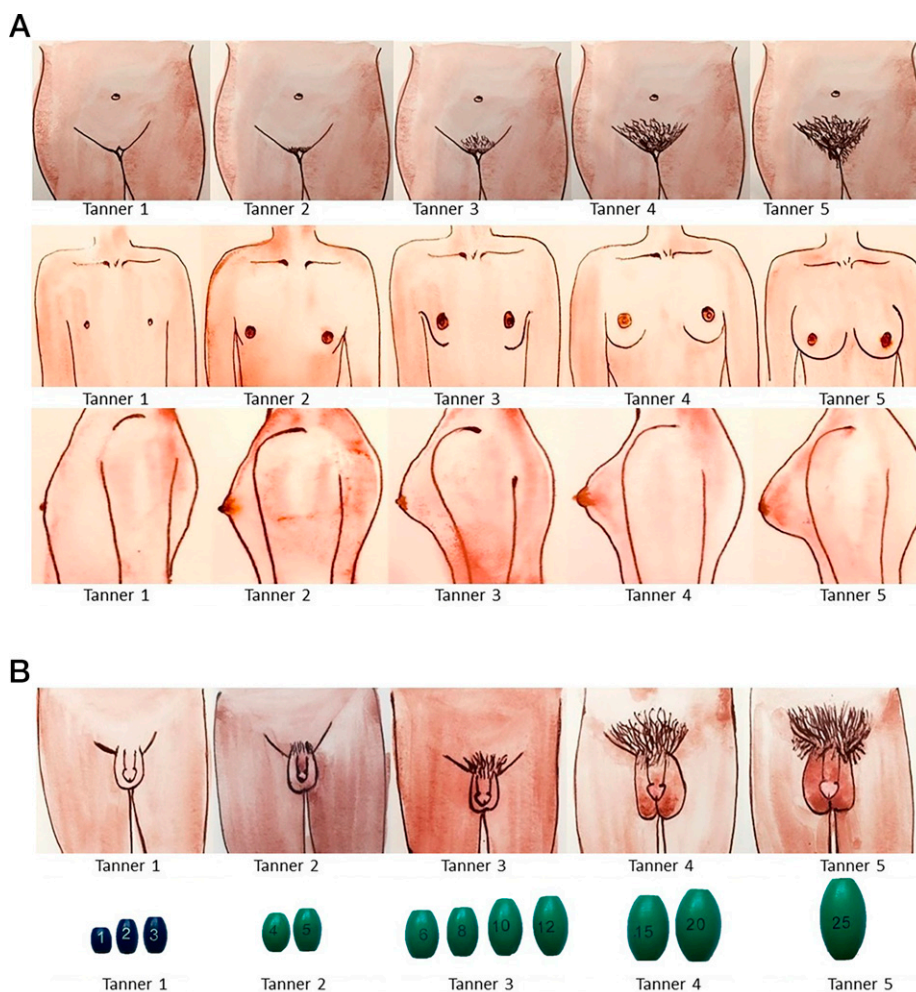
## ABBREVIATIONS

CPP	central precocious puberty
GnRH	gonadotropin-releasing hormone
GnRH-a	gonadotropin-releasing hormone agonist
hCG	human chorionic gonadotropin
HPG	hypothalamic-pituitary-gonadal
IPA	idiopathic premature adrenarche
LH	luteinizing hormone
MRI	magnetic resonance imaging
NCCAH	nonclassic congenital adrenal hyperplasia

## NORMAL PHYSIOLOGY

Gonadotropin-releasing hormone (GnRH) is secreted from the arcuate nucleus of the hypothalamus into the portal circulation, from where it is carried to the anterior pituitary gonadotrophs. Here it acts on GnRH receptors to signal release of the gonadotropins: luteinizing hormone (LH) and follicle-stimulating hormone. Leptin, released by adipose tissue, acts as a metabolic checkpoint for reproductive function, with early puberty often found in states of obesity, and delayed puberty in states of thinness.

Pulsatile secretion of GnRH is regulated by a synchronized interplay of stimulatory and inhibitory factors collectively known as the GnRH pulse generator. This includes kisspeptin-neurokinin-dynorphin neurons in the arcuate nucleus of the hypothalamus that produce kisspeptin (a potent GnRH secretagogue), along with neurokinin B (increases KISS1 expression) and dynorphin (inhibits kisspeptin release). Augmentation of GnRH pulses and gonadotropin secretion initially occurs during sleep, with extension to daytime as puberty progresses. Makorin-ring-finger-protein 3 (MKRN3)



**Figure 1.** Sexual maturity rating, commonly known as Tanner staging, for girls (A) and boys (B). (2)(3) Pubic hair (both sexes) is defined by the following Tanner stages: 1, no pubic hair; 2, scant hair on the labia in girls and at the base of the penis in boys; 3, coarse hair extending to the mons; 4, dense terminal hair filling the entire pubic triangle; and 5, hair on the inner thigh or extending to the lower abdomen. In girls (A, middle and bottom rows), breast development starts as a bud (Tanner stage 2), followed by formation of a peripheral mound (Tanner stage 3). The peak growth spurt in girls occurs between Tanner stages 2 and 3 of breast development. Tanner stage 4 is characterized by a secondary areolar mound ("double contour" where the areolar mound is lifted off the surface of the breast), which eventually disappears into the contour of the mature breast (Tanner stage 5). In boys (B), prepubertal testicles are less than 3 mL (Tanner stage 1). With onset of puberty, the testicular volume increases (3–5 mL) bilaterally and the skin of the scrotum thins and reddens (Tanner stage 2). In Tanner stage 3, testicular volume is 6 to 12 mL, with further scrotal enlargement and lengthening of the penis. Tanner stage 4 is indicated by testicular volume of 12 to 20 mL, with scrotal enlargement and darkening, and Tanner stage 5 is indicated by testicular volume greater than 20 mL, with adult appearance of scrotum and penis. It takes approximately 4 years for boys to reach adult testicular volumes of 20 to 25 mL. Adapted with permission from Muir A. Precocious puberty. *Pediatr Rev.* 2006;27(10):373–381.

acts as a “pubertal brake,” with low circulating levels during minipuberty of infancy, higher levels between ages 1 and 10 years, and low levels again during puberty.

## CLINICAL SIGNS OF PUBERTY (FIG 1)

The first clinically apparent sign of puberty in 85% of girls is breast bud development (thelarche). Thelarche is a surrogate for ovarian enlargement, which is the true first sign of female puberty. In 15% of girls, puberty starts with adrenarche, eg, pubic hair development. (1) Menarche typically occurs approximately 2.25 years (on average) after thelarche. (2) It can take 2 to 5 years for most menstrual cycles to become ovulatory.

Similarly, testicular enlargement to greater than 3 mL is usually the initial sign of puberty in boys. Voice-deepening, peak growth spurt, and increased muscular strength typically occur around Tanner stage 4 for genital development (testicular volumes  $\geq 12$ –20 mL). (3)

Adrenarche, resulting from adrenal androgen production, is biochemically detectable by an increase in production of dehydroepiandrosterone sulfate approximately 1 year before the onset of pubic hair. This is independent of HPG axis activation. Axillary hair typically appears 1 to 2 years after pubic hair development.

## TIMING OF ONSET OF PUBERTY

Ninety-five percent of girls attain thelarche between 8 and 13 years of age, (4) and 95% of boys start testicular enlargement between 9 and 14 years of age. (5) Between the mid-19th and mid-20th centuries, the average menarchal age decreased remarkably from 17 years to younger than 14 years in the United States, thus revealing secular trends toward earlier onset of puberty over time. (6) In general, Black and Hispanic children tend to have pubertal onset earlier than white and Asian children. (5)(6)(7)(8).

## MINIPUBERTY

After birth, in the absence of feedback from placental steroids, the HPG axis becomes temporarily active during minipuberty of infancy. By 1 week of age, gonadotropin levels start increasing and, in response, there is increased secretion of estradiol/testosterone levels, with peak levels seen by 2 to 3 months of age. (9) Minipuberty is thought to represent an essential programming process for genital organ development, fertility, body composition, and cognitive functions later in life.

Clinically, minipuberty is associated with penile growth in boys and enlargement of the uterus in girls. Onset of minipuberty in preterm babies is at a similar postnatal age

as that of term babies, but the degree of HPG axis activation in the former is increased and its duration prolonged.

During the first year after birth, the hypothalamic-pituitary axis becomes increasingly sensitive to negative feedback from low levels of sex steroids produced in response to gonadotropins and enters a long period of relative quiescence (“prepuberty”).

## NORMAL VARIANTS OF EARLY PUBERTY

### Idiopathic Premature Thelarche

Idiopathic premature thelarche refers to benign, self-limited breast tissue development in girls younger than 8 years (most commonly within the first 2 years after birth). No other signs of puberty are present.

Breast enlargement may be bilateral or unilateral, but not beyond Tanner stage 3. Palpation of glandular tissue can usually help distinguish idiopathic premature thelarche from lipomastia, which is common in children with obesity. The cause is unknown, with serum estradiol levels usually in the prepubertal range. Most cases do not progress to true puberty. (10) Thus, clinical monitoring by the primary care provider is usually sufficient. A bone age may be the only routine test warranted. (11) If the child has rapid growth, significant bone age advancement, progressive breast development, and/or other signs of puberty, referral to a pediatric endocrinologist is recommended.

### Idiopathic Premature Adrenarche

Premature pubarche is defined as the appearance of pubic hair, axillary hair, apocrine odor, and/or acne, without breast development, before age 8 years in girls and without testicular enlargement before age 9 years in boys. (12) There is no concomitant virilization, eg, no clitoromegaly in girls and no voice-deepening or penile enlargement in boys. The term *premature adrenarche* refers to early maturation of the zona reticularis of the adrenal cortex, and it is substantiated by a slight increase (up to that seen in Tanner stage 2) in the circulating adrenal-androgen precursor dehydroepiandrosterone sulfate ester. Children with idiopathic premature adrenarche (IPA) are more often female, (13) more frequently Black, and usually taller than expected for age, with mild bone age advancement. IPA is often associated with prematurity, (14) low birthweight (especially if followed by rapid postnatal catch-up growth [15]), and elevated BMI. (16) If a child presents with pubarche after 6 years of age, laboratory or radiologic studies are not routinely warranted. Approximately 4% of children with premature adrenarche have nonclassic congenital adrenal hyperplasia (NCAH) (17) and will

have rapid progression in androgen-mediated pubarche and virilization, an early growth spurt, and undue bone age advancement. An early-morning 17-hydroxyprogesterone level is the initial screening test for NCCAH.

IPA may be a forerunner for future development of polycystic ovarian syndrome (18) in girls, as well as early-onset insulin resistance and metabolic syndrome in either sex. (19)(20)

### Isolated Pubic Hair of Infancy

Isolated occurrence of pubic hair without progression is occasionally seen in infants. Interestingly, in most cases, this pubic hair is in an atypical location, eg, on the scrotal sac in boys and perivaginally in girls. This is a benign variant, with no intervention necessary because resolution usually occurs spontaneously. (21)

### Premature Menarche

Vaginal bleeding without other manifestations of puberty in girls before age 9 years is a rare but usually normal variant. It can be diagnosed as such only after other causes are excluded, including foreign body, vulvovaginitis, sexual abuse, local mass, severe primary hypothyroidism, and McCune-Albright syndrome. Occasionally, rupture of a functional ovarian cyst can cause a few self-limited episodes of vaginal bleeding.

### Rapid-Tempo Puberty

Puberty starting at a normal age but progressing more quickly than expected has been associated with familial patterns; having been born small for gestational age; accelerated early childhood growth; and other factors, including adoption, endocrine disruptors, and treatment of hypothyroidism. Given that rapid-tempo puberty may be associated with reduced height outcomes and psychological distress, affected adolescents are often treated (off-label) with either a GnRH agonist (GnRH-a) or, in boys, an aromatase inhibitor. However, there are no proven effective treatments, especially because epiphyseal fusion may be near-complete by the time of identification. (22)

### Precocious Puberty (Fig 2)

Most pediatric endocrinologists use 8 years in girls and 9 years in boys as general cutoff ages to separate early-normal from precocious puberty but also recognize that a personalized approach is required, especially for Black girls aged 6 to 8 years, white girls aged 7 to 8 years, and all boys aged 8 to 9 years. (23) In these age ranges, pathological causes of

precocious puberty are rare but have occasionally been noted (especially in those with rapid-tempo puberty).

### Central Precocious Puberty

Central precocious puberty (CPP) results from early maturation of the HPG axis. Isolated thelarche can be the initial presentation in girls. However, the presence of *both* thelarche and adrenarche usually indicates central precocity. In females, historically, approximately 80% of CPP was considered idiopathic, but use of magnetic resonance imaging (MRI) has revealed a slightly higher percentage of pathological findings. In contrast, only approximately 10% of male CPP cases are idiopathic.

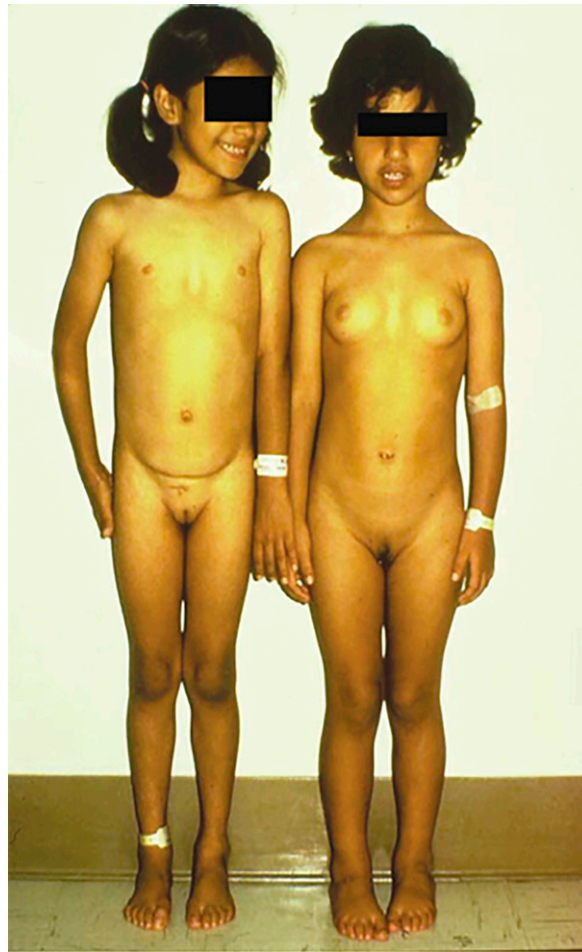The most concerning causes of CPP are hypothalamic-pituitary tumors. (24) Fortunately, the most frequently encountered mass is a hypothalamic hamartoma, a benign developmental malformation consisting of tumorlike masses in the tuber cinereum. Affected patients may present with gelastic (laughing) or other seizures and/or developmental delay. Other brain tumors that may cause CPP (possibly with other pituitary hormone deficiencies) include glial cell and germ cell tumors and, occasionally, craniopharyngiomas and pinealomas.

Other causes include congenital anatomical defects in the suprasellar region (eg, subarachnoid cysts, arachnoidoceles, and Rathke cleft cysts), other midline brain anomalies (eg, hydrocephalus, meningocele, and optic nerve hypoplasia), cranial irradiation, meningoencephalitis, moderate to severe head trauma, and perinatal insults. (25) In neurofibromatosis type 1, CPP may occur with or without an associated hypothalamic optic glioma.

CPP may also emerge in the setting of untreated peripheral causes of puberty (see the next subsection) because of secondary HPG activation from elevated circulating sex steroid levels. Another cause of sexual precocity is van Wyk-Grumbach syndrome, where CPP develops in the backdrop of long-standing untreated primary hypothyroidism. (26)

Children adopted from abroad are noted to have increased risk of CPP, although inaccurate birthdates may confound this. (27)

Recently, a few monogenic causes of CPP have been reported, (28) including activating variants of the genes encoding kisspeptin (*KISS1*) and its receptor (*KISS1R*) and loss-of-function variants in the imprinted genes *MKRN3* (the most common cause of familial CPP) and *DLK1* (encoding delta-like noncanonical Notch ligand 1).



**Figure 2.** Precocious puberty. The stark impact of early pubertal onset is demonstrated, with a 5-year-old prepubertal girl (left) standing next to her 3-year-old biological sister (right) with central precocious puberty, which is characterized by concurrence of thelarche, pubarche, and tall stature secondary to advanced bone age.

### Peripheral Precocious Puberty (29)

The term *peripheral puberty* refers to puberty originating independent of HPG axis activation, eg, from aberrant primary gonadal or adrenal sex steroid secretion, human chorionic gonadotropin (hCG)–producing tumors, or exogenous sources.

In boys, Leydig cell tumors, and gain-of-function variants in the LH receptor gene (familial testotoxicosis) (30) can cause gonadotropin-independent testicular maturation. Tumors secreting hCG (eg, hepatoblastomas and germ cell tumors) can cause precocious puberty as the hCG can bind to LH receptors on Leydig cells, leading to significant testosterone production. (31) Rarely, feminizing Sertoli cell tumors are associated with Peutz-Jeghers syndrome in boys.

In girls, premature estrogen production may result from autonomously functioning ovarian cysts (32) or granulosa cell tumors. Another rare cause is McCune-Albright

syndrome, which is more common in girls than in boys and is characterized by the clinical triad of polyostotic fibrous dysplasia, irregularly bordered (“coast of Maine”) café-au-lait spots, and multiple autonomous endocrinopathies (most often gonadotropin-independent precocious puberty, but also hyperthyroidism, gigantism, and hypercortisolemia). Girls typically present as toddlers with early vaginal bleeding before or soon after breast development.

Premature and inappropriate hyperandrogenism in either sex may occur secondary to CAH or NCCAH (most commonly due to 21-hydroxylase deficiency), androgen-secreting adrenal adenomas or carcinomas, and some cases of Cushing syndrome.

Exogenous exposure to sex steroids in the form of transdermal estrogen/testosterone or environmental phytoestrogens can lead to the development of isosexual or contrasexual secondary sexual characteristics. (33)



## EVALUATION (FIG 3)

When evaluating a child with early signs of puberty, the initial goals are to quantify the degree of pubertal development (Tanner staging), assess the rate of pubertal progression, quantify height velocity, exclude normal variants, uncover whether observed pubertal changes have an idiopathic or pathological basis, and if pathological, distinguish between central and peripheral processes.

The initial test to be performed by the primary care provider is a bone age (left-hand radiograph), which provides an index of the potency and duration of the process but not the cause. Specifically, if the bone age is within 2 SD of the child's chronological age, and not associated with significant height acceleration, it suggests a normal variant, a process of short duration, and/or slow progression. In contrast, if the bone age is significantly advanced, a laboratory evaluation (with additional imaging as indicated by the physical examination findings) must be initiated. Referral to a pediatric endocrinologist is strongly recommended.

### Central Precocious Puberty

Measurement of early-morning serum LH and estradiol levels, using ultrasensitive assays at an experienced commercial laboratory, should be undertaken if early breast development is evident in a girl. Pelvic ultrasonography can be a useful adjunctive tool to determine ovarian and uterine volumes. (34) The presence of bilaterally enlarged ovaries for age suggests hypothalamic-pituitary activation or, less likely, McCune-Albright syndrome. In boys, early bilaterally symmetrical testicular enlargement is usually indicative of central stimulation, which may be confirmed with early-morning measurements of ultrasensitive LH and testosterone levels.

Because gonadotropin secretion is pulsatile and initially sleep-entrained, random daytime measurements of LH and follicle-stimulating hormone levels may be low despite central activation. If CPP is still clinically suspected, a GnRH stimulation test should be performed. (35) The premise behind this test is that the pituitary gonadotrophs in a prepubertal child are minimally responsive to exogenous GnRH. With central pubertal onset, endogenous hypothalamic GnRH "primes" the pituitary gonadotrophs, causing a significant release of LH and subsequently estradiol or testosterone on administration of exogenous GnRH.

With confirmed and progressive CPP, a contrast-enhanced brain/sella MRI is recommended to identify the cause. In girls with onset of puberty between 6 and 8 years of age, or in those with a family history of CPP, provider discretion may be used because the incidence of clinically

relevant intracranial pathology is low. (36) Normal free  $T_4$  and thyrotropin levels rule out van Wyk-Grumbach syndrome.

### Peripheral Precocious Puberty

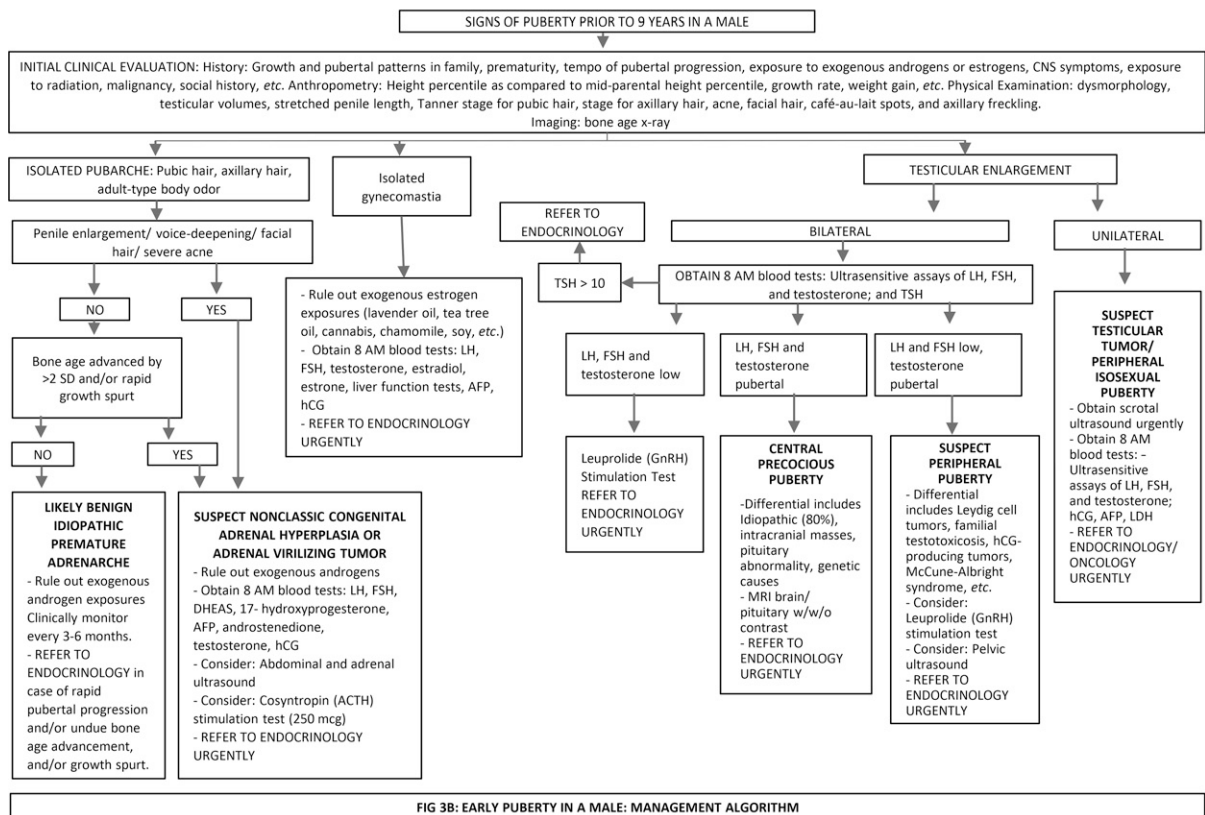
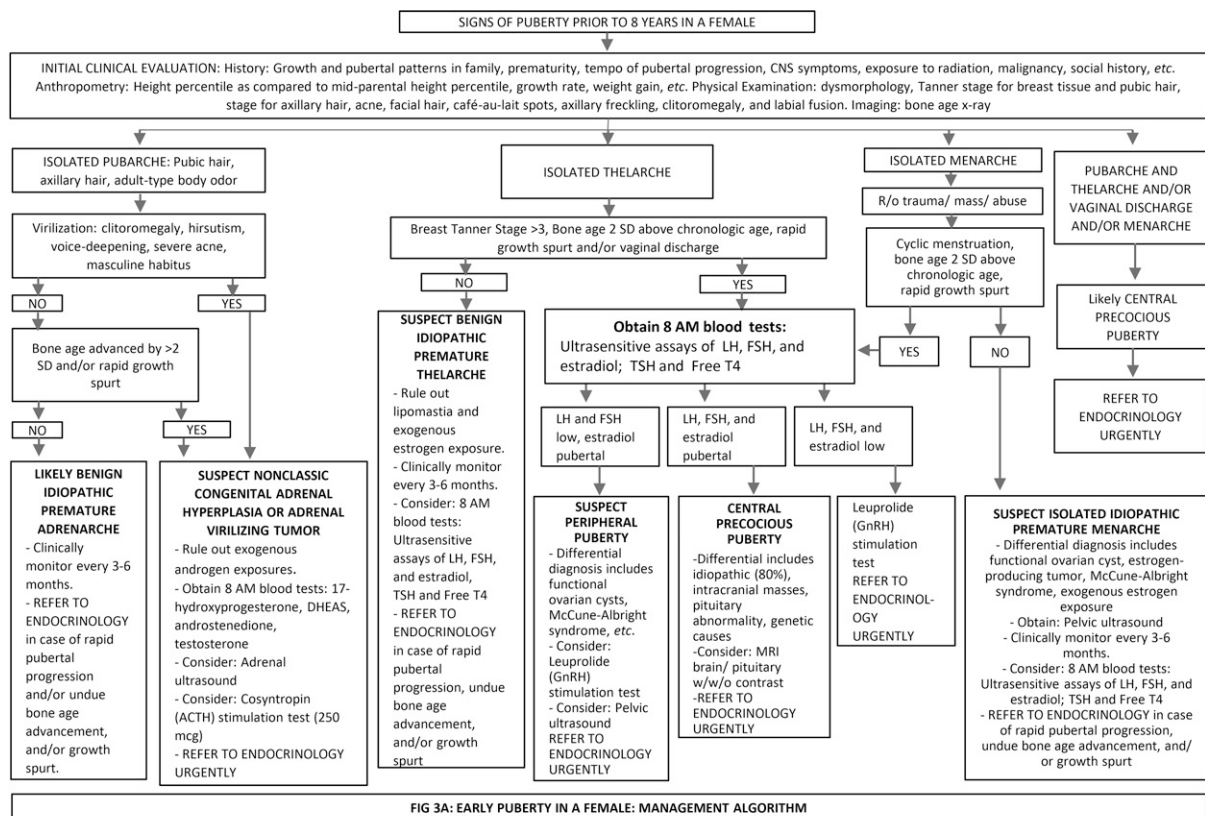
When peripheral puberty is suspected, targeted laboratory testing should be performed. For example, if a girl presents with virilization only, evaluation consists of measurement of serum levels of total testosterone and 17-hydroxyprogesterone, the former an index of the severity of the process and the latter a screening test for CAH due to 21-hydroxylase deficiency. With androgen-specific pubertal signs, rapid weight gain, and other clinical features, Cushing syndrome must be considered. If biochemical testing suggests an adrenal or ovarian tumor, performance of an abdominal/pelvic MRI is mandatory. Measurement of serum gonadotropin/estradiol levels and brain MRI are not indicated in the evaluation of virilization in girls.

Testicular size and symmetry will guide the evaluation for a boy with peripheral puberty. If the testes are prepubertal and symmetrical, the androgen source must be extratesticular, ie, adrenal glands or exogenous exposure. With unilateral testicular enlargement, an androgen-producing tumor in the enlarged testis is likely, for which imaging (usually starting with ultrasonography) is warranted. If both testes are mildly enlarged for age and CPP has been ruled out, familial testotoxicosis and hCG-secreting tumors must be considered. In case of familial testotoxicosis, there is often a positive paternal history in conjunction with elevated testosterone and suppressed gonadotropin levels in the patient. hCG-producing tumors cause sexual precocity in males only, especially when predisposed to germ cell tumors (eg, Klinefelter syndrome).

## TREATMENT (37)(38)

### Central Precocious Puberty

The goal of therapy is to block secretion of gonadotropins, thus lowering circulating levels of sex steroids. This is accomplished by administration of a GnRH-a, which desensitizes the pituitary gland to endogenous GnRH (after initial stimulation during the first 1–2 months of use) through downregulation of GnRH receptors. In the United States, available GnRH-a include intramuscular depot injections of leuprolide acetate monthly or every 3 months (39), histrelin acetate subcutaneous implant, (40) intramuscular triptorelin pamoate every 6 months, (41) and subcutaneous leuprolide acetate every 6 months. (42) GnRH-a treatment typically halts but does not reverse existing physical changes of puberty.



**Figure 3.** Algorithms for the evaluation of early puberty in a girl (A) and a boy (B).

The main reasons for initiating treatment include preservation of genetic height potential and prevention or amelioration of psychological distress (eg, from menstruation at a young age). Not all patients with CPP require treatment. Children with slowly progressive CPP or early-normal puberty with a strong familial basis may profit from a period of observation without treatment, especially if other affected family members are not significantly short. The ultimate decision to treat involves careful assessment on a case-by-case basis. (43)

The data on efficacy of GnRH-a therapy in adult-height preservation of girls with idiopathic CPP are inconsistent, particularly when pubertal onset is close to the normal age of puberty, (44)(45)(46), which is, in fact, most currently treated cases. In addition, serious psychological effects of early puberty are rare, and there are conflicting data on whether treatment minimizes the stress. (47)

Monitoring of GnRH-a therapy consists of clinical assessments every 3 to 6 months, with semiannual bone age evaluation. Routine monitoring of gonadotropin or sex steroid levels is controversial, as are the optimal conditions under which such monitoring should occur, eg, randomly, with GnRH stimulation testing, or 1 hour after GnRH-a dosing. (48)(49) Furthermore, the biochemical definition of suppressed puberty is unclear. The optimal duration of GnRH-a treatment varies from patient to patient, although most pediatric endocrinologists cease therapy by age 11 years in girls and 12 years in boys. Once GnRH-a therapy is discontinued, restoration of the HPG axis usually occurs within 12 months. There is a tendency toward overweight/obesity with the use of GnRH-a in children, although elevated BMI is often present before treatment. (50) Thus, a healthy lifestyle during and after GnRH-a treatment is advisable. In addition, there may be a heightened risk of future polycystic ovarian syndrome in girls with CPP. Posttreatment bone density seems unaffected.

### Peripheral Precocious Puberty

Treatment should be targeted to the underlying peripheral etiology, eg, surgical removal of steroid- or hCG-producing tumors would almost always be the first step when present, followed by additional treatment, as directed by a pediatric oncologist. Large ovarian cysts can be drained under ultrasonographic guidance or surgically. Illicit or unintentional transfer of exogenous estrogens or androgens should be

eliminated. GnRH-a therapy is effective only in patients with CPP.

Familial testotoxicosis can be challenging to treat, with options including antiandrogen medications or aromatase inhibitors. (51) NCCAH is treated with glucocorticoids (usually hydrocortisone in children) to prevent ongoing overproduction of androgens. Girls with precocious puberty secondary to McCune-Albright syndrome are treated with aromatase inhibitors or estrogen receptor modulators. (52)

## Summary

- Based on moderate research evidence in the past and current consensus, (1)(2)(3)(4)(5) the generally accepted normal age for pubertal onset is 8 to 13 years in girls and 9 to 14 years in boys. However, with secular trends toward earlier pubertal onset, especially in Black girls, individualized assessment is crucial. There is moderate evidence to support this. (6)(7)(8)
- Based on strong research evidence, (10)(11)(12)(13)(14)(15)(16)(17)(18)(19)(20)(21)(22) normal variants of early puberty include idiopathic isolated premature thelarche and idiopathic isolated premature adrenarche. No treatment is mandatory for these.
- Bone age radiography is usually the first step in investigation of early puberty. Based on moderate research evidence and consensus, (53)(54) biochemical assessment for a central etiology involves early-morning luteinizing hormone, follicle-stimulating hormone, and estradiol/testosterone levels, followed by gonadotropin-releasing hormone stimulation testing and imaging, as indicated.
- Based on moderate research evidence, (23)(24)(25) central precocious puberty is usually idiopathic in girls and pathological in boys. Treatment, when appropriate, is with a gonadotropin-releasing hormone agonist.

References for this article can be found at  
<https://doi.org/10.1542/pir.2021-005059>.





1. A 10-year-old girl seen in the clinic for a health supervision visit has had menstrual periods of 4 to 5 days' duration since menarche 6 months earlier. She has sexual maturity rating (SMR) 4 for breasts and pubic hair development. A medical student reviews the health record and reports that breast budding was noted at age 7 years and pubic hair SMR 2 was noted at age 8 years. Her BMI has consistently been at the 95th percentile since age 5 years. A discussion with the medical student about factors that influence the timing of puberty in girls would most likely include which of the following statements?
  - A. White girls have earlier pubertal onset than Hispanic girls.
  - B. Endocrine disruptors have been associated with slow tempo of puberty.
  - C. Mother's age at menarche is a poor predictor of pubertal onset and menarche.
  - D. Obesity is associated with early-onset puberty.
  - E. Small for gestational age at birth is associated with late-onset puberty.
2. A 6-year-old girl has breast development first noticed by her mother 1 month earlier. She was born at term and was appropriate for gestational age. She has no known history of exogenous estrogen exposure. On examination in the supine position the right breast has palpable firm subareolar tissue that does not extend beyond the areolar margin. The left breast has no palpable breast bud. Examination of her external genitalia shows no enlargement of the labia minora or clitoris, no discharge, and no pubic hair. There is no axillary hair or odor. Review of her growth chart shows that her height and BMI at this visit and since age 3 years have consistently been between the 75th and 85th percentiles for age. Which of the following is the best next step in the evaluation of this girl?
  - A. Assay of ultrasensitive luteinizing hormone (LH) level.
  - B. Measurement of thyrotropin level.
  - C. Observation for tempo of pubertal progression.
  - D. Ultrasonography of the breasts.
  - E. Urgent referral to endocrinology.
3. A 7-year-old boy has axillary hair and coarse pubic hair that extends horizontally across the base of the penis. There is no penile enlargement. The scrotum is small, and the testes bilaterally are 2.0 mL in volume. His height and BMI for age are at the 75th and 85th percentiles, respectively. Which of the following is the best next step for the evaluation of this patient?
  - A. Abdominal/pelvic ultrasonography.
  - B. Review of growth chart to assess for recent height, weight acceleration.
  - C. Early-morning measurement of ultrasensitive LH level.
  - D. Measurement of serum human chorionic gonadotropin level.
  - E. Urgent referral to endocrinology.

**REQUIREMENTS:** Learners can take *Pediatrics in Review* quizzes and claim credit online only at: <http://pedsinreview.org>.

To successfully complete 2022 *Pediatrics in Review* articles for *AMA PRA Category 1 Credit™*, learners must demonstrate a minimum performance level of 60% or higher on this assessment. If you score less than 60% on the assessment, you will be given additional opportunities to answer questions until an overall 60% or greater score is achieved.

This journal-based CME activity is available through Dec. 31, 2024, however, credit will be recorded in the year in which the learner completes the quiz.



2022 *Pediatrics in Review* is approved for a total of 30 Maintenance of Certification (MOC) Part 2 credits by the American Board of Pediatrics (ABP) through the AAP MOC Portfolio Program. *Pediatrics in Review* subscribers can claim up to 30 ABP MOC Part 2 points upon passing 30 quizzes (and claiming full credit for each quiz) per year. Subscribers can start claiming MOC credits as early as October 2022. To learn how to claim MOC points, go to: <https://publications.aap.org/journals/pages/moc-credit>.

4. A 6-year-old boy has SMR 3 pubic hair development, and his testicles are bilaterally 4 mL in volume. He has no café-au-lait lesions and no family history of neurofibromatosis type 1. Review of his growth indicates that he has experienced height acceleration. Which of the following is the best next step in the evaluation of this patient?
- A. Clinical monitoring for tempo of pubertal progression.
  - B. Early-morning measurement of ultrasensitive LH level.
  - C. Gonadotropin-releasing hormone (GnRH) stimulation testing.
  - D. Scrotal ultrasonography.
  - E. Serum level of 17-hydroxyprogesterone.
5. An 8-year-old girl has central precocious puberty. Her breasts are SMR 3 and her height is at the 90th percentile. There is no family history of early puberty or short stature. She has not had vaginal bleeding; however, leukorrhea has been present for 2 months. Her parents are considering for their daughter treatment with a GnRH agonist. Counseling about GnRH agonist treatment for girls with central precocious puberty should include a discussion about which of the following effects of this treatment?
- A. Decreases serious psychological effects of early puberty/menarche.
  - B. Halts but does not reverse breast development.
  - C. Increases future risk of osteoporosis.
  - D. Increases future risk of polycystic ovarian syndrome.
  - E. Is required to prevent short adult stature.