

Concerning Newborn Rashes and Developmental Abnormalities: Part I: Common and Benign Findings

Sophia Reyes-Hadsall, BS,^{*,†} Lily Park, DO,^{‡,§} Alejandra Frauenfelder, MD,^{‡,¶} Folasade F. Fayiga, MS,^{*,†,¶} Ana Graneiro, MD,[†] Ana M. Duarte, MD^{†,‡,§,**,††}

^{*}University of Miami Miller School of Medicine, Miami, FL

[†]Division of Dermatology, Department of Pediatrics, Nicklaus Children's Hospital, Miami, FL

[‡]Department of Dermatology, Larkin Community Hospital, South Miami, FL

[§]Nova Southeastern University, Fort Lauderdale, FL

[¶]Wright State University Boonshoft School of Medicine, Fairborn, OH

^{**}Children's Skin Center, Miami, FL

^{††}Florida International University, Miami, FL

^{‡‡}Department of Pediatrics, Nicklaus Children's Hospital, Miami, FL

EDUCATION GAP

Clinicians must be adept at discerning and managing newborn skin findings.

OBJECTIVES *After completing this article, readers should be able to:*

1. Describe physiologic and benign newborn skin findings, newborn pigmented lesions, and developmental abnormalities seen in the newborn period.
2. Describe benign pustular dermatoses, eczematous dermatitis, pustular eruptions, and transient popular lesions and differentiate key features in clinical presentations.
3. List the appropriate diagnosis and management options for newborn skin findings.
4. Describe signs associated with vascular anomalies that require further management and evaluation for associated syndromes.

INTRODUCTION

During the neonatal period, defined as the first 28 days after birth, the newborn's skin undergoes a variety of changes. Although rashes in the newborn are common and usually transient and benign, certain findings may represent underlying pathologic processes and warrant further investigation. These rashes may represent a source of concern for parents and caretakers, resulting in increased visits to the clinician. For this reason, clinicians must be adept at discerning newborn rashes and how to manage them.

AUTHOR DISCLOSURE: Dr. Duarte is a speaker for Pfizer, Sanofi Regeneron, and Pierre Fabre; the other authors have disclosed no financial relationships relevant to this article. This article does not contain a discussion of an unapproved/investigative use of a commercial product/device.

ABBREVIATIONS

ACC	aplasia cutis congenita
CALMs	café au lait macules
CDM	congenital dermal melanocytosis
ETN	erythema toxicum neonatorum
EPF	eosinophilic pustular folliculitis
HCC	Harlequin color change
HSV	neonatal herpes virus
IH	infantile hemangioma
KOH	potassium hydroxide
PWB	port wine birthmark
TNPM	transient neonatal pustular melanosis
UG	umbilical granuloma

This review has the objective of describing both benign newborn skin findings and findings with underlying systemic involvement in a 2-part series. Our goal is to synthesize a general review of the cutaneous conditions in neonates that will help clinicians prepare for the American Board of Pediatrics Maintenance of Certification as well as take care of persons with these findings. This first volume will mainly focus on benign eruptions, tumors, and cutaneous variations, characterizing their presentation, typical course, risk factors, relevant management, and potential long-term consequences. The second volume will focus on select topics on congenital infections, ichthyosis, vascular malformations, neurocutaneous disorders, blistering disorders, and midline lesions that occur in the newborn period.

NEWBORN SKIN FEATURES

Newborn skin differs from adult skin in a variety of ways. The epidermis of the newborn is thinner, contains fewer cell attachments, and is characterized by flatter dermoepidermal junctions (less undulating Rete ridges) with lower melanin and lipid concentrations. (1) In terms of functionality, there are fewer sweat glands and natural moisturizing factor density, as well as increased water content and higher pH. (1) In addition, a newborn's skin is exposed to normal mechanical stress, new flora, and temperature alterations. (2) Because of these features, newborn skin is more susceptible to infection and chemical or thermal damage and subsequently has a higher risk of heat loss. Furthermore, the skin of the newborn has greater permeability to topical agents, leading to increased absorption. For this reason, newborn skin must be treated with care. (1)

NEWBORN SKIN FINDINGS

Physiologic Desquamation (Appearing at Age 24–48 Hours)

Physiologic desquamation is a superficial desquamation that occurs in most newborn infants, with a diagnosis reported in up to 65% to 75% of newborns. (1) A study examining cutaneous findings in hospitalized newborns identified physiologic desquamation as the most common finding. (3) Postterm birth in the newborn has been associated with increased desquamation. Desquamation occurs within the first 24 to 48 hours after birth, with peak intensity between postnatal days 6 and 10. (1) Physiologic desquamation presents as scaling arising on the hands and feet that may spread gradually (Fig 1 A and B). In postterm infants, scaling may be more generalized. However, diffuse and significant desquamation may prompt consideration of other processes, such as ichthyosis vulgaris, continual skin peeling syndrome, and hypohidrotic ectodermal dysplasia. (4) Identifying

nonphysiologic desquamation depends on family history (family history of aforementioned desquamative disorders), distribution (involvement of majority of skin surface area and/or mucous membrane), and appearance (increased thickness and size) of scale. (5) However, desquamation is usually self-resolving, and treatment is supportive with the use of emollients and barrier protection creams.

Transient Color Changes of the Newborn (Appearing at Age 2–4 Weeks)

Transient color changes of the newborn are often the product of the physiologic adjustments of newborn skin to thermal changes. These physiologic adjustments often lead to skin discoloration referred to as transient vascular phenomena, which are secondary to cold temperature, stress, and immature thermoregulation. (6) Transient color changes are most commonly found between the first 2 and 4 weeks after birth and include Harlequin color change (HCC), acrocyanosis, and cutis marmorata. (6)(7) Separate from vascular-associated phenomena, physiologic jaundice also results in discoloration in the newborn.

HCC of Newborn

HCC of the newborn is a transient unilateral erythema that occurs in ~10% of newborns. (8) This phenomenon is thought to occur because of changes in vascular tone, yet the mechanism remains unexplained. There has been an association between newborns treated with prostaglandins and the development of HCC, given the influence of prostaglandins on peripheral vascular beds. (9) However, most HCC cases develop in the absence of medications. Given HCC's self-limited and transient nature, no treatment is necessary. (10)

Acrocyanosis

In newborns, extremities tend to exhibit a redder/purplish color compared with the central body. (2) Acrocyanosis is a term that describes a bluish symmetric discoloration of the distal extremities usually when the newborn is crying or losing heat owing to immaturity of the vasomotor system. (2)(11) Acrocyanosis is self-limited and can be remedied by providing warmth (eg, via use of warm clothing or ambient temperature increase). (2) Acrocyanosis usually resolves once the newborn ceases to cry or is warmed. (2)

Cutis Marmorata

Cutis marmorata presents as a reticulated violaceous mottling that symmetrically involves the extremities and the trunk (Fig 2A). (6) It follows the same pathophysiologic, transient process of acrocyanosis. Cutis marmorata may

persist for months and into childhood. There is a rare congenital variant called *cutis marmorata telangiectatica congenita*, which presents as fixed reticular violaceous patches in the lower limbs that can persist into adulthood (Fig 2 B and C). (6)(12) There is no treatment indicated for *cutis marmorata*. (6)

Physiologic Jaundice (Appearing within 24 Hours of Age)

Physiologic jaundice is a type of neonatal hyperbilirubinemia that manifests as a mild, transient, and self-limited yellowish discoloration of the skin that typically occurs at approximately the second postnatal day, appearing most commonly in pre-term infants. (13) Neonatal hyperbilirubinemia is classified either as unconjugated hyperbilirubinemia, which is more common and can be either physiologic or pathologic, or conjugated hyperbilirubinemia, which is always pathologic. Immature liver and bilirubin transport systems contribute to unconjugated hyperbilirubinemia. (13) Physiologic jaundice due to unconjugated hyperbilirubinemia is benign and self-limited, appearing after 24 hours and resolving by week 2 or 3 after birth. However, it is imperative to distinguish physiologic jaundice from pathologic jaundice. Jaundice is considered pathologic when it presents within 24 hours after birth, the total serum bilirubin is greater than the 95th percentile for the infant's age, bilirubin levels rise too quickly (>5 mg/dL per day or >0.2 mg/dL per hour), or hyperbilirubinemia persists beyond 2 or 3 weeks. When jaundice meets these criteria, there is increased risk for unconjugated bilirubin to cross the blood-brain barrier, causing bilirubin encephalopathy and kernicterus. Dysfunctional hepatobiliary processes lead to conjugated hyperbilirubinemia, which indicates underlying a medical or surgical cause that must be addressed and promptly treated. (13) Phototherapy is the mainstay of treatment for physiologic jaundice.

BENIGN PUSTULAR DERMATOSES

Pustular dermatoses are prevalent conditions in the newborn, in some cases as high as 90%, with incidence varying by the type of pustular dermatosis. (14) This section highlights and discusses the most common neonatal cutaneous entities and the evaluation for ruling out potential underlying infectious processes in an unhealthy-appearing newborn.

Erythema Toxicum Neonatorum (Appearing at Age 2–3 Days to 2–3 Weeks)

Erythema toxicum neonatorum (ETN) is the most common of the benign pustular dermatoses in newborns, with an estimated incidence between 40% and 70%. (15) ETN

typically appears within the first 2 to 3 days after birth, ranging up to 2 to 3 weeks after birth. Physical presentation is notable for erythematous macules and papules that may evolve into pustules on a blotchy erythematous base, termed “flea-bitten appearance” (Fig 1 A–C). Pustules can be either isolated or clustered. Lesions typically spare acral surfaces. Diagnosis of ETN is made clinically and can be confirmed with a rapid clinical test of a Wright stain and/or Tzanck smear of a pustule, which would predominantly reveal eosinophils and the absence of multinucleated giant cells, ruling out herpes simplex virus (HSV). (14) ETN is self-limited, no treatment is indicated, and the etiology remains unknown. (6)(16)

Transient Neonatal Pustular Melanosis (Appearing within 2 Weeks of Age)

Transient neonatal pustular melanosis (TNPM) is a rare pustular eruption, with a global prevalence of less than 3%. Although it affects both sexes equally, there is a higher prevalence in Black male infants. (17) TNPM is typically present at birth and presents as pustules, vesicles, or pigmented macules 2 to 5 mm in diameter on a nonerythematous base

A

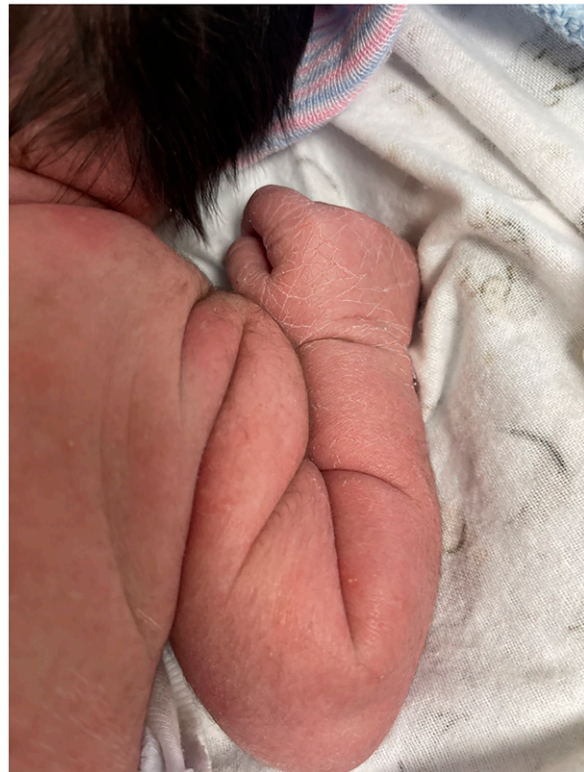

Figure 1A. Neonatal desquamation with concurrent ETN; ETN on the right arm and back. ETN=erythema toxicum neonatorum.

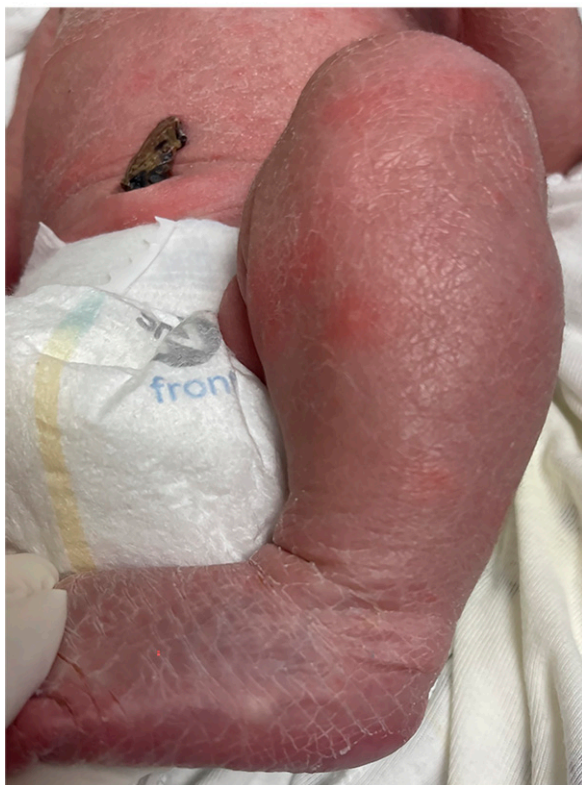B

Figure 1B. Neonatal desquamation with concurrent ETN; ETN on the left leg.

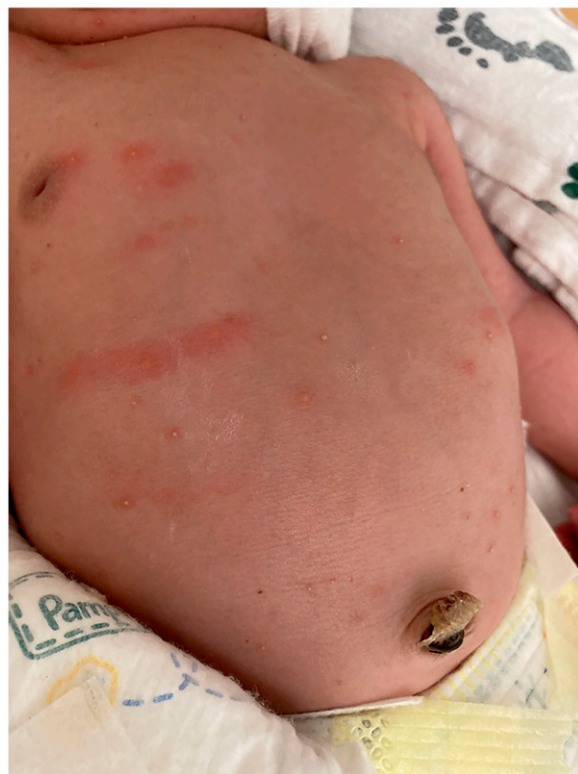C

Figure 1C. Neonatal desquamation with concurrent ETN; NTN on the trunk.

that evolve into a central desquamating crust. A secondary hyperpigmented macule with a collarette of fine scale may persist several days after. At times, the hyperpigmented macule with collarette of scale is the only presentation at birth. TNPM commonly involves the chin, neck, upper chest, sacrum, abdomen, and thighs and spares acral surfaces. Diagnosis is made clinically, although a Wright stain or Tzanck smear of a lesion revealing numerous neutrophils and rare eosinophils is confirmatory and can help to quickly and easily rule out HSV. Lesions typically self-resolve within the first 2 weeks after birth, and treatment is not necessary. (2)(6)(17)

Acropustulosis of Infancy (Appearing Anytime during the Newborn Period or Early Infancy)

Acropustulosis of infancy (also called infantile acropustulosis) is a chronic, recurrent pustular eruption of the palms and soles (rarely affecting the scalp, trunk, buttocks, and extremities). (18) Associated systemic symptoms occurring during the active phase include pruritus and excessive irritability. Acropustulosis can be seen during the newborn period or in early infancy. Because of its

recurring nature, episodes may last 1 to 3 weeks with periods of remission lasting 1 to 3 weeks. Overall, this pustular eruption tends to resolve completely by age 2 to 3 years. (18)(19) The diagnosis is made clinically, and whereas histopathology reveals sterile intraepidermal pustules, Wright stain of a lesion reveals numerous neutrophils and few eosinophils. (14) An association with scabies is well documented, with suspected scabies infection and/or known scabies treatment preceding the eruption. (20) Treatment includes oral dapsone, which provides symptomatic relief in 24 to 48 hours. Topical corticosteroids to the affected areas or oral antihistamines to relieve itch may also be applied. However, in most cases, acropustulosis resolves on its own with no treatment. (19)

Eosinophilic Pustular Folliculitis (Appearing at Age 5–10 Months)

Eosinophilic pustular folliculitis (EPF), formerly known as Ofuji disease, is a rare pustular dermatosis that most commonly occurs in 5- to 10-month-old boys but has been described in the newborn period. (14) EPF presents as a self-limited, recurrent, vesiculopustular eruption of infancy. (21)

Physical presentation is notable for 2- to 3-mm follicular white vesicles and pustules on a red base, commonly on the scalp and forehead with rare involvement of the trunk. Associated systemic symptoms during the active phase are pruritus and irritability. Eruptions can recur for months to years after the initial presentation. Wright stain of a skin lesion reveals large numbers of eosinophils with no bacterial, fungal, or viral organisms. (14) EPF has been linked to immunosuppression in individuals with human immunodeficiency virus; however, the association between infantile EPF in infants seropositive for human immunodeficiency virus is unclear. Infantile EPF has also been associated with atopy. (21) The presence of EPF may also be an early presenting feature of hyper-immunoglobulin E syndrome. (22) Treatment is symptomatic, with topical corticosteroids, oral erythromycin, dapsone, colchicine, indomethacin, and cyclosporine demonstrating efficacy. (14)(21)

Evaluation for Benign Pustular Dermatoses

Benign pustular dermatoses often mimic infectious pustular eruptions, and further evaluation may be necessary to

A

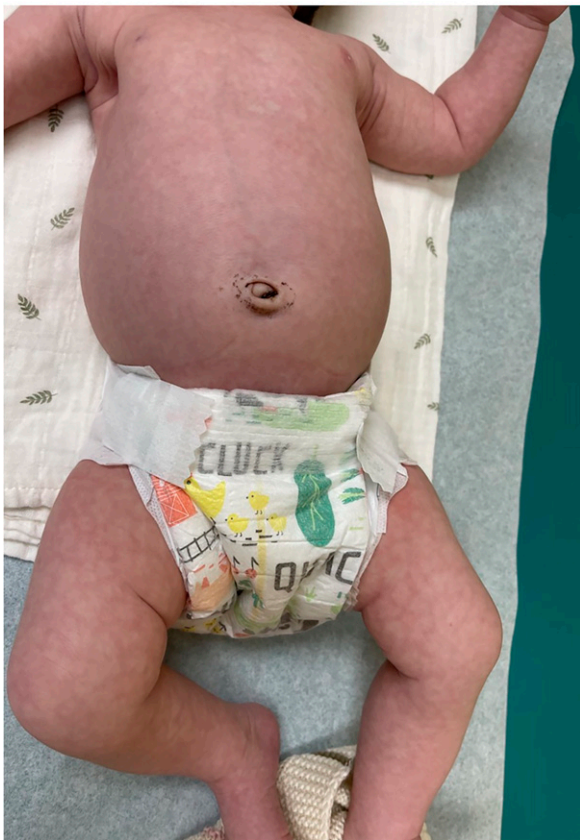

Figure 2A. Cutis marmorata diffusely on the trunk and upper and lower extremities.

B

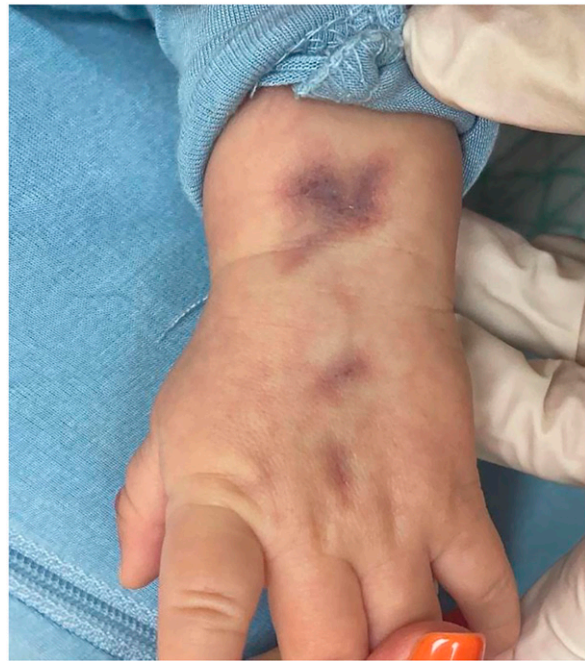

Figure 2B. CMTC on the left dorsal hand and wrist. CMTC=cutis marmorata telangiectatica congenita.

confirm a benign cause. Benign pustular dermatoses are differentiated from HSV infection by the absence of multinucleated giant cells on Wright stain or Tzanck smear.

C

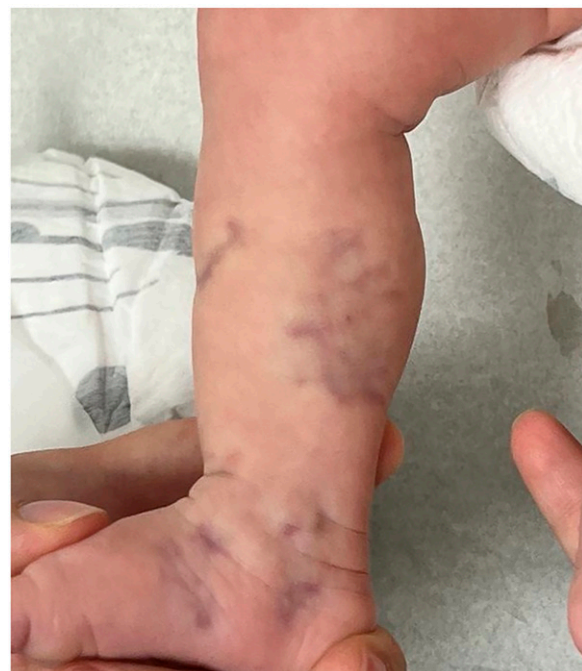

Figure 2C. CMTC on the right medial lower extremity.

Pustular Wright stains and/or Tzanck smears can help by revealing the presence of eosinophils or neutrophils (summarized in Table 1). Negative Gram-stain results and potassium hydroxide (KOH) preparations of skin lesions exclude bacterial and candidal infections, respectively. If the newborn is notably ill, viral and bacterial cultures are indicated. Finally, acropustulosis may appear clinically similar to scabies or syphilis, which can be ruled out by using skin scrapings, looking for ectoparasites, or using syphilis serologies, respectively. (14)

ECZEMATOUS DERMATITIS

Dermatitis, or inflammation localized to the skin, is prevalent in the newborn period and has various causes. This section highlights the most common causes of eczematous dermatitis in the newborn period along with the evaluation, differential diagnoses, and treatment options.

Diaper Dermatitis (Appearing Anytime During the Newborn Period or Early Infancy)

Diaper dermatitis is considered the most common skin disorder of infancy and is usually due to an irritant contact dermatitis. The primary causative factor of diaper dermatitis is moisture or wetness in the diaper area leading to a breakdown of the skin barrier. Diaper dermatitis presents as red, scaly, erosive, irritant reactions confined to the convex surfaces of the perineum, lower abdomen, buttocks, and proximal thighs. Typically, diaper dermatitis spares the intertriginous areas.

Superimposed infection can arise as a complication of irritant contact dermatitis, typically within 48 to 72 hours, and may lead to recalcitrant diaper dermatitis, requiring further evaluation and alternative management. Candidal infection, followed by staphylococcal infection, is the most common infectious etiology. Involvement of the perineum or the presence of satellite lesions (separate and distinct round erythematous patches or plaques) may signal candidal infection (Fig 3). *Candida albicans* has been isolated from 80% of diaper dermatitis with perineal involvement. Erythematous beefiness of the anal area may indicate a

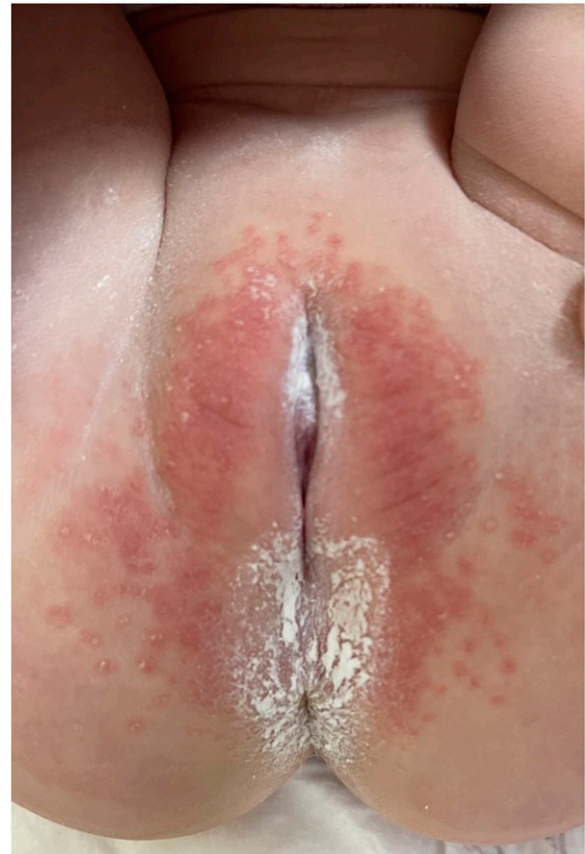

Figure 3. Candidal diaper dermatitis on the female newborn genitalia.

superimposed perianal streptococcal infection. The presence of thin-walled pustules on an erythematous base, yellow-colored crust indicating lesions impetiginized by staphylococcal or streptococcal infection, and a collarette of scale around a red denuded base may also be seen. (23)(24)(25)

Diaper dermatitis with no superimposed infection is typically self-limited, resolving in 3 days. Treatment is aimed at restoring the skin's protective barrier with lubricants (eg, petrolatum) and barrier paste (eg, zinc oxide) and minimizing moisture retention (eg, changing diapers frequently, gentle thorough cleansing). If diaper dermatitis is severe, a tapering course of low-potency topical corticosteroid ointment (eg, hydrocortisone or desonide) in combination with a topical antimonial cream (eg, nystatin cream) may be used. (2)(25) Resistant or persistent irritant contact dermatitis may point to chronic irritant exposure or superimposed infection, the most common of which is candidal. In the case of superimposed candidal infection, diagnosis is clinical, yet a KOH preparation is confirmatory. Treatment involves the use of topical antifungals such as nystatin. If the diaper dermatitis does not improve with the use of antimonial cream in this case, one should consider performing a culture for secondary

Table 1. Wright Stain or Tzanck Smear Findings of Benign Pustular Dermatoses

CONDITION	EOSINOPHILS	NEUTROPHILS
ETN	Numerous	Rare
TNPM	Rare	Numerous
Infantile acropustulosis	Rare	Numerous
EPF	Numerous	Rare

EPF=eosinophilic pustular folliculitis, ETN=erythema toxicum neonatorum, TNPM=transient neonatal pustular melanosis.

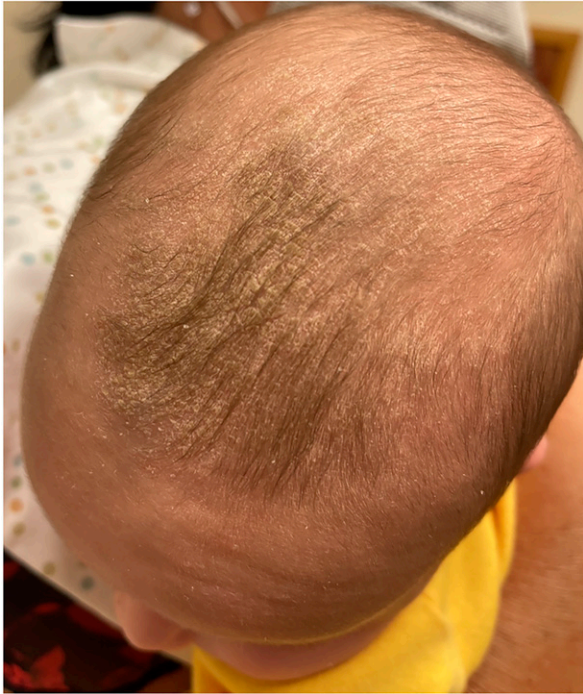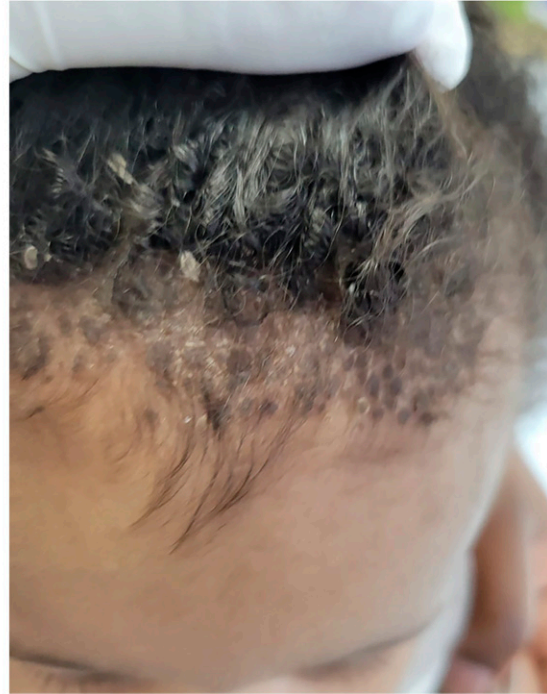A**B**

Figure 4A and B. Seborrheic dermatitis on the scalp.

infections. In the case of staphylococcal or streptococcal infection, infection is confirmed with culture, and Gram-stain of a skin lesion may reveal gram-positive cocci in clusters and the presence of neutrophils. Treatment is the administration of empiric antibiotics. (2)(23) In addition, one can consider less common etiologies such as psoriasis (ie, “napkin dermatitis”), histiocytosis, or Leiner disease (C5 component deficiency), which may require a biopsy for diagnosis. (24)

Seborrheic Dermatitis (Appearing within 2 Months of Age)

Seborrheic dermatitis is an extremely common neonatal rash, often appearing within the first 2 months after birth. It frequently involves the scalp, hence the colloquial name “cradle cap,” but can also involve the face, ears, and neck. Seborrheic dermatitis presents as erythematous patches with greasy, yellow scales that begin in the intertriginous areas, especially the diaper area, axillae, and scalp (Fig 4A-B). Fissuring, maceration, and weeping may also be seen. In darker-pigmented infants, postinflammatory hypopigmentation can be seen, but this is transient and resolves in months. Infants are generally healthy and asymptomatic. Although the exact cause of seborrheic dermatitis is unknown, *Malassezia furfur* has been implicated. Superimposed

infection with *Candida* species or impetigo (infection by *Staphylococcus* species or *Streptococcus pyogenes*) may also occur, requiring treatment with either topical antifungals (eg, topical ketoconazole) or antibiotics. Overall, seborrheic dermatitis may resolve in 2 to 3 months with no treatment

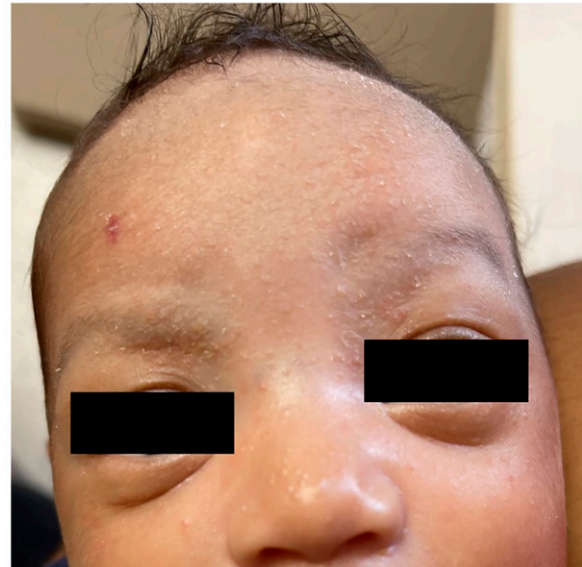C

Figure 4C. Seborrheic dermatitis extending onto the forehead.

but can persist as long as 8 to 12 months. Treatment focuses on applying keratolytics in antiseborrheic shampoos (eg, zinc pyrithione, sulfur, and salicylic acid) and emollients. If the rash is persistent, low-potency topical steroids can also be used. (6)(7)

Atopic Dermatitis (Appearing within the First 2 Years of Age)

Atopic dermatitis is a chronic inflammatory skin condition that is caused by a breakdown of the barrier function of the skin via mutation in the filaggrin protein. (26) More than 20% of children have atopic dermatitis, with more than 60% of cases presenting within the first 2 years of age. Atopic dermatitis presents as pruritic erythematous patches and plaques with resulting excoriation and/or lichenification commonly in the flexural surfaces (ie, antecubital or popliteal fossa) or the cheeks in infants (Fig 5). (27) Atopic dermatitis is highly associated with asthma, and often a history of asthma or atopic dermatitis in a first-degree relative is identified. (27) In addition, peripheral eosinophilia or immunoglobulin E reactivity may be seen. Treatment of atopic dermatitis is aimed at restoring the barrier function of the skin by using emollients or moisturizers (eg, petrolatum) and reducing inflammation with topical steroids

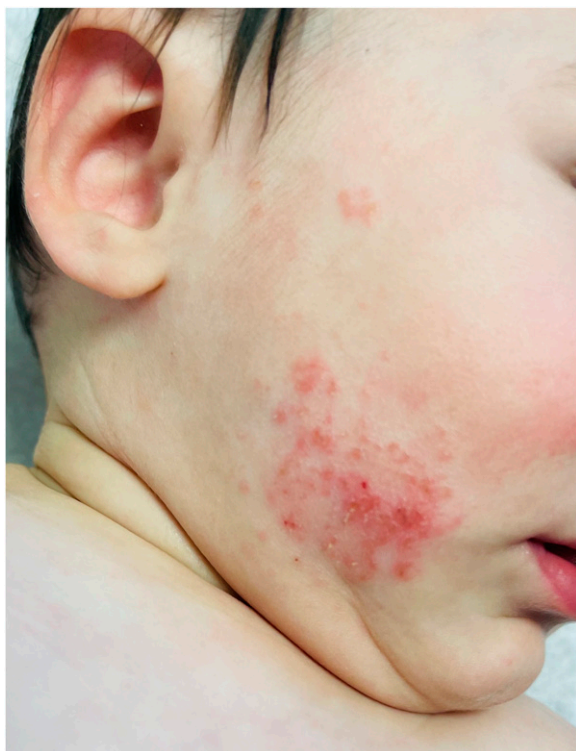

Figure 5. Atopic dermatitis on the right jawline and cheek.

(eg, topical hydrocortisone). Avoiding the use of allergens to the skin is essential; that is, one should avoid using household products with fragrances or harsh chemicals. Lastly, light therapy in the form of narrow-band UV-B has been shown to improve atopic dermatitis. Beyond the newborn period, other medications for the treatment of atopic dermatitis are available.

PUSTULAR ERUPTIONS

Presentations that appear papulopustular with sudden and widespread onset are categorized as pustular eruptions. In this section, pustular eruption etiologies, differential diagnoses, course, and treatment are reviewed.

Neonatal Acne (Appearing at Age 3 Weeks)

Neonatal acne occurs in up to 20% of newborns, typically at age ~3 weeks (although it may appear at birth or early infancy). Neonatal acne presents as predominantly inflammatory red papules and pustules, with rare cysts. Notably there is an absence of comedones, the distinguishing feature of adolescent acne. Neonatal acne typically resolves within 1 to 3 months and is suspected to be caused by colonization of the skin by *Malassezia* species followed by a subsequent inflammatory reaction. Treatment is not necessary because it is self-limited; however, if acne is persistent or severe, topical acne preparations and/or ketoconazole cream may be used. (28)(29)

Infantile Acne (Appearing at Age 3 to 6 Months)

When acne-like lesions occur at age ~3 to ~6 months, these lesions are called infantile acne. Infantile acne is more common in boys and presents in a more pleomorphic fashion compared with neonatal acne. Presentation includes inflammatory papules and pustules, as well as open and closed comedones. Infantile acne resolves by age 3 years and is thought to be triggered by endogenous androgens. (28)(29)

Miliaria (Appearing at Age 1 Week)

Miliaria occurs in term or preterm infants after 1 postnatal week. Miliaria is caused by obstruction of the flow of sweat and rupture of the eccrine sweat duct in response to thermal stress (recalling that newborn skin contains fewer sweat glands). (6) There are 3 subtypes of miliaria. Miliaria crystallina presents as superficial vesicles 1 to 2 mm in diameter on noninflamed skin. Miliaria crystallina occurs when the sweat gland duct is blocked by keratinous debris just beneath the stratum corneum. Miliaria rubra presents as small papules and pustules and occurs when obstruction to the sweat gland occurs in the mid-dermis.

Miliaria profunda presents as deep-seated papulopustular lesions. Miliaria profunda occurs rarely in infancy, and it erupts when the sweat gland duct ruptures at the dermoepidermal junction. (6) Miliaria has a predisposition for the intertriginous areas, scalp, face, and trunk (Fig 6). However, if miliaria occurs in an older infant, it presents in areas occluded by tight clothing. Miliaria is typically self-limited, and treatment is aimed at cooling the skin and using looser clothing. (6)(30)

TRANSIENT PAPULAR LESIONS

Lesions that are transient, papular, and not widespread are characterized as transient papular lesions. Here we describe their key clinical features, overall clinical course, and management.

Sebaceous Gland Hyperplasia (Appearing within 1 Week after Birth)

Sebaceous gland hyperplasia is a common finding in term infants. It presents as yellow papules 1 to 2 mm in diameter and is caused by maternal or endogenous androgenic stimulation of sebaceous gland growth. Sebaceous gland hyperplasia is often self-limited, first appearing within

1 week after birth and resolving in 4 to 6 months, and treatment is not required. (31)

Milia (Appearing within 1 Month after Birth)

Approximately 50% of newborns will experience milia. Milia present as pearly, yellow papules 1 to 3 mm in diameter on the face, chin, and forehead and, rarely, on the trunk and extremities (Fig 7). They may also appear as oral mucosal lesions along the gum border (Bohn nodules) or palate (Epstein pearls). (6)(32) Histology reveals miniature epidermal inclusion cysts arising from the pilosebaceous apparatus of vellus hairs. Typically, lesions resolve within 1 month but may persist for several months. A newborn exhibiting many lesions distributed over a wide area or that persist beyond several months of age may be suggestive of orofacial-digital syndrome or hereditary trichodysplasia (as in Marie Unna hypotrichosis). (33) An increasing number of lesions in areas of normal trauma (eg, acral areas) may be suggestive of scarring epidermolysis bullosa with subtle blistering. (34)(35) No treatment of milia is indicated.

ORAL MUCOSAL CYSTIC FINDINGS

Cystic lesions in the oral mucosa are reviewed in this section, highlighting clinical features to identify the different etiologies.

Epstein Pearls (Appearing within 1 to 2 Weeks of Age)

Epstein pearls are extremely common benign oral mucosal lesions found in ~60% to ~85% of newborns. Epstein pearls are thought to be caused by keratin entrapment

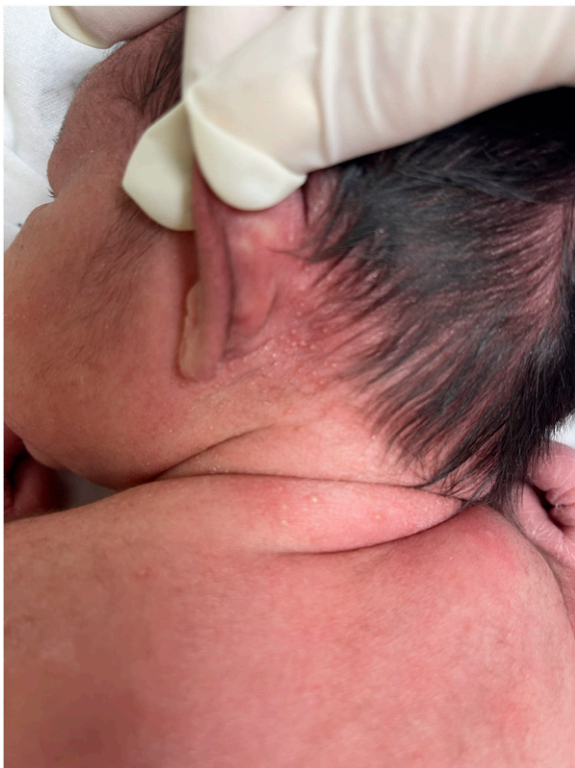

Figure 6. Miliaria seen on left posterior auricular scalp.

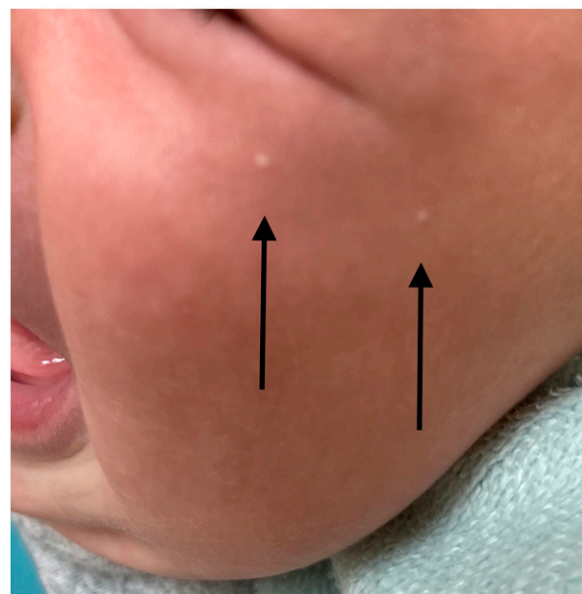


Figure 7. Milia (2) seen on the left upper cheek.

during the fusion of the soft and hard palates in development. Epstein pearls present as small, white-yellow nodules ranging from 1 mm to several millimeters in diameter located in the midpalatal raphe. They are firm in consistency and can be isolated or present in clusters. Diagnosis is clinical, and no laboratory testing or imaging is necessary. These nodules are asymptomatic and self-resolving and do not require further treatment. (34)(36)

Bohn Nodules (Appearing within a Few Weeks of Age)

Bohn nodules are keratin-filled cysts that present on the gingival border. They are thought to be remnants of odontogenic epithelium. Like Epstein pearls, they are also asymptomatic and self-limiting, rupturing spontaneously within weeks to months. Diagnosis is clinical, no additional evaluation is necessary, and treatment is not indicated. (34)(37)

SUBCUTANEOUS FAT NECROSIS OF THE NEWBORN (APPEARING IN FIRST FEW POSTNATAL WEEKS)

Subcutaneous fat necrosis of the newborn is a rare, self-limited form of panniculitis that occurs primarily in term and postterm infants. Although the cause is unknown, it has been associated with total body cooling for treatment of hypoxic ischemic encephalopathy, difficult deliveries, hypothermia, perinatal asphyxia, and maternal diabetes. Subcutaneous fat necrosis occurs within the first few postnatal weeks and presents as discrete, firm, and red or hemorrhagic nodules and plaques up to 3 cm in diameter. Typically, areas that are exposed to trauma (eg, cheeks, back, buttocks, extremities) are involved. The lesions may be tender. Overall, the lesions resolve in 1 to 2 months, which can involve becoming fluctuant, draining, and healing with atrophy. An undesired systemic complication of fat necrosis is calcium deposition both in subcutaneous and extracutaneous tissue. If severe, calcification develops and can be detected on radiography. Hypercalcemia may develop 1 to 4 months after initial detection of subcutaneous fat necrosis, leading to poor weight gain, irritability, nephrocalcinosis, and, potentially, seizures. Other systemic complications seen with subcutaneous fat necrosis include thrombocytopenia, hyperlipidemia, and hyperglycemia. Diagnosis is made clinically, although if performed, histopathology reveals fat necrosis with foreign body giant cell reaction. Needle-shaped clefts are present in the remaining fat cells, and calcium deposits are scattered through the subcutis. Histopathology mimics sclerema neonatorum, which is characterized by diffuse, waxlike hardening of the skin with minimal inflammation of the fat on biopsy. Management of subcutaneous necrosis

of the newborn includes monitoring serum ionized calcium levels, serum creatinine, triglycerides, platelets, and glycemia and performing an abdominal ultrasonography to assess for the presence of nephrocalcinosis. (7)(38) Treatment is aimed at the management of hypercalcemia (intravenous fluids, low-calcium milk feeds, diuretics, corticosteroids, and bisphosphonates). (39)

NEWBORN PIGMENTED LESIONS (PRESENT AT BIRTH)

In this section, congenital pigmented lesions found in newborns are reviewed, including congenital dermal melanocytosis, café-au-lait macules (CALMs), and the various kinds of congenital nevi.

Congenital Dermal Melanocytosis (Appearing at Birth)

Congenital dermal melanocytosis (CDM), previously referred to as Mongolian patch, is a common, benign newborn finding that presents as gray-blue macules and/or patches (Fig 8).

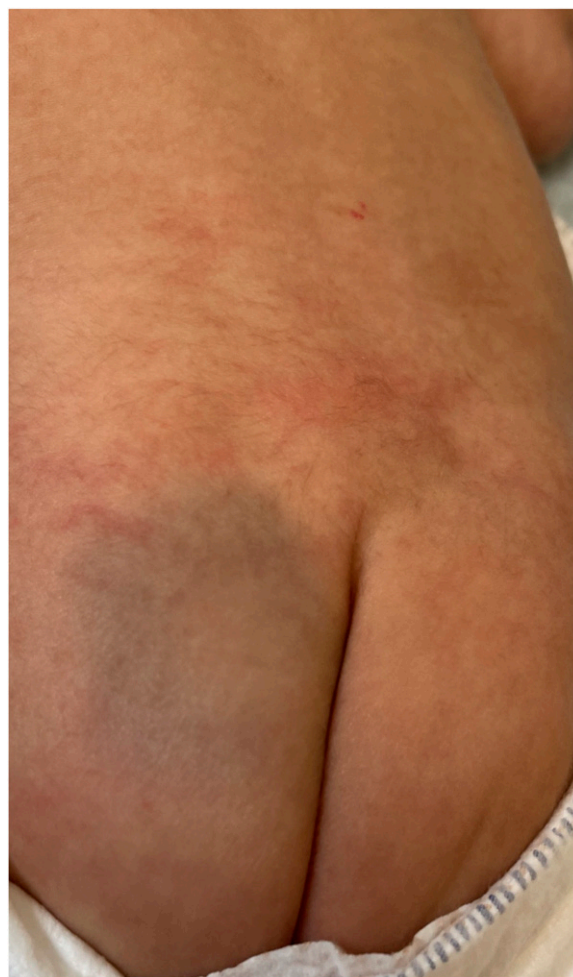

Figure 8. Congenital dermal melanocytosis on the right buttock.

CDM is found most commonly in the lumbar and sacral-gluteal region, followed by the shoulders. CDM typically presents at birth or shortly after and fades between ages 1 and 6 years. Therefore, treatment is not required. (40) There is an overall incidence of ~25%. All genders are affected equally, and although it can be seen in up to 90% of Asian, African American, and Native American individuals, it may be present in infants of any race. If there are large or multiple CDMs present with a vascular malformation, evaluation for phakomatosis pigmentovascularis should be considered. (41)(42) In a complicated case with a large or expanding CDM, evaluation for lysosomal storage disease should be considered. (43)(44) Finally, because of its bruise-like appearance, CDM has previously been mistaken for child abuse, highlighting the importance of taking appropriate histories from parents. (45)

CALMs (Appearing at Birth or through Childhood)

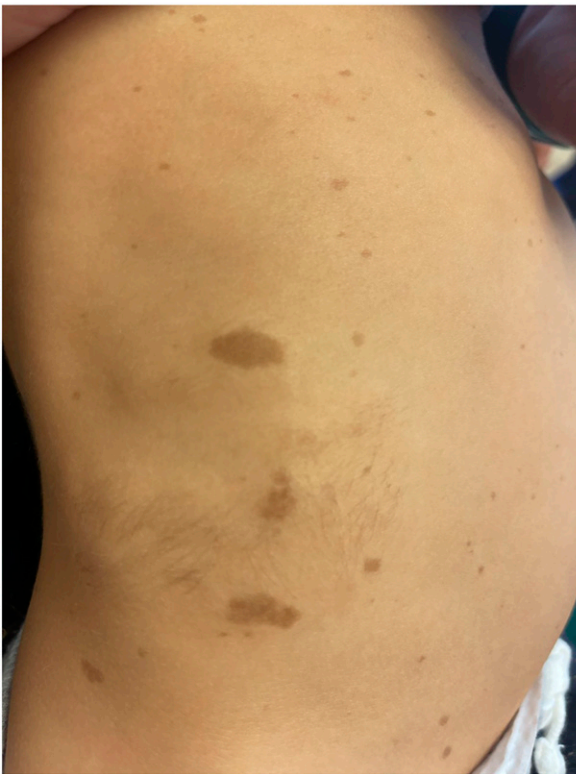CALMs are well-defined, flat, light-dark brown macules or patches that may be present at birth or develop during childhood (Fig 9A and B). Two to 3 percent of healthy newborns may have at least 1 sporadic CALM present at

birth. However, multiple or patterned CALMs may be associated with genodermatoses (a large group of inherited skin disorders that can have multisystem involvement) such as neurofibromatosis type 1 (≥ 6 CALMs), Legius syndrome, Noonan syndrome, McCune–Albright syndrome, cardiofaciocutaneous syndrome, and Costello syndrome. (46) If these genodermatoses are suspected, genetic evaluation and evaluation for other organ involvement may be required. However, typically, CALMs are benign and require no further evaluation or treatment. (47)(48)

Congenital Nevi (Appearing at Birth)

Congenital nevi are quite common in newborns, with less than 5% of newborns presenting with a congenital nevus. There are several kinds of congenital nevi, the characteristics of which are summarized in Table 2. (48)(49)(50)(51)(52)(53) Overall, these congenital nevi may be associated with underlying genodermatoses. (46) Depending on their clinical characteristics, congenital nevi may require further evaluation. For the most part, they do not require immediate treatment, but eventually, excision may be considered for cosmetic or prophylactic purposes. (48)(49)

A



B

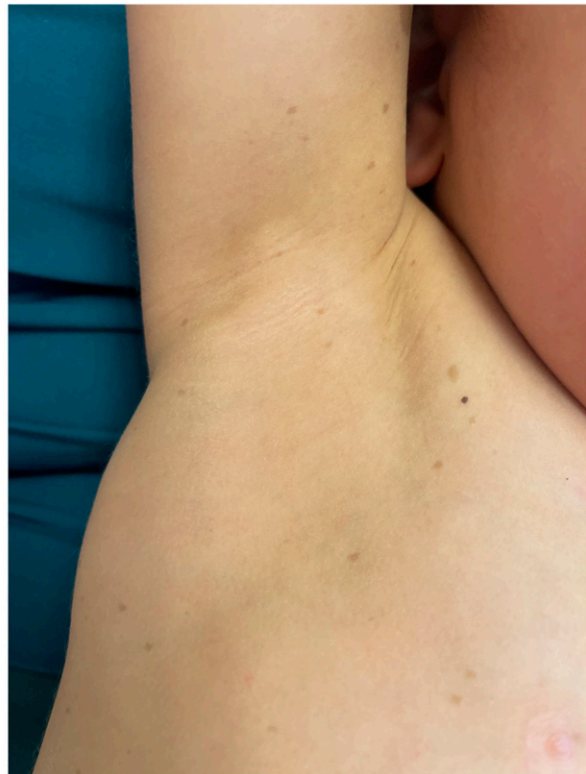

Figure 9. A. Multiple CALMs on the right flank with hypertrichotic patch. B. Right axilla demonstrating axillary freckling, concerning for an associated genodermatosis. CALM=café-au-lait macule.

Table 2. Summary of Clinical Characteristics of Different Types of Congenital Nevi

NEVUS	INCIDENCE	PATHOGENESIS	PRESENTATION	TREATMENT	COMPLICATIONS/ ASSOCIATIONS
CMN (Fig 10A)	1%	Aberrant proliferation and migration of melanocytes during embryogenesis	Red or brown, flat or minimally raised nevi that may develop rugosity, nodularity, color heterogeneity, and overlying hair	Excision for cosmetic reasons may be performed	Large/giant CMN: neurocutaneous melanosis Overall: melanoma (<5% risk)
ND/HMs	4.7%	Decreased production of melanin and/or impaired transfer of melanin to keratinocytes	Hypopigmented macules sometimes with associated white hair. ND does not blanch when pressed	None	Multiple “confetti-like” or “ash-leaf”-shaped HMs: tuberous sclerosis complex
Nevus anemicus (Fig 10B and C)	1%–5%	Increased sensitivity to catecholamines in local vasculature, leading to vasoconstriction	Congenital vascular anomaly that presents as a well-defined, irregularly shaped, white patch. Blanches when pressed. More common on trunk and chest than on extremities, head, and neck	None	Recently suggested association with <i>NF1</i>
Epidermal nevus	0.1%–0.3%	Overgrowth of epidermal components due to acquired somatic mutation after fertilization in utero	Pink, skin-colored, or light to dark brown; flat or minimally raised at birth, following lines of Blaschko, most commonly on trunk and extremities	Excision may be considered for cosmetic reasons but is not necessary	Rarely develop benign and/or malignant neoplasms. Associated with linear epidermal nevus syndrome
Nevus sebaceous	0.3%	Overgrowth of mesenchymal components, including sebaceous and apocrine glands (lack normal hair follicles)	Pink, skin-colored, or light to dark brown; flat or minimally raised at birth; ovoid or linear with overlying alopecia; following lines of Blaschko; most commonly on face and scalp. Become yellow and “wartlike” or “bubbly” during puberty	Excision may be considered for cosmetic or prophylactic reasons but is not necessary and may be deferred until adolescence if concerned for transformation into basal cell carcinoma in <0.8%	10%–20% develop benign and/or malignant neoplasms. Can be associated with linear nevus sebaceous syndrome
Nevus comedonicus	1 in 45,000	Unknown	Grouped dilated follicular openings with keratin follicular plugs that resemble open comedones (ie, “blackheads”)	Excision not usually considered. Treatment options include topical and systemic retinoids, topical steroids, salicylic acid, or ammonium lactate	Associated with <i>NEK9</i> and <i>FGFR2</i> mutations. Germline <i>FGFR2</i> mutation is associated with Apert syndrome and Nevus comedonicus. Associated with hidradenitis suppurativa

CMN=congenital melanocytic nevus, HM=hypomelanotic macule, ND=nevus depigmentosus.

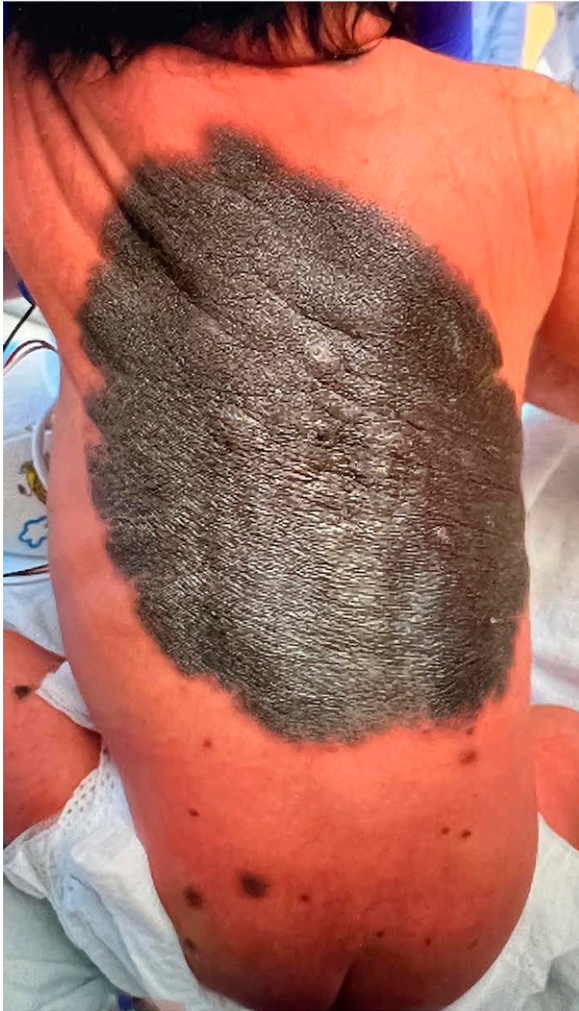A

Figure 10A. Giant congenital nevus with satellite lesions.

VASCULAR ANOMALIES (PRESENT AT BIRTH)

Vascular anomalies represent a vast category of abnormal vascular overgrowth in the form of tumors or malformations. In this section, the vascular anomalies that are benign and most commonly found in newborns are discussed, including port-wine stain, nevus simplex, and infantile hemangioma (IH).

Nevus Simplex (Appearing at Birth)

Nevus simplex, colloquially referred to as “salmon patch,” “angel’s kiss,” or “stork bite,” is a common finding present in 40% to 60% of newborns affecting all genders and races equally. It presents at birth as a pale pink to bright red, partially or completely blanchable patch with indistinct borders most commonly involving the forehead, glabella, upper eyelids, and nape (Fig 11). The lesion becomes more prominent with

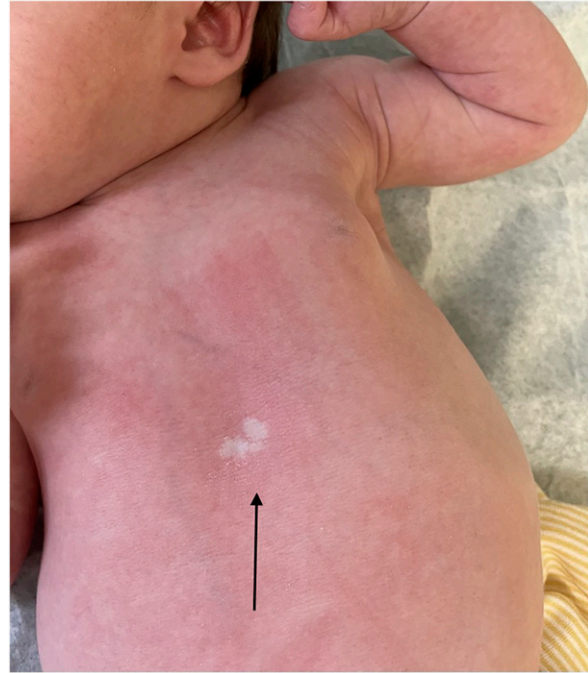B

Figure 10B. Nevus anemicus on the mid-chest.

crying, vigorous activity, and ambient temperature changes and blanches with compression. Most often, a nevus simplex fades spontaneously within 1 to 2 years after birth; however, lesions on the nape and glabella are more likely to persist into adulthood. Unusually prominent or persistent nevus simplex has been associated with underlying conditions including Beckwith-Wiedemann syndrome, macrocephaly-capillary malformation, odontodysplasia, and Roberts–SC phocomelia syndrome. A benign nevus simplex requires no further evaluation or treatment. (54)(55)

Port-Wine Birthmark, or Nevus Flammeus (Appearing at Birth)

Port-wine birthmark (PWB), also known as nevus flammeus and previously known as port-wine stain, is a capillary malformation that arises from abnormal morphogenesis leading to dilation of dermal capillaries and postcapillary venules, resulting in ectasia of the superficial vascular plexus. PWB presents in 0.3% to 0.5% of newborn infants as a well-defined, erythematous patch, most commonly in the face and scalp, that increases in size with age and does not typically involute spontaneously (Fig 12). PWB are typically segmental in distribution and do not cross the midline. Over time, PWB may become hypertrophic and violaceous, and PWB near the eyelid may result in early-onset glaucoma. (56) Hence, early treatment is indicated

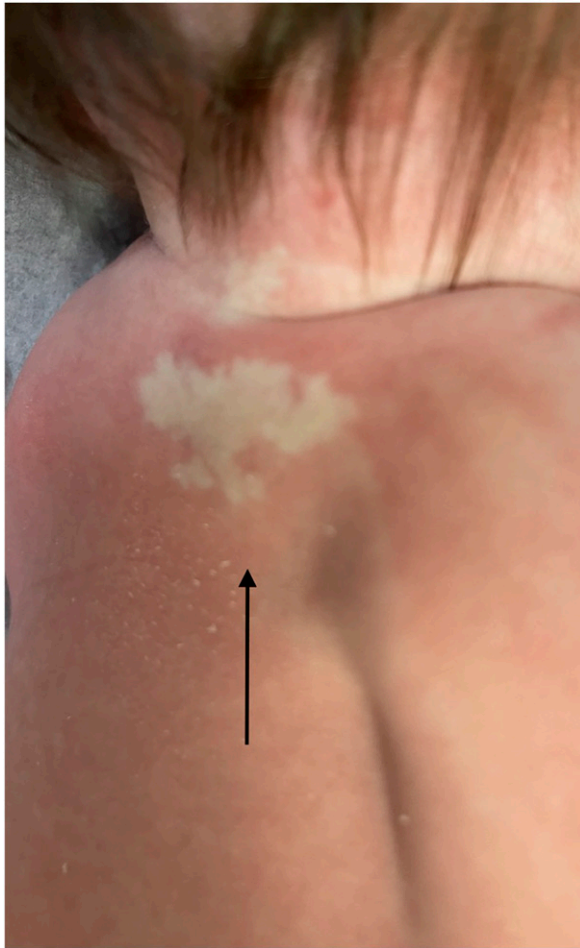C

Figure 10C. Nevus anemicus on the right upper back.

for lesions close to the eyelid. The treatment of choice is laser therapy with pulsed dye laser. Less commonly, in recalcitrant cases, the alexandrite or Nd:YAG laser can be considered. Novel treatment options such as angiogenesis inhibitors are being explored. (57) Certain clinical features may point to more serious underlying disease. Historically, distribution of a PWB over the V₁ dermatome (ophthalmic division of the trigeminal nerve) was thought to be an indicator of Sturge-Weber syndrome. (56)(58) Researchers have recently shown that PWB segmental distribution is attributed to embryologic vasculature, not the trigeminal nerve distribution, and that any lesion on the forehead is more predictive of underlying Sturge-Weber syndrome, warranting further evaluation with ophthalmologic examination and brain magnetic resonance imaging. (59) Size of the PWB has also been associated with severity of neurologic involvement, which

may be used as a predictive tool to classify neurologic severity. Klippel-Trenaunay-Weber syndrome is also characterized by PWB along with varicose veins, soft tissue, and bony hypertrophy usually in 1 lower limb and abnormal lymphatic drainage among other findings. (60)

IH (Appearing at Birth, Developing through Infancy)

IHs, formerly referred to as “strawberry hemangiomas,” occur in ~1% to ~3% of newborns. They are the most common benign tumors found in infancy. Initially unapparent, or present as a precursor lesion (a pale patch of skin, Fig 13A), hemangiomas rapidly proliferate and become prominently vascular, erythematous, raised nodular growths as the newborn grows (Fig 13 B and C). The most rapid proliferation occurs in the first 8 weeks after birth, with proliferation peaking by age 1 year. This is followed by spontaneous progressive involution, with most hemangiomas resolving by age 4 to 6 years. (61) After resolution of the hemangioma, there may be atrophy, telangiectasias, hypopigmentation, or scars, underscoring the need for early treatment, which speeds up resolution. Smaller IHs should be monitored for changes. Treatment options for thin lesions include pulsed dye laser and topical β -blockers, with systemic β -blockers reserved for lesions that are larger, may limit function, may ulcerate, or may have a poor cosmetic outcome. The location and clinical characteristics of hemangiomas guide evaluation and management. Hemangiomas that obstruct vital structures such as the eye, airway, or other vital organs require urgent evaluation, including imaging, and may on rare occasions require surgical excision. Multiple or large hemangiomas may result in high-output heart failure. Lumbosacral hemangiomas, if deep, have been associated with tethered cord syndrome or other neurologic defects. Finally, the presence of 5 or more hemangiomas on the skin should prompt evaluation of hemangiomas in the liver via ultrasonography. (55)(62)(63)

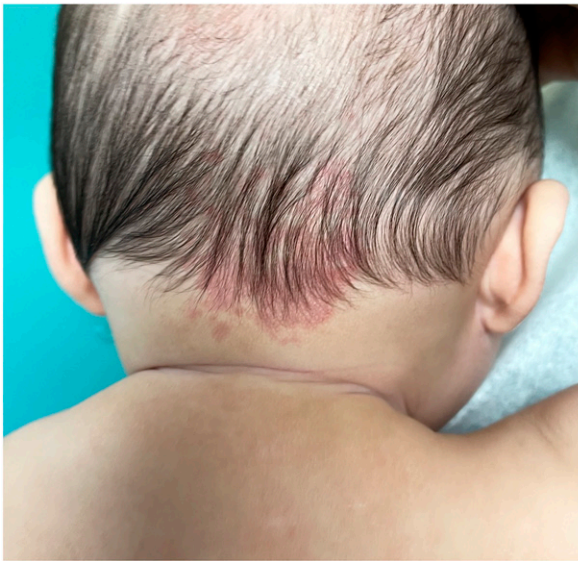DEVELOPMENTAL SKIN ABNORMALITIES (BEFORE BIRTH)

This section describes minor anomalies that are present in newborns, are usually benign, and may not require further evaluation.

Aplasia Cutis Congenita (Present at Birth)

Aplasia cutis congenita (ACC) is a rare congenital malformation that can occur either in isolation or as part of a syndrome. Less than 1/10,000 newborns present with ACC. ACC appears as an absence of the skin and, rarely, underlying deeper structures, such as bone, that occurs mostly on the scalp but can present anywhere on the skin. (64) Typically,

A



B

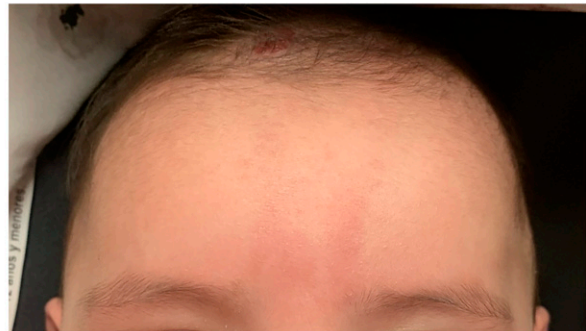

Figure 11. A. Nevus simplex on the posterior lower scalp/nape. B. Nevus simplex on the glabella.

ACC is less than 10 cm in diameter and has a variety of features, including a circular, oval, linear, or stellate membranous or nonmembranous surface. Lesions larger than 10 cm are typically associated with underlying bony defects, which is important in considering complications that may result in death. Presence of ACC may be associated with complications including infection, hemorrhage, thrombosis, and seizures. In

addition, the membranous variant of ACC is associated with trisomy 18. (65) Regarding treatment, options include observation for small lesions with no complications or surgical intervention with plastic surgery for larger lesions. (64)

Preauricular Sinuses, Pits, Tags, and Cysts (Present at Birth)

A preauricular sinus is an isolated congenital defect associated with the squamous epithelium that lines the sinus in front of the ear. This defect can lead to the production of epithelial-lined subcutaneous cysts, preauricular pits

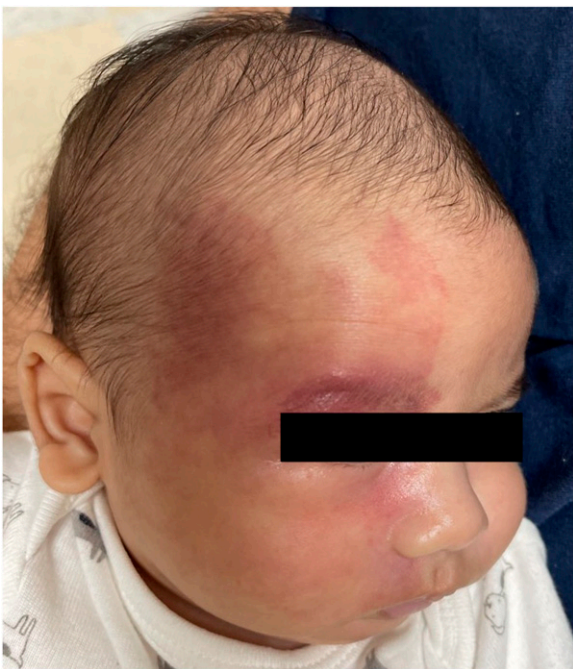

Figure 12. Port-wine stain (nevus flammeus) on the right half of face with concern for possible Sturge-Weber syndrome.

A

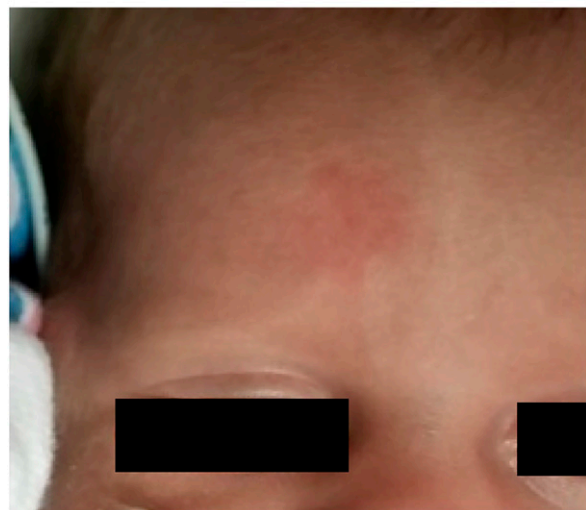

Figure 13A. Progression of infantile hemangioma; one week.

B

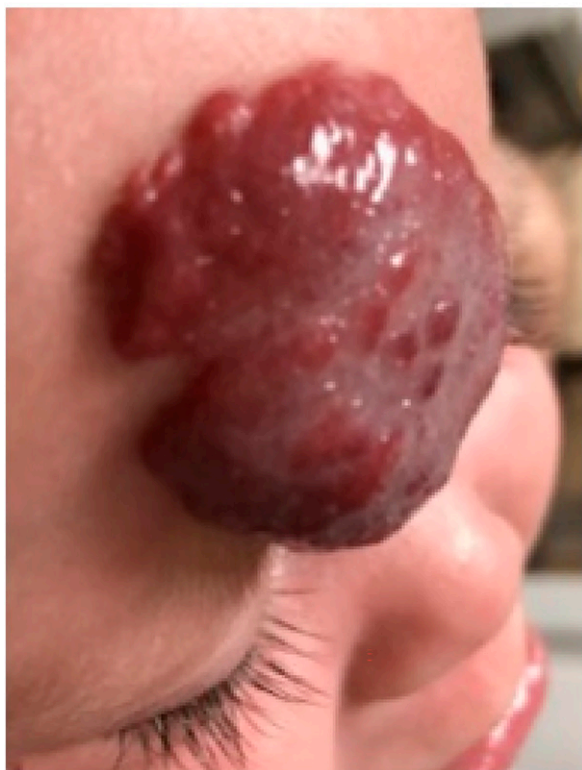

Figure 13B. Progression of infantile hemangioma; fully formed at 1 month.

due to improper fusion of the tubercles of the first 2 branchial arches, accessory skin tags that may require surgical removal, and ulcerations and infections. A preauricular

C

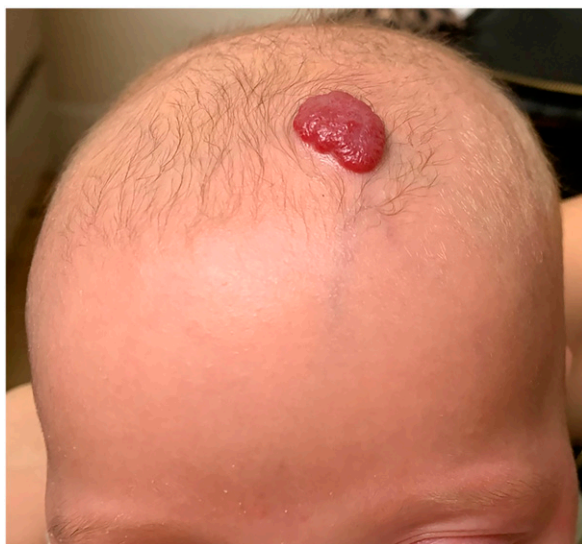

Figure 13C. Progression of infantile hemangioma; infantile hemangioma on the left upper anterior scalp.

lesion raises concern for hearing impairment or genitourinary defects in newborns. Treatment for preauricular pits, tags, and cysts includes surgical removal; in cases of recurrent infections, removal of the entire preauricular sinus tract is performed. The overall incidence rate is 0.1% to 0.9% in the United States, 0.9% in England, 1.6% to 2.5% in Taiwan, and 4% to 10% in some areas of Africa. (66) The prevalence of preauricular sinuses is higher in Black and Asian populations.

Supernumerary Digits (Present at Birth)

Supernumerary digits or polydactyly is an autosomal dominant defect of the upper or lower extremity allowing additional digits. (67) Location of the additional digits is characterized as preaxial when on the radial or great toe side and postaxial when on the ulnar or fifth toe side. The presence of digits in between the middle digits is classified as central or mesoaxial polydactyly. (67) In the United States, polydactyly is more common in Black than in white populations, with an incidence rate of 13.5 per 1,000 in Black boys versus 2.3 per 1,000 in white boys. (68) Girls have a lower incidence than boys, yet Black girls continue to have a higher incidence rate of 11.1 per 1,000 versus 0.6 per 1,000 in white girls. (68) Polydactyly occurs owing to failure of digit development and *SHH* signaling during 4 to 8 weeks of gestational age. (67) The best treatment to maximize functional outcomes is surgical intervention in the neonatal period if no bony structures exist or between the ages of 7 and 12 months if there are bony structures present in the hypoplastic digit. (67)

Supernumerary Nipples (Present at Birth)

Supernumerary nipples are additional extraneous nipples that arise because of extramammary glands developing along the mammary ridges, giving rise to nipple development during embryogenesis. Supernumerary nipples may be unilateral or bilateral and may include a nipple, areola, or both. They are often similar in color to but are smaller than the primary nipple and are often mistaken for congenital nevi. More than 5% of children have supernumerary nipples, which are often benign findings that do not require further evaluation or treatment. (55) Although previous studies have suggested an association between supernumerary nipples and renal/urinary tract malformations, recent studies suggest insufficient evidence of an association. (69)

Umbilical Granulomas (Appearing in the Newborn Period)

An umbilical granuloma (UG) is a residual fleshy nodule of granulation tissue, which appears after the separation

of the umbilical cord during the first 7 to 14 days after birth; in some cases, this can be up to 2 months. (70)(71) UGs occur in 1 of 500 births. (72) Moreover, in a comparison of techniques of umbilical cord clamping, conventional clamping (clamping the umbilical cord ~2–3 cm from the umbilicus) was found to have an 8% higher incidence of UG formation versus proximal clamping (clamping the umbilical cord at the base of the umbilicus, thereby leaving no umbilical cord remnant). (73) Complications from UG include excessive discharge, moisture, or inflammation due to primary infection; moreover, this local infection can progress to omphalitis, a secondary infection, which is a true medical emergency. (70) Treatment of UG includes cauterization with silver nitrate, desiccation with isopropyl alcohol application, topical steroids, and the simplest cost-effective method, table salt application. (70)(74)

Sacral Dimpling (Present at Birth)

Sacral dimpling is a congenital solitary indentation occurring within the gluteal cleft because of improper fusion of the neural tube during embryological development (Fig 14). Sacral dimpling is benign and arises in 1.8% to 7.2% of newborn infants. (75) A sacral dimple is permanent and does not require treatment. However, dimpling above the gluteal cleft, such as in the lumbosacral region, is of concern because it can be associated with spina bifida occulta (ie, occult spinal dysraphism), tethered spinal cord, or a dermal sinus tract. (7) Dimples larger than 5 mm and farther than 2.5 cm from the anus are considered atypical. (76) Abnormal sacral dimpling can also be accompanied by higher-

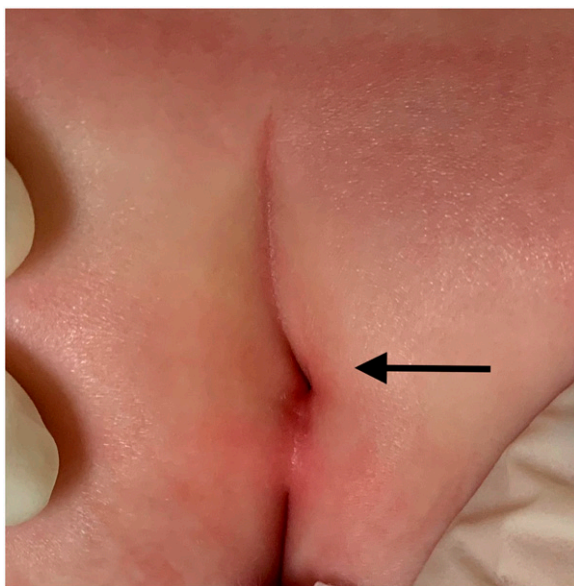


Figure 14. Sacral dimpling (seen superior to the gluteal cleft).

risk findings such as a hemangioma, collection of hair, lipoma, or skin tag. (77) For infants younger than 2 to 4 months with sacral dimpling of concern, one may obtain ultrasonography to rule out underlying pathology. If an infant is older than 4 months with a high index of suspicion for underlying pathology, ultrasonography or magnetic resonance imaging can be used for further evaluation. (75) If underlying defects are diagnosed, a neurosurgical referral is indicated, and additional treatment may be needed.

CONCLUSION

This review highlights common neonatal rashes, lesions, and anomalies that represent benign findings in newborns. Newborns may have several typical benign findings, most of which are asymptomatic and self-limited. Often, treatment is not required or is aimed at supportive care such as barrier protection and symptom reduction. The overarching theme is to be able to recognize normal benign findings in a newborn, distinguishing them from findings that are concerning for underlying processes. Most diagnoses are made clinically, and at times, additional evaluation can help confirm clinical diagnoses. Persistent or resistant findings may warrant further evaluation. Recognizing the benign nature of most newborn skin findings can minimize unnecessary laboratory evaluation or treatment that exposes the infant to unnecessary medications and can avoid causing psychosocial distress to the parents who rely on their healthcare providers for management and care.

Summary

- Harlequin color change, a transient unilateral erythema in newborn, is self-limited. (10) (Based on consensus)
- Acropustulosis of infancy tends to self-resolve by age 2 to 3 years. (18)(19) (Based on consensus)
- Eosinophilic pustular folliculitis of infancy can recur for months to years after the initial presentation. (14) (Based on consensus)
- Diaper dermatitis is associated with irritant contact dermatitis and *Candida*, *Staphylococcus*, and *Streptococcus* species infection. (23)(24)(25) (Based on consensus)
- Atopic dermatitis is associated with asthma, and peripheral eosinophilia or immunoglobulin E reactivity may be seen. (26) (Based on consensus)
- Neonatal acne typically occurs at age ~3 weeks and resolves within 1 to 3 months. It is thought to

be caused by colonization of the skin by *Malassezia* species followed by an inflammatory reaction. (28)(29) Infantile acne occurs at ~3 to 6 months and resolves by age 3 years and is thought to be triggered by endogenous androgens. (28)(29) (Based on consensus)

- Miliaria crystallina presents as superficial vesicles 1 to 2 mm in diameter on noninflamed skin. It occurs when the sweat gland duct is blocked by keratinous debris just beneath the stratum corneum. (6) (Based on consensus)
- Sebaceous gland hyperplasia in infants is often self-limited, resolves in 4 to 6 months, and treatment is not required. (31) (Based on consensus)
- Approximately 50% of newborns will experience milia, which self-resolves in 1 month to several months. If a newborn exhibits large numbers of lesions distributed over a wide area or persisting beyond several months of age, this may be suggestive of oral-facial-digital syndrome or hereditary trichodysplasia (as in Marie Unna hypotrichosis). (33)(34) (Based on consensus)
- Epstein pearls are common benign oral mucosal lesions, usually in the palate, that are found in ~60% to ~85% of newborns and resolve spontaneously. (34)(36) (Based on consensus)
- Bohn nodules are keratin-filled cysts that present on the gingival border and self-resolve. (34)(37) (Based on consensus)
- Although subcutaneous fat necrosis tends to self-resolve in 1 to 2 months, it can have a rare systemic complication of calcium deposition and hypercalcemia, thrombocytopenia, hyperlipidemia, and hyperglycemia. Therefore, management of

subcutaneous necrosis of the newborn includes monitoring serum ionized calcium levels, serum creatinine, triglycerides, platelets, and glycemia and performing an abdominal ultrasonography to assess for nephrocalcinosis. (7)(38)(39) (Based on consensus)

- Nevus simplex can be seen in 40% to 60% of newborns and can fade spontaneously within 1 to 2 years after birth; however, lesions on the nape and glabella are more likely to persist into adulthood. (54)(55) (Based on consensus)
- Infantile hemangiomas rapidly proliferate in the first 8 weeks after birth and continue until age ~18 months, after which spontaneous involution occurs slowly over time. Fifty percent of hemangiomas resolve by the age of 5 years, and 90% resolve by age 10 years. (55)(62)(63) (Based on consensus)
- Sacral dimpling is often benign, although permanent. (75) However, dimpling in the lumbosacral region can be associated with occult spinal dysraphism, tethered spinal cord, or a dermal sinus tract. (7) Dimples larger than 5 mm and farther than 2.5 cm from the anus are considered atypical. (76) Infants younger than 2 to 4 months with sacral dimpling of concern may be assessed by ultrasonography, and infants older than 4 months should be assessed by ultrasonography or magnetic resonance imaging. (75) (Based on expert consensus)



References and teaching slides for this article can be found at <https://doi.org/10.1542/pir.2022-005726>.



This longer quiz will be worth 1.5 AMA PRA Category 1 Credit™, to reflect the length of time expected to learn. Because there are only 2 quizzes in this issue, claiming ABP MOC Part 2 points will not be possible until November 2023 instead of October 2023. Before a 2023 MOC Part 2 claim can be processed, 30 total PIR quizzes must be completed.

1. A term newborn girl undergoes her initial physical examination in the nursery at 24 hours after birth. The girl is feeding well and has a normal physical examination. This is the first infant for the parents, who inquire about the skin care of the newborn. In discussing ways to care for the skin of their newborn, the clinician explains to the parents that compared with the skin of adults, newborn skin is characterized by which of the following features?
 - A. Higher concentrations of melanin and lipid.
 - B. Higher permeability to absorption of topical agents.
 - C. Lower susceptibility to infections or temperature changes.
 - D. Lower water content and pH.
 - E. Thicker epidermis.
2. A 5-day-old boy is brought to the clinic by his mother for his initial visit. The infant was born at term to a 25-year-old G1P0 mother with no perinatal complications. The infant was discharged from the hospital at 36 hours after birth. The infant is breastfeeding well every 2 hours and has seedy bowel movements almost after every feed. The mother expresses no concerns except for a “rash” that she noticed 2 days previously. The infant lives with both parents. They have no pets. No one in the family has a similar rash. On physical examination, the infant is afebrile with stable vital signs. He is well hydrated. Examination of the skin is notable for diffuse blanching erythematous macules and papules, with few pustules on an erythematous base that have a “flea-bitten appearance”. Some of the pustules are clustered. The lesions spare the acral surfaces. The remainder of the physical examination is unremarkable. A Wright stain and/or Tzanck smear of one of those pustules is most likely to reveal predominance of which of the following findings?
 - A. Basophils.
 - B. Eosinophils.
 - C. Lymphocytes.
 - D. Multinucleated giant cells.
 - E. Neutrophils.
3. For the patient in the vignette in question 2, which of the following is the most appropriate treatment of this patient?
 - A. No treatment indicated.
 - B. Topical moisturizing lotion.
 - C. Topical antifungal cream.
 - D. Oral amoxicillin.
 - E. Oral acyclovir.

REQUIREMENTS: Learners can take *Pediatrics in Review* quizzes and claim credit online only at: <http://pedsinreview.org>.

To successfully complete 2023 *Pediatrics in Review* articles for AMA PRA Category 1 Credit™, learners must demonstrate a minimum performance level of 60% or higher on this assessment. If you score less than 60% on the assessment, you will be given additional opportunities to answer questions until an overall 60% or greater score is achieved.

This journal-based CME activity is available through Dec. 31, 2025, however, credit will be recorded in the year in which the learner completes the quiz.



2023 *Pediatrics in Review* is approved for a total of 30 Maintenance of Certification (MOC) Part 2 credits by the American Board of Pediatrics (ABP) through the AAP MOC Portfolio Program. *Pediatrics in Review* subscribers can claim up to 30 ABP MOC Part 2 points upon passing 30 quizzes (and claiming full credit for each quiz) per year. Subscribers can start claiming MOC credits as early as November 2023. To learn how to claim MOC points, go to: <https://publications.aap.org/journals/pages/moc-credit>.

4. An 8-month-old girl is brought to the clinic by her parents because of persistent diaper rash. The infant was seen in the emergency department a week ago because of fever and upper respiratory infection symptoms, diagnosed with otitis media, and started on oral amoxicillin for 10 days. The infant continues to be on amoxicillin. The parents report that she has been having loose stools needing frequent diaper changes. She was noted in the past few days to have a diaper rash, for which they have used zinc oxide with limited improvement. On physical examination, the tympanic membranes are dull and nonerythematous. Examination of the perineum reveals an erythematous rash that involves the creases accompanied by satellite skin lesions. Which of the following is the most likely cause of this infant's diaper rash?
- A. Atopic dermatitis.
 - B. *Candida albicans*.
 - C. Histiocytosis.
 - D. Irritant diaper dermatitis.
 - E. Seborrheic dermatitis.
5. The infant in question 4 is started on nystatin cream topically for 10 days and advised to continue the nystatin cream for a minimum of 7 days after finishing the antibiotic course. The family returns to the clinic 5 days later because of persistence of the diaper rash. The infant completed the oral antibiotic 3 days previously. Physical examination results are significant for an erythematous rash in the diaper area with thin-walled pustules noted on an erythematous base, some of which have a honey-colored crust. The rash extends to the perineal area with beefiness noted around the perianal area. A Gram-stain of fluid from the pustules will most likely reveal which of the following findings?
- A. Basophils.
 - B. Budding hyphae.
 - C. Eosinophils.
 - D. Gram-positive cocci in clusters.
 - E. Multinucleated giant cells.
6. A 4-month-old boy is brought to the clinic by his parents for a health maintenance well visit. His last clinic visit was at age 2 months. The parents report that he has been irritable lately and has not seemed to be gaining weight compared with the first 2 months after birth. He is the product of 40 weeks' gestation and spontaneous vaginal delivery born to a mother with diabetes. He was treated for hypothermia at birth. His past medical history is significant for subcutaneous fat necrosis lesions over the buttocks, diagnosed at age 3 weeks. The lesions since then do not seem to be as tender but feel a bit hard to touch. The infant is on no medications. Immunizations are up-to-date. Today, his height and weight are at the 10th percentile, down from 25th percentile 2 months ago. The care of this patient involves monitoring for which of the following electrolyte abnormalities?
- A. Hypercalcemia.
 - B. Hyperkalemia.
 - C. Hypocalcemia.
 - D. Hypoglycemia.
 - E. Hypokalemia.

7. A newborn girl was noted on physical examination to have a port-wine birthmark over the right side of the face. On physical examination, there is a nonblanching, well-demarcated, erythematous, macular lesion over the lower two-thirds of the right cheek, not involving the forehead or the eye. Which of the following is the most appropriate treatment for this infant?
- A. Oral β -blocker.
 - B. Oral prednisone.
 - C. Pulsed dye laser.
 - D. Topical β -blocker.
 - E. Topical corticosteroids.
8. A 4-week-old girl is brought to the clinic by her parents because of multiple reddish lesions that were noted to appear 7 to 10 days previously. The lesions became larger in size and darker in color in the past few days, which prompted the clinic visit. There is no family history of similar lesions. The infant is otherwise doing well with normal growth and development. Skin examination reveals a total of 6 erythematous, vascular, raised lesions ranging from 1.5 to 2.5 cm in diameter located over the upper and lower extremities and the back. The lesions are consistent with infantile hemangiomas. The remainder of the physical examination is unremarkable. In addition to topical β -blockers, which of the following is the most appropriate step in management?
- A. Echocardiogram.
 - B. Magnetic resonance imaging of the brain.
 - C. No further testing is needed.
 - D. Ultrasonography of the liver.
 - E. Upper endoscopy.