

What's new for us in strabismus?

Pradeep Sharma, Nripen Gaur, Swati Phuljhele, Rohit Saxena

Strabismus is one of the most challenging subspecialties encountered in the field of ophthalmology. The concept of etiology of strabismus is being advanced with the development of newer imaging modalities and increased understanding of the genetics of strabismus. Imaging is also being used to aid in the planning of strabismus surgery. Newer horizons are being explored in the amblyopia management. The good old eye-pad is being replaced with the iPad. Early detection of loss of stereopsis is being used to decide the timing for strabismus surgery. Improvement of binocular summation has been discovered as a benefit of corrective strabismus surgery. Newer surgical techniques such as new transposition procedures are being developed to correct complex strabismus. Strabismus surgeries aided by adjustable sutures have increased the precision of a strabismologist. A new light has been thrown on the psychosocial impact of strabismus. A present-day strabismologist has advanced from the goal of ocular alignment to a bigger perspective "to regain the paradise lost: stereopsis."

Key words: Amblyopia, nystagmus, stereopsis, strabismus, strabismus surgery, transposition

Strabismus is one of the commonly encountered disease entities in the ophthalmology outpatient department. The prevalence of this disease ranges from 0.5% to 5%.^[1] Strabismus is not just a cosmetic blemish but has also a myriad of effects of its own such as disruption of binocular vision and stereopsis apart from causing a negative impact on the patient's self-esteem and interpersonal relationships. With advances in the knowledge base, the goal of present-day strabismologist is not just restoring the ocular alignment but also restoring the ultimate goal "stereopsis." This review highlights the recent advances in the field of strabismus as well as newer treatment modalities.

Etiology

Our understanding regarding the etiopathogenesis of strabismus is continually being revised. Various theories have been proposed in the past to explain this intriguing disease ranging from muscular theories supported by Scobee^[2] to the classic reflexogenic theories. Chavasse had proposed that an abnormal visual input may impede binocular fusion development leading to strabismus. Recent advances in imaging techniques and advances in the field of genetics have remarkably changed the recent-day understanding. The advent of high-resolution magnetic resonance imaging (MRI) has led to the discovery of extraocular muscle pulleys which are the condensation of the connective tissue of the posterior Tenon's fascia. These help in maintaining the paths of the extraocular muscles. Puley heterotropia or abnormalities can lead to the development of strabismus. Instability of the rectus pulleys

has been shown to be associated with incomitant strabismus.^[3] Based on MRI, Yokoyama procedure^[4] for correcting highly myopic strabismus has been devised. An inferior displacement of the lateral rectus pulley has been implicated in heavy eye syndrome^[4] as well as sagging eye syndrome.^[5] A recent study has shown that rectus pulley displacements can create the clinical picture of superior oblique palsy.^[6] Congenital cranial dysinnervation disorders (CCDDs) are secondary to some neurologic pathology of congenital origin. These have a wide spectrum of phenotypic presentation. This wide spectrum results due to either primary or secondary dysinnervation. The concept of CCDD was proposed in 2002.^[7] Recent studies have supported this concept and the focus is now on identifying the genes that cause CCDDs. In a study done at our center to study high-resolution MRI of intracranial parts of sixth nerve and the extraocular muscles in orbit in patients of CCDD, we found the absence or hypoplasia of sixth nerve in Duane retraction syndrome (DRS), anomalous course, sixth nerve absence/hypoplasia in eyes of Mobius syndrome along with the absence of seventh nerve in patients of Mobius syndrome [Fig. 1]. A significant hypoplasia of lateral rectus was also found in these patients.

Genetic basis of strabismus is also being explored. A recent study by Altick *et al.*^[8] has shown through microarray analysis that the gene expression in the extraocular muscles of the strabismic and the nonstrabismic individuals. They found that 25% of the muscle-specific genes were downregulated in the extraocular muscles of strabismic patients. Another study from Japan has been done to localize

Access this article online

Website:

www.ijo.in

DOI:

10.4103/ijo.IJO_867_16

Quick Response Code:



Pediatric Ophthalmology and Strabismus Services, Dr. Rajendra Prasad Centre for Ophthalmic Sciences, All India Institute of Medical Sciences, New Delhi, India

Correspondence to: Prof. Pradeep Sharma, Pediatric Ophthalmology and Strabismus Services, Dr. Rajendra Prasad Centre for Ophthalmic Sciences, All India Institute of Medical Sciences, New Delhi - 110 029, India. E-mail: drpsharma57@yahoo.com

Manuscript received: 08.11.16; Revision accepted: 06.03.17

This is an open access article distributed under the terms of the Creative Commons Attribution-NonCommercial-ShareAlike 3.0 License, which allows others to remix, tweak, and build upon the work non-commercially, as long as the author is credited and the new creations are licensed under the identical terms.

For reprints contact: reprints@medknow.com

Cite this article as: Sharma P, Gaur N, Phuljhele S, Saxena R. What's new for us in strabismus?. Indian J Ophthalmol 2017;65:184-90.

the chromosomal susceptibility loci for comitant strabismus.^[9] They found multiple susceptibility loci for comitant strabismus. Chromosome 8q^[10] has been shown to be associated with DRS. Chan *et al.*^[11] found CHN1 mutations in two families with this disease. Several other CCDDs have similarly been identified with genetic anomalies.

Amblyopia Management

Amblyopia is one of the treatable causes of vision loss in children. Early diagnosis of this condition through visual screening can lead to better treatment outcomes. The conventional treatment method involves the occlusion of the better eye. However, the method of occlusion has its very own imperfections. The conventional form of patching has been associated with low compliance, and it averages below 50% according to a recent study.^[12] It is also associated with social stigma and may lead to stress and anxiety. Recent researches focus on newer treatment modalities to address the issue of low compliance. New liquid crystal display (LCD) occlusion glasses have been developed for amblyopia treatment. These function by alternating one lens from opaque to transparent at an interval of 30 s, thereby simulating intermittent occlusion. These glasses can achieve occlusion without being a cosmetic blemish. A study comparing LCD glasses with conventional patching has found the glasses to be an effective alternative.^[13] However, they do suffer from the same disadvantage of the spectacle mounted occlusions which can be easily “peeked off” by the children.

Dichoptic training has been shown to actuate a higher level of plasticity than the use of occlusion alone.^[14] Birch *et al.*^[15] compared the dichoptic iPad gameplay with sham iPad gameplay in amblyopia treatment and found that the group given amblyopia treatment in the form of dichoptic iPad games had significant visual gain 3 months posttreatment. Binocular iPad treatment has been to be effective in another as well.^[16] A shift from Eye-pads to I-pads!

Enhancement of cortical plasticity is one of the most important issues to be addressed in amblyopia treatment. Fluoxetine has been shown to reactivate cortical plasticity in amblyopic rats.^[17] Levodopa has been shown to be efficacious

in amblyopia along with occlusion by us^[18] and several others and now documented through functional MRI studies.^[19] Besides this, citicoline^[20] has also been shown to be of benefit when used along with occlusion therapy.

Imaging in Strabismus

Imaging techniques have not only changed the current understanding of strabismus etiology but also aided in the planning of the surgery. Anterior chamber optical coherence tomography has been shown to be effective in detecting muscle insertions in previously operated as well as new strabismus cases.^[21,22] Ultrasonic biomicroscopy has been used for the same purpose.^[23] These investigative modalities provide a noninvasive modality to estimate the muscle insertions and are better over previously used conventional modalities such as computed tomography (CT) scan as there is no radiation exposure. Furthermore, they also prove to be more cost-effective as compared to CT and MRI.

Dynamic MRI^[24] is a yet another imaging modality that can help in surgical planning as it can pick up functional muscle contractility. High-resolution MRI of the orbit can successfully predict to extraocular muscle pulley location and the muscle paths which can aid us in planning the surgery. With the help of this, we described a new condition synergistic innervational downshoot [Fig. 2a-c].^[25] Functional MRI and diffusion tensor imaging have been used for the evaluation of brain cluster activation in strabismic amblyopes,^[26] and it has shown that the improvement in visual acuity postocclusion therapy correlates with the hemodynamic activity.

Stereopsis and Binocular Summation

The ultimate goal for any strabismologist is to achieve a good stereopsis as was highlighted in the Knapp lecture at AAPOS

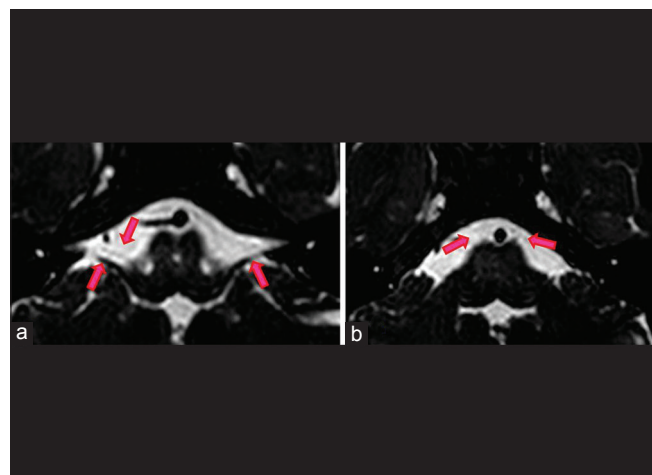


Figure 1: High-resolution magnetic resonance imaging images showing (a) absence of left seventh nerve (b) bilateral sixth nerve hypoplasia in Mobius syndrome

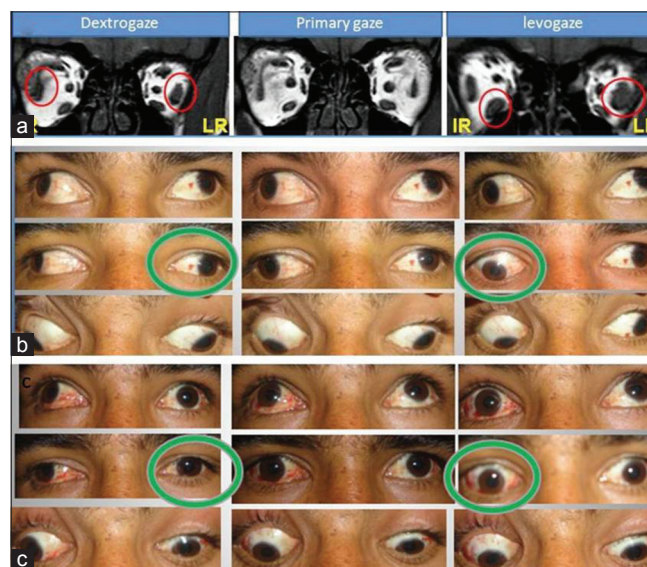


Figure 2: A new condition “synergistic innervational downshoot” diagnosed with the help of dynamic magnetic resonance imaging (a) magnetic resonance imaging orbit showing contraction of both right eye and left eye lateral rectus (increase in cross-section of muscle) on dextrogaze and contraction of right eye inferior rectus and left eye lateral rectus on levogaze, (b) preoperative nine gaze clinical photograph, (c) postoperative nine gaze clinical photograph

2016, Vancouver, by Dr. Sharma. The patients of strabismus have a deficit of depth perception, and the binocular summation is also adversely affected. Timely correction of strabismus can lead to better outcomes in terms of stereopsis. The critical period for surgery is 4–6 weeks for congenital cataract, 4–6 weeks for infantile esotropia, and 4–6 weeks for intermittent exotropia. Early assessment of vision has been possible with Teller Acuity Cards [Fig. 3].^[27] A horizontal Lang two-pencil test has been shown to an effective screening test for stereopsis and binocularity [Fig. 4].^[28] The merit of this test is the advantage of it being a bedside test and it requires least patient cooperation. Nongpiur *et al.*^[29] have evaluated stereoacuity in patients with acquired esotropia. They have found a horizontal deviation up to eight prisms diopter to be compatible with stereopsis.

Early detection of abnormal stereoacuity and near fusional vergence amplitudes can help decide the proper timing of surgery in intermittent exotropia.^[30] The stereoacuity testing can be used as a predictor of the outcomes of the surgery in case of intermittent exotropia. A study done at our center showed that the distance stereoacuity is reduced to a bigger extent than the near stereoacuity.^[31] A stereoacuity more than 20 s of arc was recommended to be an indication of surgery, whereas a stereoacuity worse than 70 s of arc was associated with poor prognosis [Fig. 5]. The binocular summation is defined as the superiority of binocular visual functions over the monocular ones. Improvement of binocular summation is one of the newly discovered functional benefits of the corrective strabismus surgery.^[32]

Pharmacologic Injection Treatment

Botulinum Type A toxin and bupivacaine injections in extraocular muscles have found their place in the correction of strabismus. Botulinum toxin has been used for treating infantile esotropia and partially accommodative esotropia and also as a temporary measure in paralytic strabismus to prevent secondary muscle contracture. Lueder *et al.*^[33] have evaluated long-term results of botulinum-augmented medial rectus recessions for large-angle infantile esotropia showing successful outcome in 74% cases. Bupivacaine, an amide local anesthetic, has been proved to correct strabismus by increasing the strength of the muscle.^[34] According to a recently published study^[35] reporting the efficacy of injection treatment

in horizontal comitant strabismus in adult patients with bupivacaine and botulinum A toxin, the injection treatments result in a stable clinically significant correction and can be a low-cost alternative to the conventional surgery. Although the success rates are inferior as compared to the conventional surgery, the pharmacologic injection treatment appears promising.

Nystagmus

The most common types of nystagmus seen in children are infantile nystagmus syndrome, fusional maldevelopment syndrome, and spasmus nutans.^[36] Outcomes in cases of nystagmus has also improved significantly with the augmented Andersons procedure^[37] in shifting the eccentric null to the primary position and also evaluating the auditory biofeedback.^[38] Perceptual learning has been shown to improve visual acuity in children with infantile nystagmus.^[39] A study evaluating four-muscle tenotomy surgery for nystagmus has shown improvement in the visual acuity and decrease in the intensity of nystagmus.^[40] A study by Singh *et al.* has evaluated the retroequatorial recession of horizontal rectus evaluation and Hertle-Dell'Osso procedure in patients with infantile nystagmus. The authors have demonstrated the improvement in contrast sensitivity and reduction of electronystagmography (ENG) amplitudes in the patients.^[41] Resolution of periodic alternating nystagmus with amantadine has been reported.^[42] A nystagmus-specific quality of life questionnaire has also been developed recently.^[43]

Minimally Invasive Strabismus Surgery

Minimal invasive approach for strabismus surgery is being explored to decrease tissue trauma and patient discomfort. The conventional limbal-based approach is fraught with increased tissue traumatization and visible postoperative scarring. Fornix-based approach introduces by Parks markedly decreased the postoperative discomfort, and the scar itself was well hidden under the lids. However, this technique does not reduce the area of tissue disruption as compared to the limbal-based approach. Gobin developed a novel procedure to access the rectus muscle using two small openings. The principles of his surgery have become the cornerstone for the



Figure 3: Visual assessment using Teller Acuity Cards



Figure 4: Horizontal Lang's two pencil test "a simple yet sensitive tool for the assessment of stereopsis"

minimally invasive strabismus surgery. This surgical technique has been used for various types of strabismus surgeries which include rectus muscle recessions and plications, rectus muscle transpositions, inferior oblique recessions, and rectus muscle posterior fixations.^[44] The disadvantage of this technique is a steeper learning curve and the risk of a conjunctival tear in patients having inelastic conjunctiva. Mini-plication^[45] has been described as a new rectus tightening procedure for treatment of small-angle strabismus. It can be done under topical anesthesia and is useful in adult patients with diplopia. Mini-tenotomy is a similar procedure which can be used as a weakening procedure for similar indications under topical anesthesia.^[46] It is also important to ensure a proper learning of the strabismus procedures by the residents and fellows. The International Council of Ophthalmology's Ophthalmology Surgical Competency Assessment Rubric for Strabismus Surgery^[47] guidelines in this regards serve the purpose of this and have been validated.^[48]

Adjustable Sutures

Adjustable sutures are being used to correct the overcorrections and undercorrections in the immediate postoperative period. These sutures come handy to the strabismologist as they give the surgeon an additional chance to increase the overall surgical success rate. Studies have shown better outcomes with adjustable suture surgery than the nonadjustable suture surgery in patients with exotropia.^[49] Another study has shown the adjustable suture surgery to be beneficial in children undergoing reoperation for childhood strabismus.^[50] Single-stage adjustable strabismus surgery is a good alternative for patients with restrictive strabismus.^[51] A study done at our center to evaluate the stability of ocular alignment after single-stage adjustable strabismus surgery performed under topical anesthesia showed better outcomes compared to conventional surgery.^[52] The adjustable procedure has now been incorporated even in the partial vertical rectus transpositioning to improve the outcomes in exotropic DRS and abducens palsy. Cases with near-distance disparity are being tackled more effectively by the resection recession procedures on the same rectus muscle. This was found to be effectively correcting a persistent cyclic esotropia.^[53]




Figure 5: Frisby-Davis distance stereoacuity test “an established indicator for the timing of strabismus surgery in intermittent divergent squint”

Transposition Surgeries

Surgical management of incomitant strabismus can be a challenge even to the seasoned strabismologists. Transposition procedures involving the normally functioning muscles are a conventional treatment option in such cases. These surgeries can be used in a myriad of disease spectra such as sixth and third nerve palsies, DRS, and monocular elevation deficit. Transposition surgeries commonly used in recent times are vertical recti transpositions (VRT), Knapp's procedure, and modified Nishida procedure. To avoid anterior segment ischemia, partial VRT is being preferred rather than using the full muscle tendon. VRT is used for the management of sixth nerve palsy [Fig. 6a-c] as well as DRS. VRT surgery with posterior fixation sutures has been shown to be effective in the management of complete sixth nerve palsy and patients of esotropic DRS.^[54] Partial VRT has been shown to improve abduction and binocular single visual field in cases of exotropic Duane syndrome.^[55] Modified Nishida procedure^[56] involves direct suturing of the recti muscles to the sclera without any tenotomy or splitting of muscle. It has proven to be very useful in the treatment of sixth nerve palsy and also missing medial rectus muscles [Fig. 7a-c]. Medial transposition of split lateral rectus has also been tried with success in cases of third nerve palsy.^[57,58] Superior rectus transposition has been proven to increase abduction in esotropic DRS^[59] with or without medial rectus recessions.

Periosteal Fixation Procedures

However, in cases where anterior segment ischemia is a concern or in cases where the muscles to be transposed are abnormal, the transposition procedures fail to deliver and cannot be used. Periosteal fixation procedures can serve as an important remedy in such cases.^[60] Periosteal fixation procedures involve either fixing the antagonist muscle to the periosteum or by tethering the globe to the periosteum on the side of missing or paralyzed muscle. Precaruncular periosteal approach for medial wall periosteal anchoring of the globe has been found to be a viable option in the management of complete external oculomotor nerve palsy.^[61] Lateral rectus periosteal fixation has been found to be effective to correct exodeviation in cases of exotropic DRS.

Psychosocial Aspect of Strabismus

Physical appearance is an important aspect of the socialization process. Menon *et al.*^[62] have documented the psychosocial difficulties in individuals with strabismus. Another study has detected subnormal health-related quality of life in the parents of children with strabismus.^[63] Strabismus surgery can bring about psychosocial benefits to the affected person.^[64,65] Nelson *et al.*^[66] have found strabismus surgery to have a significant effect on self-esteem and confidence of patients. Another study has found that the strabismus surgery improves health-related quality of life in both affected children as well as their parents.^[67]

Conclusions

With ongoing research and improvement in the surgical techniques, we are closer to achieve the ultimate goal of stereopsis for all and that too early in the childhood. The overall outcomes of surgery have improved with the

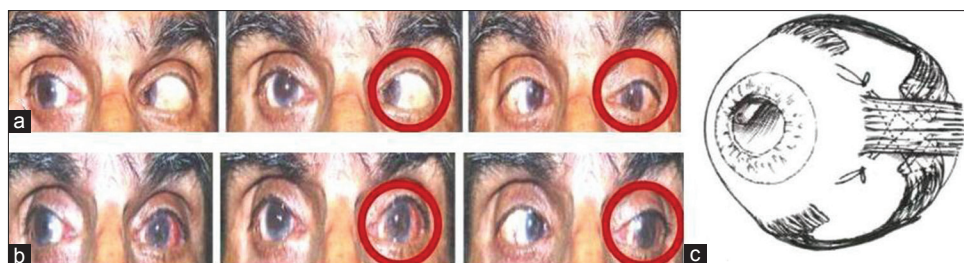


Figure 6: Adjustable partial vertical recti transposition in a patient of left lateral rectus palsy (a) preoperative clinical photograph, (b) postoperative clinical photograph, (c) schematic diagram showing the surgical technique

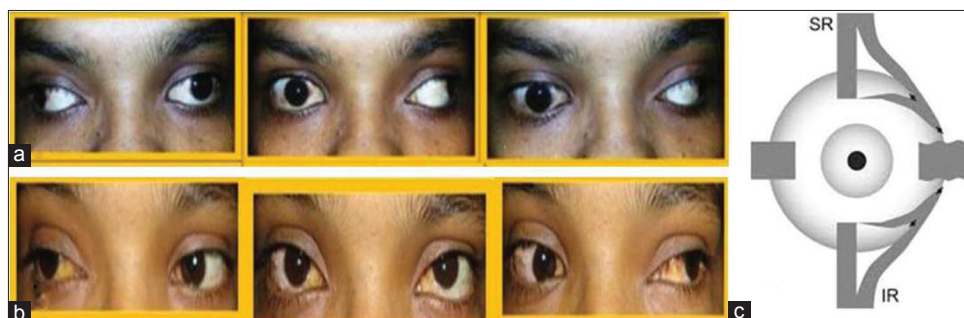

Figure 7: Modified Nishida technique in management of absence of medial rectus (a) preoperative clinical photograph, (b) postoperative clinical photograph, (c) schematic diagram showing the surgical technique

advent of newer surgical techniques, especially being made adjustable. As our understanding of this disease evolves, with newer techniques of imaging, the outcomes of the management are bound to improve. Moreover, the goal is not just 20/20 or 6/3 vision with good near vision J1 in each eye but also good stereopsis and good fusion. We are not just correcting strabismus but also restoring binocular vision and stereopsis!

Financial support and sponsorship

Nil.

Conflicts of interest

There are no conflicts of interest.

References

- Hashemi H, Yekta A, Jafarzadehpour E, Ostadimoghaddam H, Eshtrati B, Mohazzab-Torabi S, *et al.* The prevalence of strabismus in 7-year-old schoolchildren in Iran. *Strabismus* 2015;23:1-7.
- Scobee RG. Anatomic factors in the etiology of heterotropia. *Am J Ophthalmol* 1948;31:781-95.
- Oh SY, Clark RA, Velez F, Rosenbaum AL, Demer JL. Incomitant strabismus associated with instability of rectus pulleys. *Invest Ophthalmol Vis Sci* 2002;43:2169-78.
- Yamaguchi M, Yokoyama T, Shiraki K. Surgical procedure for correcting globe dislocation in highly myopic strabismus. *Am J Ophthalmol* 2010;149:341-6.e2.
- Chaudhuri Z, Demer JL. Sagging eye syndrome: Connective tissue involution as a cause of horizontal and vertical strabismus in older patients. *JAMA Ophthalmol* 2013;131:619-25.
- Suh SY, Le A, Clark RA, Demer JL. Rectus pulley displacements without abnormal oblique contractility explain strabismus in superior oblique palsy. *Ophthalmology* 2016;123:1222-31.
- Gutowski NJ, Bosley TM, Engle EC. 110th ENMC International Workshop: The congenital cranial dysinnervation disorders (CCDDs). Naarden, The Netherlands, 25-27 October, 2002. *Neuromuscul Disord* 2003;13:573-8.
- Altick AL, Feng CY, Schlauch K, Johnson LA, von Bartheld CS. Differences in gene expression between strabismic and normal human extraocular muscles. *Invest Ophthalmol Vis Sci* 2012;53:5168-77.
- Shaaban S, Matsuo T, Fujiwara H, Itoshima E, Furuse T, Hasebe S, *et al.* Chromosomes 4q28.3 and 7q31.2 as new susceptibility loci for comitant strabismus. *Invest Ophthalmol Vis Sci* 2009;50:654-61.
- Amouroux C, Vincent M, Blanchet P, Puechberty J, Schneider A, Chaze AM, *et al.* Duplication 8q12: Confirmation of a novel recognizable phenotype with Duane retraction syndrome and developmental delay. *Eur J Hum Genet* 2012;20:580-3.
- Chan WM, Miyake N, Zhu-Tam L, Andrews C, Engle EC. Two novel CHN1 mutations in 2 families with Duane retraction syndrome. *Arch Ophthalmol* 2011;129:649-52.
- Wallace MP, Stewart CE, Moseley MJ, Stephens DA, Fielder AR; Monitored Occlusion Treatment Amblyopia Study (MOTAS) Cooperatives; Randomized Occlusion Treatment Amblyopia Study (ROTAS) Cooperatives. Compliance with occlusion therapy for childhood amblyopia. *Invest Ophthalmol Vis Sci* 2013;54:6158-66.
- Wang J, Neely DE, Galli J, Schliesser J, Graves A, Damarjian TG, *et al.* A pilot randomized clinical trial of intermittent occlusion therapy liquid crystal glasses versus traditional patching for treatment of moderate unilateral amblyopia. *J AAPOS* 2016;20:326-31.
- Li J, Thompson B, Deng D, Chan LY, Yu M, Hess RF. Dichoptic training enables the adult amblyopic brain to learn. *Curr Biol* 2013;23:R308-9.
- Birch EE, Li SL, Jost RM, Morale SE, De La Cruz A, Stager D Jr, *et al.* Binocular iPad treatment for amblyopia in preschool children. *J AAPOS* 2015;19:6-11.
- Li SL, Jost RM, Morale SE, Stager DR, Dao L, Stager D, *et al.* A binocular iPad treatment for amblyopic children. *Eye (Lond)* 2014;28:1246-53.
- Maya Vetencourt JF, Sale A, Viegli A, Baroncelli L, De Pasquale R,

- O'Leary OF, *et al.* The antidepressant fluoxetine restores plasticity in the adult visual cortex. *Science* 2008;320:385-8.
18. Bhartiya P, Sharma P, Biswas NR, Tandon R, Khokhar SK. Levodopa-carbidopa with occlusion in older children with amblyopia. *J AAPOS* 2002;6:368-72.
 19. Yang CI, Yang ML, Huang JC, Wan YL, Jui-Fang Tsai R, Wai YY, *et al.* Functional MRI of amblyopia before and after levodopa. *Neurosci Lett* 2003;339:49-52.
 20. Pawar PV, Mumbare SS, Patil MS, Ramakrishnan S. Effectiveness of the addition of citicoline to patching in the treatment of amblyopia around visual maturity: A randomized controlled trial. *Indian J Ophthalmol* 2014;62:124-9.
 21. Ngo CS, Smith D, Kraft SP. The accuracy of anterior segment optical coherence tomography (AS-OCT) in localizing extraocular rectus muscles insertions. *J AAPOS* 2015;19:233-6.
 22. Takkar B, Sharma P, Singh AK, Sahay P. Anterior segment optical coherence tomography for identifying muscle status in strabismus surgery. *Int J Ophthalmol* 2016;9:933-4.
 23. Dai S, Kraft SP, Smith DR, Buncic JR. Ultrasound biomicroscopy in strabismus reoperations. *J AAPOS* 2006;10:202-5.
 24. Teodorescu L, Ionescu V. Dynamic nuclear magnetic resonance in strabismus. *Oftalmologia* 2010;54:123-8.
 25. Sharma P, Chaurasia S, Rasal A, Angmo D. Synergistic innervational downshoot: A distinct vertical dysinnervation pattern and its unique management. *Can J Ophthalmol* 2017;52:e31-e38.
 26. Gupta S, Kumaran SS, Saxena R, Gudwani S, Menon V, Sharma P. BOLD fMRI and DTI in strabismic amblyopes following occlusion therapy. *Int Ophthalmol* 2016;36:557-68.
 27. Sharma P, Bairagi D, Sachdeva MM, Kaur K, Khokhar S, Saxena R. Comparative evaluation of Teller and Cardiff acuity tests in normals and unilateral amblyopes in under-two-year-olds. *Indian J Ophthalmol* 2003;51:341-5.
 28. Nongpiur ME, Sharma P. Horizontal Lang two-pencil test as a screening test for stereopsis and binocularity. *Indian J Ophthalmol* 2010;58:287-90.
 29. Nongpiur ME, Singh A, Saxena R, Sharma A, Sharma P. To evaluate stereoacuity in patients with acquired esotropia and to determine factors associated with favourable outcomes. *Indian J Ophthalmol* 2014;62:695-8.
 30. Sharma P, Saxena R, Narvekar M, Gadia R, Menon V. Evaluation of distance and near stereoacuity and fusional vergence in intermittent exotropia. *Indian J Ophthalmol* 2008;56:121-5.
 31. Singh A, Sharma P, Singh D, Saxena R, Sharma A, Menon V. Evaluation of FD2 (Frisby Davis distance) stereotest in surgical management of intermittent exotropia. *Br J Ophthalmol* 2013;97:1318-21.
 32. Pineles SL, Demer JL, Isenberg SJ, Birch EE, Velez FG. Improvement in binocular summation after strabismus surgery. *JAMA Ophthalmol* 2015;133:326-32.
 33. Lueder GT, Galli M, Tychsen L, Yildirim C, Pegado V. Long-term results of botulinum toxin-augmented medial rectus recessions for large-angle infantile esotropia. *Am J Ophthalmol* 2012;153:560-3.
 34. Scott AB, Miller JM, Shieh KR. Bupivacaine injection of the lateral rectus muscle to treat esotropia. *J AAPOS* 2009;13:119-22.
 35. Debert I, Miller JM, Danh KK, Scott AB. Pharmacologic injection treatment of comitant strabismus. *J AAPOS* 2016;20:106-111.e2.
 36. Penix K, Swanson MW, DeCarlo DK. Nystagmus in pediatric patients: Interventions and patient-focused perspectives. *Clin Ophthalmol* 2015;9:1527-36.
 37. Gupta R, Sharma P, Menon V. A prospective clinical evaluation of augmented Anderson procedure for idiopathic infantile nystagmus. *J AAPOS* 2006;10:312-7.
 38. Sharma P, Tandon R, Kumar S, Anand S. Reduction of congenital nystagmus amplitude with auditory biofeedback. *J AAPOS* 2000;4:287-90.
 39. Huurneman B, Boonstra FN, Goossens J. Perceptual learning in children with infantile nystagmus: Effects on visual performance. *Invest Ophthalmol Vis Sci* 2016;57:4216-28.
 40. Dubner M, Nelson LB, Gunton KB, Lavrich J, Schnall B, Wasserman BN. Clinical evaluation of four-muscle tenotomy surgery for nystagmus. *J Pediatr Ophthalmol Strabismus* 2016;53:16-21.
 41. Singh A, Ashar J, Sharma P, Saxena R, Menon V. A prospective evaluation of retroequatorial recession of horizontal rectus muscles and Hertle-Dell'Osso tenotomy procedure in patients with infantile nystagmus with no definite null position. *J AAPOS* 2016;20:96-9.
 42. Lee SH, Lee SY, Choi SM, Kim BC, Kim MK, Kim JS. Resolution of periodic alternating nystagmus with amantadine. *J Neurol Sci* 2016;364:65-7.
 43. McLean RJ, Maconachie GD, Gottlob I, Maltby J. The development of a nystagmus-specific quality-of-life questionnaire. *Ophthalmology* 2016;123:2023-7.
 44. Mojon DS. Review: Minimally invasive strabismus surgery. *Eye (Lond)* 2015;29:225-33.
 45. Leenheer RS, Wright KW. Mini-plication to treat small-angle strabismus: A minimally invasive procedure. *J AAPOS* 2012;16:327-30.
 46. Wright KW. Mini-tenotomy procedure to correct diplopia associated with small-angle strabismus. *Trans Am Ophthalmol Soc* 2009;107:97-102.
 47. Golnik KC, Motley WW, Atilla H, Pilling R, Reddy A, Sharma P, *et al.* The ophthalmology surgical competency assessment rubric for strabismus surgery. *J AAPOS* 2012;16:318-21.
 48. Motley WW 3rd, Golnik KC, Anteby I, Atilla H, Gole GA, Murillo C, *et al.* Validity of ophthalmology surgical competency assessment rubric for strabismus surgery in resident training. *J AAPOS* 2016;20:184-5.
 49. Mireskandari K, Cotesta M, Schofield J, Kraft SP. Utility of adjustable sutures in primary strabismus surgery and reoperations. *Ophthalmology* 2012;119:629-33.
 50. Zhang MS, Hutchinson AK, Drack AV, Cleveland J, Lambert SR. Improved ocular alignment with adjustable sutures in adults undergoing strabismus surgery. *Ophthalmology* 2012;119:396-402.
 51. Sharma P, Reinecke RD. Single-stage adjustable strabismus surgery for restrictive strabismus. *J AAPOS* 2003;7:358-62.
 52. Sharma P, Julka A, Gadia R, Chhabra A, Dehnan M. Evaluation of single-stage adjustable strabismus surgery under conscious sedation. *Indian J Ophthalmol* 2009;57:121-5.
 53. Gaur N, Sharma P, Verma S, Takkar B, Dhar S. Surgical correction of persistent adult-onset cyclic strabismus. *J AAPOS* 2017;21:77-8.
 54. Akar S, Gokyigit B, Pekel G, Demircan A, Demirok A. Vertical muscle transposition augmented with lateral fixation (Foster) suture for Duane syndrome and sixth nerve palsy. *Eye (Lond)* 2013;27:1188-95.
 55. Sharma P, Tomer R, Menon V, Saxena R, Sharma A. Evaluation of periosteal fixation of lateral rectus and partial VRT for cases of exotropic Duane retraction syndrome. *Indian J Ophthalmol* 2014;62:204-8.
 56. Nishida Y, Hayashi O, Oda S, Kakinoki M, Miyake T, Inoki Y, *et al.* A simple muscle transposition procedure for abducens palsy without tenotomy or splitting muscles. *Jpn J Ophthalmol* 2005;49:179-80.
 57. Sukhija J, Kaur S, Singh U. Nasal lateral rectus transposition combined with medial rectus surgery for complete oculomotor nerve palsy. *J AAPOS* 2014;18:395-6.
 58. Saxena R, Sharma M, Singh D, Dhiman R, Sharma P. Medial

- transposition of split lateral rectus augmented with fixation sutures in cases of complete third nerve palsy. *Br J Ophthalmol* 2016;100:585-7.
59. Tibrewal S, Sachdeva V, Ali MH, Kekunnaya R. Comparison of augmented superior rectus transposition with medial rectus recession for surgical management of esotropic Duane retraction syndrome. *J AAPOS* 2015;19:199-205.
 60. Saxena R, Phuljhele S, Sharma P, Pinto CN. Periosteal fixation procedures in the management of incomitant strabismus. *Middle East Afr J Ophthalmol* 2015;22:320-6.
 61. Saxena R, Sinha A, Sharma P, Phuljhele S, Menon V. Precaruncular approach for medial orbital wall periosteal anchoring of the globe in oculomotor nerve palsy. *J AAPOS* 2009;13:578-82.
 62. Menon V, Saha J, Tandon R, Mehta M, Khokhar S. Study of the psychosocial aspects of strabismus. *J Pediatr Ophthalmol Strabismus* 2002;39:203-8.
 63. Yamada T, Hatt SR, Leske DA, Holmes JM. Health-related quality of life in parents of children with intermittent exotropia. *J AAPOS* 2011;15:135-9.
 64. Glasman P, Cheeseman R, Wong V, Young J, Durnian JM. Improvement in patients' quality-of-life following strabismus surgery: Evaluation of postoperative outcomes using the Adult Strabismus 20 (AS-20) score. *Eye (Lond)* 2013;27:1249-53.
 65. Sharma PI, Aslam A, Saxena R, Vashisht P. Responsiveness of Health-Related Quality-of-Life Questionnaire in Adults Undergoing Strabismus Surgery. Presented at AAO Annual Meeting 2017, Chicago.
 66. Nelson BA, Gunton KB, Lasker JN, Nelson LB, Drohan LA. The psychosocial aspects of strabismus in teenagers and adults and the impact of surgical correction. *J AAPOS* 2008;12:72-6.e1.
 67. Wang X, Gao X, Xiao M, Tang L, Wei X, Zeng J, *et al*. Effectiveness of strabismus surgery on the health-related quality of life assessment of children with intermittent exotropia and their parents: A randomized clinical trial. *J AAPOS* 2015;19:298-303.